

# The American Society of Colon and Rectal Surgeons Clinical Practice Guidelines for the Surgical Management of Crohn's Disease

Amy L. Lightner, M.D.<sup>1</sup> • Jon D. Vogel, M.D.<sup>2</sup> • Joseph C. Carmichael, M.D.<sup>3</sup>  
Deborah S. Keller, M.D., M.S.<sup>4</sup> • Samir A. Shah, M.D.<sup>5</sup> • Uma Mahadevan, M.D.<sup>6</sup>  
Sunanda V. Kane, M.D., M.S.P.H.<sup>7</sup> • Ian M. Paquette, M.D.<sup>8</sup>  
Scott R. Steele, M.D., M.B.A.<sup>1</sup> • Daniel L. Feingold, M.D.<sup>9</sup>

Prepared by the Clinical Practice Guidelines Committee of The American Society of Colon and Rectal Surgeons

- 1 Department of Surgery, Cleveland Clinic, Cleveland, Ohio
- 2 Department of Surgery, University of Colorado, Aurora, Colorado
- 3 Department of Surgery, University of California, Irvine, California
- 4 Department of Surgery, Columbia University, New York, New York
- 5 Department of Medicine, Brown University, Providence, Rhode Island
- 6 Department of Medicine, University of California, San Francisco, California
- 7 Department of Internal Medicine, Mayo Clinic, Rochester, Minnesota
- 8 Department of Surgery, University of Cincinnati, Cincinnati, Ohio
- 9 Department of Surgery, Rutgers University, New Brunswick, New Jersey

The American Society of Colon and Rectal Surgeons (ASCRS) is dedicated to ensuring high-quality patient care by advancing the science, prevention, and management of disorders and diseases of the colon, rectum, and anus. The Clinical Practice Guidelines Committee is composed of Society members who are chosen because they have demonstrated expertise in the specialty of colon and rectal surgery. This committee was created to lead international efforts in defining quality care for conditions related to the colon, rectum, and anus and develop clinical practice guidelines based on the best available evidence. While not

proscriptive, these guidelines provide information on which decisions can be made and do not dictate a specific form of treatment. These guidelines are intended for the use of all practitioners, health care workers, and patients who desire information about the management of the conditions addressed by the topics covered in these guidelines.

These guidelines should not be deemed inclusive of all proper methods of care nor exclusive of methods of care reasonably directed toward obtaining the same results. The ultimate judgment regarding the propriety of any specific procedure must be made by the physician in light of all of the circumstances presented by the individual patient.

Earn Continuing Education (CME) credit online at [cme.lww.com](http://cme.lww.com). This activity has been approved for AMA PRA Category Credit.<sup>TM</sup>

Supplemental digital content is available for this article. Direct URL citations appear in the printed text, and links to the digital files are provided in the HTML and PDF versions of this article on the journal's Web site ([www.dcrjournal.com](http://www.dcrjournal.com)).

**Funding/Support:** None reported.

**Financial Disclosures:** None reported.

**Correspondence:** Daniel L. Feingold, M.D., Professor and Chair, Section of Colorectal Surgery, Rutgers University, 125 Patterson Street, New Brunswick, NJ 08901. E-mail: [daniel.feingold@rutgers.edu](mailto:daniel.feingold@rutgers.edu).

Dis Colon Rectum 2020; 63: 1028–1052

DOI: 10.1097/DCR.0000000000001716

© The ASCRS 2020

## STATEMENT OF THE PROBLEM

Crohn's disease (CD) is an idiopathic, incurable chronic inflammatory disease of the GI tract, which affects over one million people in the United States and continues to increase in incidence for unknown reasons.<sup>1</sup> The characteristic transmural inflammation of CD can occur anywhere along the GI tract, resulting in an inflammatory, fibrostenotic, or penetrating phenotype. Although the degree of symptoms is variable and may wax and wane throughout the disease course, patients can require chronic immunosuppression and operations to *treat* the disease symptoms, but both are unable to *cure* the disease.

Monoclonal antibodies have become the cornerstone of medical therapy for moderate-to-severe disease; however, their utility is limited by primary and secondary loss

of response and the risk of serious opportunistic infection with anti-tumor necrosis factor (TNF) medication.<sup>2-9</sup> Although the rate of surgical intervention for medically refractory disease has decreased over the past 6 decades and less emergent surgery is being performed, a meta-analysis of population-based studies reported that rates of surgical intervention for medically refractory disease remain high at 16%, 33%, and 47% at 1, 3, and 5 years from diagnosis.<sup>10,11</sup> After resection, because surgery is not curative, 70% to 90% of patients will have endoscopic recurrence by 1 year and up to 35% of patients will have a repeat intestinal resection within 10 years.<sup>12-14</sup> Given the typical complexity of patients with CD requiring surgical intervention, multidisciplinary care with gastroenterologists, surgeons, radiologists, pathologists, and other ancillary team members is critical for optimizing patient care. Because the management of patients with CD involves different medical disciplines working in conjunction with one another, these guidelines must be viewed in that context and represent only a portion of the treatment necessary for the optimal care of these patients. This clinical practice guideline will focus on the surgical management of patients with CD.

## METHODOLOGY

This clinical practice guideline is based on the previous ASCRS *Clinical Practice Guideline for the Surgical Management of Crohn's Disease* that was published in 2015.<sup>15</sup> Bowel preparation, enhanced recovery pathways, prevention of thromboembolic disease, and the management of perianal disease, although relevant to the management of patients with CD, are beyond the scope of this guideline and are addressed in other ASCRS clinical practice guidelines.<sup>16-19</sup> An organized search of MEDLINE, PubMed, EMBASE, Scopus, and the Cochrane Database of Collected Reviews limited to the English language was performed from January 1, 2014 through December 1, 2019. The complete search strategy is listed in **Supplemental Digital Content**, <http://links.lww.com/DCR/B243>. Keyword combinations included “Crohn's disease”; “colitis”; “ileitis”; “fibrostenotic”; “stricture”; “abscess”; “phlegmon”; “fistula”; “megacolon”; “fulminant”; “complications”; “infliximab”; “steroids”; “TNF”; “tumor necrosis factor”; “immunomodulators”; “Crohn abscess”; “Crohn anastomosis”; “Crohn cancer”; “Crohn colitis”; “Crohn dilation”; “Crohn dysplasia”; “Crohn endoscopy”; “Crohn laparoscopy”; “Crohn laparotomy”; “Crohn operation”; “Crohn resection”; “Crohn stricture”; “Crohn strictureplasty”; and “Crohn surgery” or “laparoscopic approach\*” or “laparoscopic resection\*” or “minimally invasive approach\*” or “minimally invasive surgery\*” or “pouch\*” or “pouch failure\*” or “pouch outcome\*” or “robotic platform\*” or “robotic resection\*” or “robotics\*” or “stoma\*” or “stomas\*” or “use of diversion.\*”

In brief, a total of 15,643 unique journal titles were identified including 142 articles from a directed search of

references embedded in candidate publications including references from the 2015 guideline. The initial review of the search results titles led to the exclusion of 14,562 articles. After a review of the remaining 1081 articles, a total of 312 articles were chosen for grading of the recommendations (Fig. 1). Emphasis was placed on prospective trials, meta-analyses, systematic reviews, and practice guidelines. Peer-reviewed observational studies and retrospective studies were included when higher-quality evidence was insufficient. The final source material used was evaluated for the methodologic quality, the evidence base was examined, and a treatment guideline was formulated by the subcommittee for this guideline. The final grade of recommendation and level of evidence for each statement were determined using the Grades of Recommendation, Assessment, Development, and Evaluation system (Table 1).<sup>20,21</sup> When agreement was incomplete regarding the evidence base or treatment guideline, consensus from the committee chair, vice chair, and 2 assigned reviewers determined the outcome. Members of the ASCRS Clinical Practice Guidelines Committee worked in joint production of these guidelines from inception to final publication. Recommendations formulated by the subcommittee were reviewed by the entire Clinical Practice Guidelines Committee, selected members of the ASCRS Inflammatory Bowel Disease committee, and selected practicing gastroenterologists. The guideline was peer reviewed by *Diseases of the Colon & Rectum* and the final guideline was approved by the ASCRS Executive Council. In general, each ASCRS Clinical Practice Guideline is updated every 5 years. No funding was received for preparing this guideline and the authors have declared no competing interests related to this material. This guideline conforms to the Appraisal of Guidelines Research and Evaluation (AGREE) checklist.

## OPERATIVE INDICATIONS

### Medically Refractory Disease

1. **Patients who demonstrate an inadequate response to, develop complications from, or are nonadherent with medical therapy should typically be considered for surgery. Grade of recommendation: Strong recommendation based on low-quality evidence, 1C.**

The goals of medical treatment of CD are to achieve remission with endoscopic mucosal healing in patients with active disease and avoid relapse in those with quiescent disease. When glucocorticoids are used, clinical improvement is usually evident within days of initiating intravenous therapy and within 2 to 4 weeks of treatment with oral glucocorticoids. When immunomodulators (eg, 6-mercaptopurine, methotrexate, azathioprine) are used as a monotherapy, a plateau in improvement of clinical symptoms is often demonstrated within 12 to 16 weeks.<sup>14</sup> On the initiation of monoclonal antibody therapy with

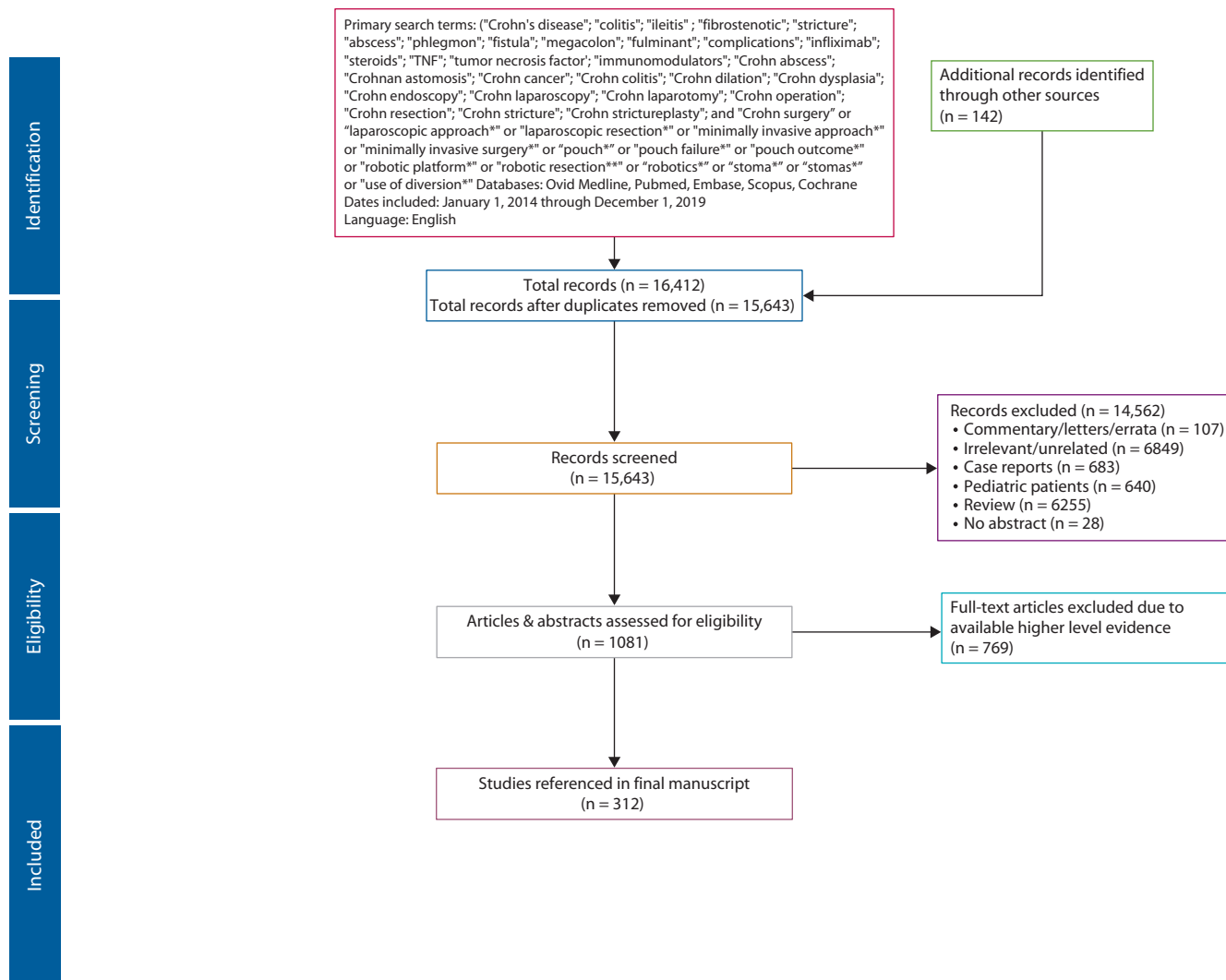


FIGURE 1. PRISMA literature search flow sheet.

an anti-TNF (eg, infliximab, adalimumab, certolizumab pegol), anti-integrin (eg, vedolizumab), or anti-interleukin (eg, ustekinumab) a 6- to 12-week course of therapy is usually recommended to assess efficacy.<sup>22</sup> An exception to these timelines is in the setting of severe, acute colitis, when infliximab is given as a loading dose in an attempt to control the acute presentation; in this situation, a more limited period of about 5 to 7 days is usually recommended to determine the initial response justifying continuation of therapy.<sup>23–25</sup>

Surgical intervention may be warranted in patients who are unable to tolerate medical therapy because of side effects, are nonadherent to medical therapy, or have medically refractory disease activity due to primary or secondary loss of response.<sup>26–29</sup> Surgery may also be considered in patients who are steroid dependent regardless of disease severity because of the deleterious effects of chronic glucocorticoid use.<sup>30</sup> A recent randomized, controlled trial also proposed laparoscopic resection as a reasonable

option rather than initiating monoclonal antibody therapy in the setting of otherwise refractory, relatively limited disease (eg, short-length <40 cm, inflammatory, nonstricturing, ileocolic disease).<sup>31</sup>

### Inflammation

1. Patients with severe acute colitis who do not adequately respond to medical therapy or who have signs or symptoms of impending or actual perforation should undergo surgery. Grade of recommendation: Strong recommendation based on low-quality evidence, 1C.

Because of the limited evidence specific to CD, the management of severe, acute colitis in patients with CD is based almost entirely on our understanding of this condition in patients with ulcerative colitis (UC).<sup>32,33</sup> A recent prospective cohort comparative analysis showed that the severe forms of UC and Crohn's colitis respond similarly to medical therapy with a response to steroids in 73% and

**TABLE 1.** The GRADE System: grading recommendations

Grade	Description	Benefit versus risk and burdens	Methodologic quality of supporting evidence	Implications
1A	Strong recommendation, High-quality evidence	Benefits clearly outweigh risk and burdens or vice versa	RCTs without important limitations or overwhelming evidence from observational studies	Strong recommendation, can apply to most patients in most circumstances without reservation
1B	Strong recommendation, Moderate-quality evidence	Benefits clearly outweigh risk and burdens or vice versa	RCTs with important limitations (inconsistent results, methodologic flaws, indirect or imprecise) or exceptionally strong evidence from observational studies	Strong recommendation, can apply to most patients in most circumstances without reservation
1C	Strong recommendation, Low- or very-low quality evidence	Benefits clearly outweigh risk and burdens or vice versa	Observational studies or case series	Strong recommendation but may change when higher-quality evidence becomes available
2A	Weak recommendation, High-quality evidence	Benefits closely balanced with risks and burdens	RCTs without important limitations or overwhelming evidence from observational studies	Weak recommendation, best action may differ depending on circumstances or patients' or societal values
2B	Weak recommendations, Moderate-quality evidence	Benefits closely balanced with risks and burdens	RCTs with important limitations (inconsistent results, methodologic flaws, indirect or imprecise) or exceptionally strong evidence from observational studies	Weak recommendation, best action may differ depending on circumstances or patients' or societal values
2C	Weak recommendation, Low- or very-low quality evidence	Uncertainty in the estimates of benefits, risks and burden; benefits, risk and burden may be closely balanced	Observational studies or case series	Very weak recommendations; other alternatives may be equally reasonable

GRADE = Grades of Recommendation, Assessment, Development, and Evaluation; RCT = randomized controlled trial.

Adapted from Guyatt G, Guterman D, Baumann MH, et al. Grading strength of recommendations and quality of evidence in clinical guidelines: report from an American College of Chest Physicians Task Force. *Chest*. 2006;129:174–181.<sup>20</sup> Used with permission.

68% of patients and to anti-TNF drugs in 89% and 86% of patients.<sup>33</sup>

“Severe acute colitis” and “fulminant colitis” are terms that apply to patients with colitis, frequent stools ( $\geq 6$ /day), and systemic inflammatory response syndrome (SIRS).<sup>32,34</sup> The degree of severity can be classified as mild, moderate, or severe using the modified Truelove and Witts criteria, with severe colitis defined as  $\geq 6$  bowel movements per day and at least one of the following: temperature  $>37.8^{\circ}\text{C}$ , pulse  $>90$  beats per minute, erythrocyte sedimentation rate  $>30$  mm/h, C-reactive protein  $>30$  mg/L, or a hemoglobin  $<10.5$  g/dL.<sup>34</sup> “Megacolon” is often defined as transverse colon diameter  $\geq 5.5$  cm and, in the setting of SIRS, is termed “toxic megacolon.”<sup>35,36</sup> When severe Crohn’s colitis is suspected, alternative causes of colitis (eg, *Clostridium difficile*, cytomegalovirus) should typically be excluded with stool studies and endoscopic mucosal biopsy via careful flexible sigmoidoscopy, and therapeutic drug monitoring may be helpful to guide monoclonal antibody therapy.<sup>37–40</sup> Laboratory testing including serum C-reactive protein, hemoglobin, creatinine, and albumin levels, fecal calprotectin and monoclonal antibody drug levels

for therapeutic drug monitoring can help measure the response to therapeutic interventions.<sup>40,41</sup> Given the potentially masking effects of high-dose steroids, patients are usually followed with plain abdominal x-rays to determine the presence of megacolon or bowel perforation, and these may need to be repeated often, if not daily, until patients’ overall clinical condition improves.

Initial treatment of severe colitis includes supportive care, intravenous fluid resuscitation, avoidance of antidiarrheal medication, limited use of opiates and anticholinergics, and prompt initiation of intravenous glucocorticoids (eg, methylprednisolone 60 mg/day). Venous thromboembolism prophylaxis beginning on hospital admission is recommended because active colitis is a risk factor for this potentially life-threatening condition, whereas bowel rest and prophylactic antibiotics are usually not necessary.<sup>40,42,43</sup>

In general, a response to steroid therapy includes improvement or resolution of the SIRS, a decrease in stool frequency (eg,  $<6$ /day), and overall clinical improvement. When patients do not respond adequately within about 72 hours, using a second-line therapy such as an

anti-TNF drug or cyclosporine should typically be considered.<sup>24,25,44,45</sup> A response to anti-TNF or cyclosporine in this setting should occur typically within about 5 to 7 days.<sup>46–48</sup> For medical treatment failures or colitis-related emergencies (eg, colon perforation), subtotal colectomy with end ileostomy is generally recommended.<sup>49</sup>

### Stricture

**1. Endoscopic dilation may be considered for patients with short-segment, noninflammatory, symptomatic small-bowel or anastomotic strictures. Grade of recommendation: Strong recommendation based on low-quality evidence, 1C.**

Strictures complicating CD can arise anywhere along the intestinal tract and are often classified as either inflammatory or fibrostenotic in nature. The degree of inflammation surrounding the bowel wall can be suggestive of an inflammatory stricture, and chronic upstream bowel dilation is more typical of a fibrostenotic stricture. However, these categories are not mutually exclusive because intestinal fibrosis is a dynamic process and inflammation and fibrosis can coexist within the same stricture or region.<sup>50,51</sup> Ultrasound, computed tomography enterography (CTE) and magnetic resonance enterography (MRE) can diagnose small-bowel strictures with a high level of accuracy, and recent guidelines report algorithms for trying to distinguish between fibrotic and inflammatory strictures.<sup>52–54</sup> Magnetic resonance imaging avoids the radiation exposure from CT imaging that may be a particularly relevant consideration in younger patients who potentially face an increased lifetime cumulative radiation exposure.<sup>55</sup> In addition, MRE may be better than CTE in distinguishing inflammatory, fibrotic, and mixed inflammatory/fibrotic strictures.<sup>53</sup> However, obtaining an MRE after a CTE has been performed is not usually recommended because of the lack of additional diagnostic yield under these circumstances.<sup>56</sup>

Medical therapy with steroids, immunomodulators, or anti-TNF drugs remains the first-line treatment for strictures with an inflammatory component, whereas endoscopic or surgical therapy is usually indicated for fibrostenotic strictures.<sup>51,57</sup> The typical indication for endoscopic therapy is a limited, short-segment (<5 cm) stricture in the absence of associated penetrating disease (eg, abscess, fistula). Primary and anastomotic strictures may be successfully dilated with endoscopic techniques.<sup>58,59</sup> The most commonly used dilation approach is a “through-the-scope” method using variable diameter dilating balloons, although a standardized methodology of sequential dilations has not been established.<sup>60</sup>

The technical success of endoscopic stricture dilation is about 90%, and complications (eg, perforation, hemorrhage) occur in 2% to 4% of cases.<sup>53,58,59,61,62</sup> After successful dilation of a nonanastomotic site (eg, primary stricture), repeat endoscopic dilation is required in 41% to

73% of patients followed for up to 5 years, and recurrence rates are higher at anastomotic sites in comparison to nonanastomotic sites.<sup>54,59,60,63</sup> Dilation of strictures <5 cm in length in the setting of CD has been associated with the best long-term outcome.<sup>58,59</sup> Steroid injection of the stricture during dilation is typically not helpful.<sup>59,63,64</sup> Within 2 to 5 years after endoscopic dilation of primary or anastomotic strictures, surgical intervention is required in about one-third of patients.<sup>53,58,59,63</sup>

**2. Surgery is indicated for patients with symptomatic small-bowel or anastomotic strictures that are not amenable to medical therapy and/or endoscopic dilation. Grade of recommendation: Strong recommendation based on low-quality evidence, 1C.**

Resection or strictureplasty is warranted for small-bowel and anastomotic strictures when medical and/or endoscopic treatments are unsuccessful or when a stricture is believed to be fixed and fibrotic in nature and not amenable to medical therapy.<sup>65</sup> When resection is performed, the extent of resection should typically include only about 2 cm of grossly uninflamed bowel proximal and distal to the diseased segment, because there is no benefit to obtaining microscopically negative margins or removing extended lengths of normal bowel.<sup>66–68</sup> Although limited mesenteric excision remains the most common practice under these circumstances, the role of a more extensive mesenteric resection is being investigated and is reviewed later.<sup>69</sup> Sutured or stapled techniques, both suitable for bowel anastomosis in this setting, and the use of a defunctioning ileostomy are discussed elsewhere in this guideline.<sup>70–72</sup>

Strictureplasty, an alternative to resection, is used in general to preserve bowel length and is often the preferred option for patients with multiple strictures separated by relatively longer segments of grossly normal small bowel, in particular, in patients who are at risk for short-bowel syndrome. Strictureplasty may also be particularly suitable for selected duodenal strictures where resection carries higher risk, but should typically be avoided in the setting of perforation, inflammatory mass, malignancy, dysplasia, or severe malnutrition.<sup>73–75</sup> In 38% to 71% of cases, strictureplasty is combined with bowel resection to address multifocal disease while maximizing bowel preservation.<sup>76,77</sup>

The type of strictureplasty performed is largely based on the length of the stricture and the pliability of the affected bowel. In general, Heineke-Mikulicz strictureplasty is used for strictures <10 cm, Finney strictureplasty can address strictures 10 to 25 cm in length, and isoperistaltic side-to-side strictureplasty is indicated for strictures longer than about 25 cm.<sup>75,78–80</sup> Complications of strictureplasty have been reported in 4% to 18% of patients in large series and include surgical site infection, obstruction, stricture-site hemorrhage, sepsis, perforation, and, in 6% of patients, early reoperation.<sup>76,78,81–83</sup> Low preoperative

albumin, weight loss, advanced age, preoperative steroid use, and abscess or fistula at the time of strictureplasty are risk factors for intra-abdominal septic complications.<sup>82,84</sup>

Patients undergoing strictureplasty are at a risk for recurrence, which, in general, is comparable to patients undergoing resection.<sup>85</sup> Studies report a 5-year recurrence rate after strictureplasty in jejunoileal and ileocolic locations of 25% to 30% that includes a roughly 3% site-specific recurrence rate; the remaining majority of recurrences develop in intestinal segments remote from original strictureplasty sites.<sup>81,82</sup> After strictureplasty, reoperation for recurrent disease has been reported in 29%, 34%, and 73% of patients after 5, 7.5, and 10 years.<sup>76,82</sup>

**3. Patients with strictures of the colon that cannot be adequately surveyed endoscopically should be considered for resection. Grade of recommendation: Strong recommendation based on low-quality evidence, 1C.**

Colonic strictures occur in 9% to 13% of patients with CD and are most commonly found at a single site, although multiple strictures may be present.<sup>86–88</sup> Endoscopic dilation can be used in colonic strictures to alleviate symptoms with success rates similar to those seen after dilating small-bowel strictures.<sup>62</sup> It is important to appreciate that 2% to 6% of colonic CD strictures contain occult dysplasia or cancer, but it is often difficult to differentiate malignant from benign strictures by using clinical criteria alone. Factors more commonly associated with cancer include shorter segment strictures, advanced patient age, longer duration of disease, and absence of active colitis.<sup>87–89</sup> Colorectal strictures should be assessed with multiple endoscopic biopsies and cytological brushings, if needed, to evaluate for malignancy.<sup>90</sup> If a stricture cannot be adequately surveyed to exclude a concomitant carcinoma, resection following standard oncologic principles should typically be performed. Although colonic strictureplasty has been reported, this is generally discouraged due to a lack of proven benefit as well as concerns about potential carcinoma being left in situ.<sup>91</sup>

### Penetrating Disease

**1. Patients with a free perforation should undergo surgical resection of the perforated segment. Grade of recommendation: Strong recommendation based on moderate-quality evidence, 1B.**

Free perforation of the bowel in patients with CD is uncommon with a reported incidence of 1.5% to 16% with nearly all cases involving a solitary perforation of the small bowel.<sup>92–97</sup> Resection of the perforated segment is preferred over simple suture closure because of the relatively high failure rate and increased risk of morbidity associated with primary repair.<sup>93,98</sup>

**2. Patients with penetrating Crohn's disease with abscess formation may be managed with antibiotics with or**

**without drainage followed by interval elective resection or medical therapy depending on the clinical situation and patient preferences. Grade of recommendation: Weak recommendation based on moderate-quality evidence, 2B.**

Intra-abdominal abscesses in patients with CD typically result from a penetrating disease phenotype with an associated distal stricture and can have an associated inflammatory process that affects other segments of bowel walling off the abscess. Although smaller abscesses (<3 cm) can generally be treated with antibiotics alone, larger abscesses are typically treated with antibiotics and percutaneous drainage (PD) that has a low rate of enterocutaneous fistula formation.<sup>99–105</sup> Comparative studies and meta-analyses comparing PD and initial surgery for spontaneous abdominal abscess in patients with CD indicate that successful PD, defined as abscess resolution and avoidance of subsequent surgery, occurs in 23% to 78% of patients; abscess recurrence is significantly higher after PD alone versus surgical intervention (OR, 2.16; 95% CI, 1.03–4.54;  $p = 0.04$ ).<sup>106–111</sup> Factors associated with PD failure include concomitant steroid use, colonic disease, and abscesses that are large, multiloculated, or multifocal.<sup>107,112,113</sup>

Percutaneous drainage used as a bridge to bowel resection compared with bowel resection without prior PD results in decreased overall complications, need for diverting stoma, and overall cost, and no difference in rates of postoperative enterocutaneous fistula and anastomotic leak.<sup>107,109,114</sup> Preoperative PD combined with antibiotics typically improves postoperative outcomes and shortens the overall length of stay.<sup>115–117</sup> In a meta-analysis of 513 patients who have CD with spontaneous abscess, the postoperative complication rate was significantly lower in patients who underwent PD followed by surgical intervention versus surgical intervention at presentation (OR, 0.44; 95% CI, 0.23–0.83;  $p = 0.03$ ).<sup>109</sup> Resection under these circumstances should emphasize bowel preservation and avoid overaggressive resection, because the removal of bowel can lead to immediate or future development of short-bowel syndrome.<sup>103</sup>

Anti-TNF therapy in the setting of an inflammatory mass (ie, phlegmon) with a concomitant abscess typically carries a low risk when initiated after intravenous antibiotics and PD of the abscess, as needed.<sup>118</sup> Although conflicting studies have been published, the treatment strategy of drainage followed by anti-TNF therapy may prevent bowel resection in up to 30% of patients.<sup>111</sup>

**3. Patients with enteric fistulas that persist despite appropriate medical therapy should be considered for surgery. Grade of recommendation: Strong recommendation based on low-quality evidence, 1C.**

In the setting of penetrating disease with enteric fistulas, concomitant abscesses should be identified and drained

when feasible.<sup>119</sup> The inability to control intra-abdominal consequences of a penetrating phenotype (ie, abscess, phlegmon) usually warrants resection of the diseased bowel.<sup>120</sup> In a multicenter, retrospective study of 93 patients with intra-abdominal fistulizing CD (enteroenteric/colic 77%, enterovesicle 17%, enterovaginal 6%), 59% had a coexisting stricture, but none had a coexistent abscess; all patients were treated primarily with anti-TNF therapy with or without a concomitant immunomodulator, and surgery was eventually performed in 44% of patients.<sup>121</sup> In this study, the cumulative surgery rate was 18%, 27%, 37%, and 47% at 1, 2, 3, and 5 years from the induction of anti-TNF agents, and did not differ by fistula location; thus, surgery was avoided in over 50% of patients. A lower Crohn's Disease Activity Index<sup>122</sup> and shorter interval between the diagnosis of fistula and starting the monoclonal antibody were independently and significantly associated with lower risk of undergoing surgery. In other multicenter retrospective studies and systematic reviews of patients with enterovesicular fistulas, anti-TNF therapy has been shown to result in a complete and durable response in 45% to 57% of patients.<sup>123,124</sup>

When operative treatment is required, management requires differentiating diseased bowel from other loops of bowel or organs that are secondarily involved that may or may not require resection. In general, diseased bowel is resected, whereas noninflamed bowel can be primarily repaired and other internal organs (eg, bladder, vagina) can be repaired or left to heal by secondary intention, depending on the circumstances.<sup>125-129</sup> Of note, the mere presence of a fistula does not necessarily mandate surgery, especially in the absence of malabsorption, intractable diarrhea, or recurrent infection.<sup>116</sup>

## Hemorrhage

**1. Stable patients with gastrointestinal hemorrhage may be evaluated and treated by endoscopic and/or interventional radiologic techniques. Unstable patients, despite resuscitation efforts, should typically undergo operative exploration. Grade of recommendation: Strong recommendation based on low-quality evidence, 1C.**

Acute lower GI hemorrhage is an unusual complication of CD, occurring in 0.9% to 10% of patients with an incidence that correlates with disease duration.<sup>130-135</sup> Significant lower GI bleeding in patients with CD is more often secondary to severe inflammation and, unlike other more common sources of massive lower GI bleeding (eg, diverticula, arteriovenous malformation), rarely necessitates the diagnostic journey required in a bleed of unknown origin. Patients with significant bleeding should undergo concomitant resuscitation along with appropriate diagnostic measures, which, in stable patients, may include CT angiography, endoscopy, nuclear scintigraphy, and/or conventional mesenteric arteriography.<sup>136</sup> Although

not specific to CD, CT angiography in the setting of acute GI bleeding has sensitivity rates up to 89% and specificity rates up to 92%.<sup>136-138</sup> The likelihood of identifying a precise bleeding source is somewhat limited, because spontaneous cessation of bleeding occurs in nearly one-half of all patients with lower GI bleeding; however, recurrent bleeding occurs in nearly 40% of cases.<sup>129,133</sup> More specific to patients with CD, endoscopic clipping may be difficult in the presence of inflamed and friable mucosa and rebleeding in patients successfully managed with nonoperative measures may be reduced with anti-TNF therapy.<sup>130,133</sup>

In general, surgical treatment is recommended in patients with CD with life-threatening bleeding, persistent hemodynamic instability, or recurrent, significant GI bleeding following nonoperative measures. Although mortality related to surgical management is high (up to 7%), rates of rebleeding are much lower compared with nonsurgical intervention (6% versus 39%).<sup>130,139</sup> The primary challenges with surgical intervention are accurately identifying the bleeding site and effectively managing the risk of short-bowel syndrome with every additional segment of bowel removed, recognizing that two-thirds of patients with CD who bleed have otherwise quiescent disease.<sup>130</sup> Therefore, if the source of bleeding has been localized by using preoperative or intraoperative modalities, a targeted resection is typically recommended.<sup>139</sup> In cases of persistent hemodynamic instability or serious bleeding that cannot be localized to 1 segment of the colon, a total colectomy may be necessary.<sup>140</sup>

## Colorectal Dysplasia and Cancer

**1. Patients with long-standing Crohn's colitis involving at least one-third of the colon or more than 1 segment, should typically undergo endoscopic surveillance at regular intervals. Grade of recommendation: Strong recommendation based on moderate-quality evidence, 1B.**

In comparison with an age-matched general population, patients with Crohn's colitis have a 2- to 3-fold increased risk of colorectal cancer, similar to the risk of colorectal cancer developing in patients with UC.<sup>141,142</sup> Risk factors for colorectal cancer in patients with CD include disease extent (usually defined as the most extensive disease documented at any time point in a patient's course) and duration, a family history of colorectal cancer, and concomitant primary sclerosing cholangitis (PSC).<sup>141,143-146</sup> Although a diagnosis of dysplasia may precede or accompany the diagnosis of adenocarcinoma in patients with Crohn's colitis, cancer can also be the index neoplastic lesion.<sup>1,147-150</sup>

Although surveillance colonoscopy for patients with CD is endorsed by multiple societies, controversy persists regarding timing and intervals.<sup>151</sup> Patients, regardless of the extent of disease at initial diagnosis, should typically undergo screening colonoscopy within 8 years of the onset of symptoms. Exceptions are made for patients with

PSC who should typically begin screening at the time of diagnosis and then undergo surveillance annually. Patients with a strong family history of colorectal cancer (age <50, first-degree relative) should typically also undergo more frequent surveillance.<sup>141,151</sup> The recommendation for dysplasia detection in patients with CD is based largely on the experience with patients with UC and typically involves high-definition, white-light colonoscopy with nontargeted (random) 4-quadrant biopsies (often recommended to be taken at 10-cm intervals with a total of  $\geq 32$  biopsies) or chromoendoscopy with targeted biopsies.<sup>141,151-154</sup> The recommended interval for subsequent screening or surveillance endoscopic examination is determined by individualized risk assessment and varies according to different societies' guidelines; societies agree that surveillance is recommended for patients with involvement of at least one-third of the colon or more than one segment.<sup>141,152,155</sup> The European Crohn's and Colitis Organization recommends that patients at highest risk, those with PSC or a history of dysplasia or stricture, undergo annual colonoscopy; intermediate-risk patients with extensive or long-standing colitis or a family history of colorectal cancer undergo colonoscopy every 2 to 3 years; and patients without high or intermediate risk use a 5-year interval. Surveillance colonoscopy should ideally be performed when the colonic disease is in remission.<sup>156</sup> Meanwhile, the American Society for Gastrointestinal Endoscopy recommends that patients with PSC, active inflammation, history of dysplasia or colorectal cancer in a first-degree relative, or an anatomic abnormality such as a stricture have annual screening, preferably with chromoendoscopy or high-definition, white-light endoscopy, whereas average-risk patients can undergo surveillance every 1 to 3 years.<sup>157</sup> Average-risk patients with endoscopically and histologically normal examinations on 2 consecutive colonoscopies can usually extend their intervals to beyond every 3 years.<sup>158</sup>

**2. Patients with visible dysplasia that is completely excised endoscopically should typically undergo endoscopic surveillance. If dysplasia is not amenable to endoscopic excision, is also found in the surrounding flat mucosa, or is multifocal, or if colorectal adenocarcinoma is diagnosed, total colectomy or total proctocolectomy is typically recommended. Grade of recommendation: Strong recommendation based on moderate-quality evidence, 1B.**

In patients with colitis, endoscopic biopsies may be classified as negative for dysplasia, indefinite for dysplasia, low-grade dysplasia (LGD), or high-grade dysplasia (HGD) based on histopathology assessment by a gastroenterology-trained pathologist. The term "indefinite for dysplasia" usually applies to situations where the pathologist cannot distinguish between dysplastic and nondysplastic atypia or there are inflammatory-associated changes due to underlying inflammation that make histologic

interpretation difficult. Patients with indefinite dysplasia may benefit from optimizing medical management in an effort to promote mucosal healing and typically undergo repeat endoscopy in 3 to 12 months.<sup>159</sup> Low-grade dysplasia and HGD are differentiated based on the distribution of nuclei within the cells of the mucosa.<sup>141,155</sup> Low-grade dysplasia is characterized by nuclei confined to the basal half of the cells, whereas HGD has nuclei located haphazardly throughout the mucosal cells. The terms "dysplasia-associated lesion or mass" and "adenoma-like mass" are no longer commonly used and have been replaced with more simplified descriptors of visible or invisible lesions.<sup>160</sup> Visible lesions are described morphologically as polypoid (pedunculated or sessile) or nonpolypoid (slightly elevated, flat, or depressed) with borders classified as distinct or indistinct.<sup>154</sup> Other noteworthy descriptors include the presence of overlying ulceration and features of submucosal invasion such as depression or failure to lift with submucosal injection, which can predict inability to endoscopically resect and raise the suspicion for cancer.<sup>151</sup>

The management of patients who have CD with dysplasia continues to evolve over time and currently depends on whether or not the dysplasia is invisible or visible, or is unifocal or multifocal, and if complete endoscopic excision of a visible lesion is achieved.<sup>141,154</sup> The diagnosis of dysplasia on mucosal biopsy specimens is associated with a high level of interobserver variability, especially when diagnosing indefinite and low-grade dysplasia.<sup>161,162</sup> Therefore, if possible, at least 2 pathologists with expertise in GI diseases should evaluate specimens with dysplasia before implementing a management plan.<sup>152,163</sup>

Retrospective studies indicate that 64% to 92% of colorectal dysplasia in patients with IBD is visible.<sup>148,164,165</sup> Visible dysplastic lesions with LGD or HGD, in colitic or noncolitic mucosa, that are amenable to complete endoscopic excision (eg, dysplasia-free margins), without dysplasia in the flat mucosa immediately adjacent to the polypectomy site or elsewhere in the colon, should be treated with endoscopic excision when appropriate expertise is available.<sup>29,141,150,166</sup> En bloc excision is preferred over piecemeal removal to allow for histologic evaluation of the completeness of resection; this may require referral to a center experienced in advanced polypectomy techniques, including endoscopic mucosal resection and endoscopic submucosal dissection. Although the success with endoscopic mucosal resection and endoscopic submucosal dissection in the setting of CD has only been demonstrated in a limited number of small studies, and the long-term efficacy of these techniques with regard to preventing subsequent malignancy or surgery is unclear, these approaches may allow for a greater proportion of lesions to achieve complete endoscopic resection with negative margins.<sup>167-169</sup> Regardless of the technique used, a tattoo should typically be placed adjacent to the polypectomy



site after removing a large polyp to facilitate future surveillance and biopsies of the flat mucosa surrounding the polypectomy site evaluating for adjacent dysplasia should typically be obtained.<sup>151,170</sup>

Ongoing surveillance for patients with CD after having visible lesions endoscopically removed is based on the relatively low risk of developing cancer under careful surveillance in patients with UC. In studies reported after 2000, the incidence of HGD or cancer diagnosed at surveillance colonoscopy after removal of a visible dysplastic lesion in patients with UC was 3% to 18% with surveillance periods of 3 to 7 years.<sup>164,165,171–174</sup> In addition, a study of 18 patients with Crohn's colitis and 30 patients with UC who underwent endoscopic excision of a visible dysplastic lesion reported that 48% had recurrent dysplasia, but none were found to have cancer with a mean 4.1 years of follow-up.<sup>166</sup> However, because of the 10-fold increased risk of developing recurrent dysplasia, close endoscopic surveillance is recommended with surveillance colonoscopy performed within 1 to 6 months and again at 12 months after index lesion removal and should typically include biopsies taken at the prior excision site.<sup>151,175</sup>

For visible dysplastic lesions not amenable to endoscopic resection or with dysplasia in the surrounding flat mucosa, multifocal dysplasia, or cases of colorectal adenocarcinoma, total colectomy with ileorectal anastomosis or total proctocolectomy is typically recommended rather than segmental resection, because multifocal dysplasia is ultimately found in more than one-third of specimens from patients undergoing colectomy for LGD or HGD in the setting of Crohn's colitis.<sup>176,177</sup> Further support for total colectomy or total proctocolectomy comes from the observation that 14% to 40% of patients with Crohn's colitis who undergo segmental colorectal cancer resection develop metachronous colorectal cancer.<sup>176,177</sup> However, much of the supporting evidence regarding dysplasia and CD is based on research performed before the use of chromoendoscopy and high-definition, white-light colonoscopy. If adequate surveillance is possible, a total colectomy with ongoing endoscopic surveillance every 1 to 2 years is reasonable in patients with rectal-sparing disease; rectal cancer was reported in only 0.7% of patients with a preserved rectum following total colectomy with an ileorectal anastomosis.<sup>178</sup>

**3. Patients with invisible, indefinite dysplasia should typically be referred to an experienced endoscopist for repeat colonoscopy using enhanced imaging with repeat random biopsies within 3 to 12 months. Grade of recommendation: Strong recommendation based on low-quality evidence, 1C.**

When nontargeted (random) endoscopic biopsies are indefinite for dysplasia, subsequent surveillance colonoscopy in patients with UC identifies dysplasia in up to 28% of patients.<sup>141</sup> In a retrospective study of 84 patients

with CD or UC with mucosal biopsies indefinite for dysplasia (92% invisible), 13% of patients had LGD and 2% had HGD or malignancy found over a median surveillance period of 28 months.<sup>179</sup> In patients with CD or UC with nontargeted biopsies indefinite for dysplasia, both the 2010 American Gastroenterological Association and 2015 SCENIC guidelines recommend, ideally, repeating surveillance using high-definition colonoscopy with chromoendoscopy within 3 to 12 months.<sup>141,154</sup>

**4. Patients with invisible, low- or high-grade dysplasia on routine surveillance colonoscopy should typically be referred to an experienced endoscopist for high-definition colonoscopy with chromoendoscopy with repeat random biopsies within 3 to 6 months. Patients found to have invisible, low- or high-grade dysplasia at the time of high-definition colonoscopy with chromoendoscopy should typically undergo total colectomy or proctocolectomy. Grade of recommendation: Strong recommendation based on moderate-quality evidence, 1B.**

When nontargeted biopsies reveal dysplasia, patients with CD should ideally undergo high-definition colonoscopy with chromoendoscopy.<sup>158,180</sup> If repeat nontargeted biopsies reveal unifocal LGD or multifocal LGD confirmed by 2 gastroenterology-trained pathologists, total colectomy in cases with rectal sparing or proctocolectomy is typically recommended, based on the rates of progression to cancer in UC studies, because supporting data specific to CD are lacking. This recommendation in the setting of unifocal LGD is controversial, and, given the available evidence, it may be appropriate to offer selected patients frequent endoscopic surveillance as an alternative to resection. A 2012 prospective study of 42 patients who have UC with LGD reported progression of LGD in 19% of patients (2 developed cancer and 6 developed HGD), whereas 17% had persistent LGD and the remaining 64% had indefinite or no dysplasia identified over a median interval of 18 months.<sup>181</sup> Another meta-analysis of 671 patients who have UC with LGD found synchronous colorectal cancer in 17% of patients (11% of patients in studies published after 2000) and a 6.1% annual rate of dysplasia progression in patients with an initial diagnosis of invisible dysplasia.<sup>89,182</sup> A 2019 multicenter analysis of patients with IBD across 7 tertiary referral centers found that, of the 287 patients with LGD, 21 (7%) developed more advanced lesions (HGD or cancer) at a median follow-up of 86 months, and risk factors for the development of more advanced lesions included metachronous lesions, nonpolypoid lesions, and colon strictures. A single-center, retrospective review of 2130 patients with UC who underwent abdominal colectomy or proctocolectomy supports this lower rate of progression. Although 141 patients had a pre-colectomy diagnosis of LGD and 33 had HGD on random biopsy, cancer was identified in only 3 (2%) and 1 (3%) patients at the time of colon resection. Of the 1801 patients without a

preoperative diagnosis of dysplasia, 62 (3%) were found to have dysplasia in their colectomy specimen.<sup>183</sup>

Although the risk of colorectal cancer in Crohn's colitis and UC appears to be similar, specific data to guide the management of invisible LGD in Crohn's colitis are lacking.<sup>141,142,144,184</sup> A reasonable approach to invisible LGD in Crohn's colitis mirrors the approach to invisible LGD in UC and recommends total colectomy in the setting of rectal-sparing disease and total proctocolectomy in cases of rectal involvement, while allowing for individualized decision making with input from both the patient and a multidisciplinary IBD team recognizing the controversy noted above.<sup>185</sup>

As with invisible LGD, the management of invisible HGD in CD is similarly largely based on our knowledge of patients with UC. Although there are reports of synchronous cancer in 42% to 67% of patients with invisible HGD, a study of 59 patients who have UC with HGD diagnosed by endoscopic biopsy revealed LGD, HGD, or cancer in only 20 (34%), 3 (5%), and 1 (2%) patients.<sup>183</sup> Furthermore, a 2019 multicenter, retrospective study of 28 patients who have IBD with HGD across 7 IBD referral centers reported progression of HGD to cancer in only 4 patients (14%) who were surveyed over a median 180 months.<sup>148</sup> Although the rates of progression may be lower than previously thought, because of the possible progression to colorectal cancer or the presence of a synchronous unidentified lesion, if invisible HGD is confirmed, total colectomy or proctocolectomy is typically recommended.<sup>29,151,152,154</sup>

**5. Suspicious lesions (eg, mass, ulcer) identified in patients with Crohn's disease should be biopsied, especially when considering small-bowel or colonic strictureplasty. Grade of recommendation: Strong recommendation based on low-quality evidence, 1C.**

Suspicious lesions along the GI tract in patients with CD warrant evaluation with a diagnosis confirmed by pathology, when possible. The incidence of small-bowel carcinoma in patients with CD is 0.3/1000 person-years duration and this represents an 18.75-fold increase compared with an age-matched general population.<sup>186</sup> Although uncommon, cases of adenocarcinoma arising at or near previous strictureplasty sites have been reported,<sup>187-190</sup> and strictures of the colon are a significant risk factor for colonic adenocarcinoma.<sup>87</sup> Therefore, biopsy of strictures or suspicious ulcerations at the time of strictureplasty in long-standing disease can help guide therapy.

## **SITE-SPECIFIC OPERATIONS**

**1. Patients with symptomatic disease of the stomach or duodenum despite medical therapy should typically be considered for endoscopic dilation, bypass, or**

**strictureplasty. Grade of recommendation: Strong recommendation based on low-quality evidence, 1C.**

Gastroduodenal disease occurs in 0.5% to 4% of patients with CD with the most common presenting phenotype being stricturing disease.<sup>191</sup> Although obstructive symptoms can be managed endoscopically or surgically with bypass, strictureplasty, or resection, there are no trials comparing the efficacy of these approaches. Single, short, moderately thick strictures of the duodenum without associated penetrating disease can usually be successfully treated with endoscopic dilation as the initial procedure, but there is a risk of recurrent stenosis.<sup>192-194</sup>

When endoscopic intervention is not feasible or ineffective, surgical management can be performed with bypass (ie, gastrojejunostomy, duodenojejunostomy) or strictureplasty, both of which are typically preferred over resection because of decreased overall morbidity. Patients best suited for strictureplasty have nonperforated, nonphlegmonous stenotic lesions and/or lesions in the second or third portion of the duodenum.<sup>195-199</sup> Retrospective reviews have conflicting results; one series favored bypass because of its decreased postoperative complications and need for reoperation and a longer interval to reoperation, whereas another series concluded that strictureplasty was the preferred approach because of the lower risks for major complications and reoperation.<sup>199,200</sup> Procedure choice depends on the anatomy of the affected duodenum, number and length of strictures, and surgeon experience. If the affected portion of the duodenum is technically difficult to mobilize, it may be best to bypass; however, bypass can result in delayed gastric emptying or marginal ulcer formation; thus, a strictureplasty is usually preferred when technically feasible.<sup>201</sup>

**2. Patients with medically refractory disease isolated to the jejunum, ileum, or ileocolon without existing or anticipated short-bowel syndrome should typically undergo escalation of medical therapy or resection of the affected bowel, ideally, as determined by a multidisciplinary team. For patients undergoing an operation with multifocal disease, strictureplasty should be considered. Grade of recommendation: Strong recommendation based on low-quality evidence, 1C.**

Ileocolic resection is the most commonly performed operation for CD.<sup>202</sup> Early resection rather than the initiation of monoclonal antibody therapy may be appropriate in patients with limited, nonstricturing ileocecal CD as supported by a randomized, controlled trial that compared early laparoscopic ileocecal resection (n = 73) and infliximab initiation (n = 70) and demonstrated improved quality-of-life scores and decreased overall cost in the operative group.<sup>31,203</sup> At the time of resection, limited macroscopic disease-free resection margins of about 2 cm are usually adequate to conserve bowel length and have not

been associated with an increased risk of disease recurrence.<sup>67</sup> In the setting of multifocal stricturing disease, especially in situations with longer segments of uninvolved intervening small bowel, strictureplasty is the preferred strategy for bowel conservation and has low rates of disease recurrence at strictureplasty sites.<sup>81,204</sup>

**3. The procedure of choice for emergency surgery in Crohn's colitis is a total abdominal colectomy with end ileostomy. Grade of recommendation: Strong recommendation based on low-quality evidence, 1C.**

Total (or, in appropriate circumstances, a subtotal) colectomy with construction of an end ileostomy and closure of the distal colon or construction of a mucous fistula is typically recommended in patients with severe or fulminant Crohn's colitis who require emergency surgery.<sup>205</sup> This approach removes the involved colon while avoiding a pelvic dissection and the risks of an anastomosis. Extrafascial placement of the closed stump may be associated with fewer pelvic septic complications compared with leaving the stump intraperitoneally, although it may be technically challenging to position the stump above the fascia.<sup>206-209</sup> Transanal drainage of the rectum may further decrease the risk of pelvic sepsis under these circumstances.<sup>210</sup>

**4. Patients with colonic disease and rectal sparing who proceed with elective surgery may undergo segmental colectomy for single-segment disease or total colectomy for more extensive disease. Grade of recommendation: Strong recommendation based on moderate-quality evidence, 1B.**

Outside the aforementioned circumstances regarding dysplasia and malignancy, symptomatic disease of the colon with rectal sparing can be managed by removal of only the diseased segment or by total abdominal colectomy. A meta-analysis of 11 studies including 1010 patients who underwent segmental colectomy ( $n = 500$ ) or total colectomy ( $n = 510$ ) for CD reported no difference with respect to CD recurrence, but segmental colectomy was associated with a decreased risk of a permanent stoma compared with total colectomy (OR, 0.52; 95% CI, 0.35–0.77).<sup>211</sup> Another meta-analysis of 6 studies including 488 patients reported no significant differences in complications or rates of permanent stoma creation between patients who underwent segmental colectomy versus total colectomy, but the segmental colectomy group had a shorter interval to surgical recurrence (defined as the need for reoperation as a result of a CD-related complication or failed medical therapy) compared with the total colectomy group (weighted mean difference 4.4 years).<sup>211,212</sup> When 2 or more colonic segments are affected, total colectomy with ileoproctostomy is typically preferred because of earlier recurrence following segmental resection.<sup>212</sup>

**5. For patients undergoing elective surgery for rectal disease, total proctocolectomy with end ileostomy or**

**proctectomy with creation of a colostomy should typically be performed. Grade of recommendation: Strong recommendation based on low-quality evidence, 1C.**

Refractory Crohn's proctitis, in general, warrants total proctocolectomy with a permanent ileostomy owing to its frequent association with concomitant colonic disease. Proctectomy alone with creation of a colostomy can be considered if the colon is spared, but a proctocolectomy is typically recommended in the presence of perianal disease because of the high rates of disease recurrence in the colon and/or at the colostomy following proctectomy with end colostomy creation under these circumstances.<sup>213</sup> When a proctectomy is performed, the entire rectum and anal canal should typically be resected because carcinoma has been described in patients left with even a short rectal remnant, and the resection should typically incorporate a total mesorectal excision because of potentially impaired perineal wound healing associated with a close rectal dissection.<sup>214,215</sup> Furthermore, in cases that do not require an oncologic distal dissection, an intersphincteric approach with primary closure of the perineal wound is preferred, in general, because it is associated with fewer wound complications and decreased overall surgical morbidity compared with a traditional abdominoperineal resection.<sup>216</sup> In cases of proctitis with severe fistulizing perianal disease, patients may be approached in a staged manner starting with fecal diversion and drainage of any active perianal sepsis, because proctectomy under these circumstances may result in a large perineal defect requiring flap reconstruction. Patients undergoing staged operations who experience continued local sepsis despite diversion and medical therapy may still require a more extensive perianal excision rather than an intersphincteric approach.

**6. Restorative proctocolectomy with IPAA may be offered to selected patients with Crohn's disease without perianal or small-bowel disease, recognizing that long-term pouch failure rates are increased in this population. Grade of recommendation: Weak recommendation based on low-quality evidence, 2C.**

Creating an ileal pouch in patients specifically known to have CD (as opposed to patients diagnosed with CD after having pouch surgery) has remained controversial since the first reported series of 31 patients in 1996.<sup>217</sup> There are no randomized, controlled trials evaluating this issue and most case series are small and show pouch failure rates (pouch excision or proximal diversion) of 3% to 56%.<sup>217-224</sup> In a series of 32 patients diagnosed with CD after undergoing IPAA, 93% experienced pouch-related complications (eg, fistula, stricture, sepsis) and the overall pouch failure rate was 29%.<sup>225</sup> In a retrospective review including 204 patients who underwent IPAA for CD (10% of the patients were diagnosed with CD before pouch surgery, 47% were diagnosed by histopathology at the time of

the pouch surgery, and 43% were diagnosed in a delayed fashion at a median of 36 months after IPAA), pouch retention rates and functional outcomes were better when the diagnosis of CD was made before or at the time of ileal pouch formation. The pouch failure rate was 15% in patients diagnosed with CD before or at the time of IPAA and was 51% for patients diagnosed in a delayed fashion ( $p < 0.001$ ).<sup>226</sup>

After IPAA, overall functional outcomes and quality of life have been shown to be similar in patients with CD who are able to keep their pouch compared with patients with UC who had a pouch.<sup>227</sup> The 2018 clinical practice guideline from the European Crohn's and Colitis Organization and the European Society of Colo-Proctology supported IPAA in carefully selected patients who had CD without perianal or small-bowel disease, but noted that the long-term pouch failure rate is increased in these patients.<sup>228</sup>

## PREOPERATIVE CONSIDERATIONS

**1. Preoperative high-dose glucocorticoids increase the risk of postoperative infectious complications and attempts should typically be made to wean glucocorticoids before surgical intervention. Immunomodulators are not associated with increased risk of postoperative infectious complications and do not typically need to be held before surgery. Grade of recommendation: Strong recommendation based on low-quality evidence, 1C.**

The majority of patients with CD evaluated for surgical intervention have been exposed to immunosuppressive therapy in the attempt to control inflammation and achieve disease remission.<sup>229</sup> Glucocorticoids are a known risk factor for increased 30-day postoperative infectious complications after bowel surgery, with some studies suggesting that this risk is increased with daily doses  $>20$  mg.<sup>230</sup> For risk reduction purposes, attempts should typically be made to wean patients' glucocorticoids at least to a daily dose  $<20$  mg before surgical intervention, if possible. Conversely, immunomodulators are not associated with increased risk of postoperative complications and can typically be safely continued in the perioperative period.<sup>222,229–231</sup>

**2. Whether or not preoperative exposure to monoclonal antibody therapy influences outcomes remains controversial, but delaying surgical intervention based on monoclonal antibody therapy alone is not typically recommended. Grade of recommendation: Weak recommendation based on low-quality evidence, 2C.**

Data regarding the association of preoperative exposure to monoclonal antibody therapy including anti-TNF agents and vedolizumab (a monoclonal integrin antagonist) in terms of postoperative complications remain controversial because of the heterogeneity in patient populations

and study designs.<sup>30,229,232–244</sup> A multicenter, prospective, cohort study of 209 patients undergoing ileocecal resection for CD found no significant association between using anti-TNF agents or anti-TNF serum drug levels and postoperative complications.<sup>234</sup> Preliminary data from the PUCCINI multicenter, prospective, observational analysis also revealed no association between preoperative anti-TNF agents or their serum levels and postoperative infectious complications in patients with IBD.<sup>245</sup> Meanwhile, prospectively collected, risk-adjusted data from a French collaborative identified anti-TNF therapy within 3 months of an ileocecal resection for CD as an independent predictor of 30-day postoperative overall and intra-abdominal septic morbidity.<sup>233</sup> Similarly, a 2019 systematic review and meta-analysis with risk adjustment identified preoperative anti-TNF therapy as a risk factor for postsurgical complications in patients with CD.<sup>246</sup> Further confounding the issue, a single-center, retrospective study found that preoperative serum anti-TNF drug levels directly correlated with postoperative complications after CD surgery, but a large, prospective study in which serum drug levels were analyzed from the day of surgery found no association between serum drug levels and postoperative complications.<sup>233,238,247</sup>

Whether or not preoperative exposure to vedolizumab increases postoperative morbidity also remains controversial because a variety of types of studies report conflicting results.<sup>242,244,248–250</sup> When only patients with CD were analyzed, as compared with pooled data from patients with UC and CD, a single-center, retrospective review compared 100 vedolizumab-exposed patients, 107 patients treated with anti-TNF agents, and 105 monoclonal antibody-naïve patients, and found vedolizumab to be an independent predictor of postoperative surgical site infection but not intra-abdominal septic complications.<sup>229</sup> This article recommended that, although vedolizumab-treated patients with CD may be a sicker cohort of patients, it is important to consider these findings with regard to preoperative counseling, operative timing, and primary closure of wounds.

Ustekinumab, a monoclonal interleukin-12 and -23 blocker approved by the Food and Drug Administration in 2016 for the treatment of moderate to severe CD, has very limited data regarding its use and potential effects on postoperative outcomes. A consortium of 6 IBD centers retrospectively compared 44 patients treated with ustekinumab with 169 patients treated with anti-TNF agents and found no difference in postoperative outcomes after CD surgery.<sup>251</sup> A single-center, retrospective review of patients with CD similarly found no difference in postoperative outcomes among 30 patients treated with ustekinumab compared with 73 patients treated with vedolizumab.<sup>252</sup>

Given the literature regarding monoclonal antibody therapy, in general, it is not recommended to delay

surgical intervention due to monoclonal antibody therapy alone, because the data do not consistently show any class of monoclonal antibody to be an independent risk factor for postoperative infectious complications.<sup>253</sup> Rather, when possible, if a patient is on an every 8 weeks dosing regimen, the optimal time to perform surgery may be approximately 4 weeks after the last monoclonal antibody dose to allow for a washout period of about one half-life, with the plan to resume the monoclonal antibody about 4 weeks after surgery, if necessary, for postoperative treatment or prophylaxis.<sup>254</sup>

**3. Preoperative nutritional support for patients with malnutrition may decrease postoperative morbidity. Grade of recommendation: Weak recommendation based on low-quality evidence, 2C.**

Malnutrition may be variably defined as greater than 10% weight loss in the previous 3 months, BMI <18.5 kg/m<sup>2</sup> or serum albumin <3.0 mg/dL, although serum albumin is a relatively poor marker of malnutrition because levels can be affected by other processes like inflammation or sepsis.<sup>255</sup> Malnutrition, found in up to 85% of patients with CD, significantly increases the risk of postoperative complications.<sup>256,257</sup> A systematic review of 29 studies regarding preoperative nutritional support in patients with CD found malnutrition to be associated with increased postoperative morbidity and preoperative nutritional support to be associated with improved outcomes.<sup>258</sup> According to the European Society for Clinical Nutrition and Metabolism 2017 guidelines, malnourished patients with CD who cannot meet their caloric needs by eating, should be given preoperative exclusive enteral nutrition (EEN), a preformulated liquid diet, to decrease the risk of postoperative morbidity.<sup>255</sup> Several retrospective studies of patients with CD undergoing intestinal resection have shown that 4 weeks to 3 months of preoperative EEN significantly decreased postoperative complications, superficial surgical site infection, intra-abdominal septic complications, infectious complications, and the total comprehensive complication index.<sup>259–262</sup> In a large study of 498 patients with CD undergoing surgery, preoperative EEN was associated with significantly decreased rates of intestinal diversion, anastomotic leak, and reoperation.<sup>263</sup> Total parenteral nutrition can be used when patients are unable to tolerate oral intake.<sup>257</sup>

**4. Smoking cessation may reduce postoperative morbidity in patients with Crohn's disease. Grade of recommendation: Strong recommendation based on low-quality evidence, 1C.**

Smoking has a known deleterious impact on the severity, exacerbations, and recurrence of CD and is associated with increased rates of hospitalization for disease flares and of postoperative disease recurrence.<sup>264</sup> Retrospective data also indicate that active smoking is associated with

increased postoperative complications. A retrospective National Surgical Quality Improvement Program study of patients with CD who underwent resection found that active smokers (n = 2047) had significantly increased rates of postoperative infectious complications (OR, 1.30;  $p < 0.001$ ), pulmonary complications (OR, 1.87;  $p < 0.001$ ), and readmissions (OR, 1.58;  $p = 0.004$ ) compared with nonsmokers (n = 5584).<sup>265</sup> However, in another single-institution, retrospective review of 691 patients with CD, smoking was not significantly associated with postoperative complications.<sup>266</sup>

## OPERATIVE CONSIDERATIONS

**1. A minimally invasive approach to Crohn's disease surgery should typically be considered. Grade of recommendation: Strong recommendation based on moderate-quality evidence, 1B.**

Randomized, controlled trials of patients with CD undergoing elective ileocelectomy have demonstrated shorter length of stay, fewer complications, decreased cost, and improved pulmonary function related to the laparoscopic approach in comparison with open surgery and comparable clinical recurrence rates.<sup>267–269</sup> National Surgical Quality Improvement Program database studies regarding elective and emergency surgery for CD showed that laparoscopy (when possible) was associated with decreased morbidity and a shorter length of stay after emergency or elective ileocelectomy.<sup>270–273</sup> In addition, a laparoscopic approach to colorectal resection is associated with lower risks of subsequent small-bowel obstruction and operation for small-bowel obstruction, which is particularly relevant to patients with CD who may ultimately require multiple operations.<sup>274</sup>

Another factor that may support using a laparoscopic platform over open surgery when operating on patients with CD deals with the incidence of incisional hernia. In a single-institution, retrospective review of patients with CD, the incisional hernia rates of laparoscopic and open surgery were similar (8.4% versus 10.8%) when a midline incision was used. In the 37 patients who had an intracorporeal anastomosis and an extraction site that used a transverse incision, the incisional hernia rate was zero.<sup>275</sup> Single-institution, retrospective series have also shown that laparoscopic resection in patients who have CD with a penetrating phenotype or with obesity has morbidity equivalent to laparoscopic surgery in patients who have CD without these risk factors.<sup>276,277</sup>

In terms of the potential utility of a robotic approach for operating on patients with CD, a national database was used to perform a propensity score-matched analysis with 108 patients in each cohort and found that, compared with open surgery, a robotic approach had a shorter length of stay by a median of 2 days ( $p < 0.001$ ) and a lower 30-day

complication rate (24% versus 38%;  $p = 0.03$ ).<sup>278</sup> When robotic total colectomy was compared with multiport laparoscopy for all pathologic indications using data from the nationwide inpatient sample database, there was no improvement in morbidity related to the use of robotics.<sup>279</sup> Although single-incision laparoscopy has been shown to be feasible in cases of complex CD, it has not demonstrated consistent advantages over multiport laparoscopy.<sup>280–285</sup>

**2. A diverting ileostomy should be considered when performing ileocelectomy in patients who have Crohn's disease with multiple risk factors. Grade of recommendation: Strong recommendation based on moderate-quality evidence, 1B.**

Although the majority of patients with CD who undergo an ileocelectomy may have a primary anastomosis with an acceptable anastomotic leak rate, patients with multiple risk factors (eg, smoking, steroid use, weight loss) have an increased risk of anastomotic leak, and temporary diversion should typically be considered in these situations.<sup>286</sup> Overall, the decision to divert or omit an anastomosis should depend on an individualized assessment of the risk factors for surgical complications and should consider that an ileostomy carries its own risk profile (eg, dehydration, acute renal insufficiency, need for subsequent reversal).<sup>287</sup> A defunctioning ileostomy should typically be considered in patients with CD who are on high-dose glucocorticoids, in particular, in combination with other CD medications (eg, immunomodulators or monoclonal antibodies), are profoundly malnourished or anemic, have a chronic bowel obstruction, or, potentially, have had prior bowel resection.<sup>234,239,288–290</sup>

An additional potential benefit of temporary ileostomy creation after ileocelectomy is that it is associated with reduced long-term risk of surgical recurrence in active smokers and patients with penetrating disease.<sup>291</sup> Another study, published in abstract form only, demonstrated a reduced risk of endoscopic recurrence at 3 years if an ileostomy was left in place an average of 3 months after ileocelectomy.<sup>292</sup>

**3. The extent of mesenteric excision during resection for Crohn's disease remains controversial. Grade of recommendation: Weak recommendation based on low-quality evidence, 2C.**

Basic science research suggests that the mesentery plays a role in IBD, but the exact mechanism remains unclear.<sup>293</sup> In 2018, Coffey et al<sup>69</sup> published a retrospective review comparing a cohort of patients with CD who had undergone conventional ileocolic resection with mesenteric division close to the intestine ( $n = 30$ ) with a group of patients who had undergone a more extended excision of the adjacent mesentery ( $n = 34$ ). The cumulative reoperation rates for CD were 40% for the standard group versus 2.9% for the extended mesenteric excision group ( $p = 0.003$ )

with a mean duration of follow-up of 70 and 52 months. The authors also demonstrated that advanced mesenteric disease, as assessed grossly by the degree of fat wrapping, predicted increased surgical recurrence (HR, 4.7; 95% CI, 1.71–13.01;  $p = 0.003$ ). Although these results seem compelling, others have pointed out several concerns with the study.<sup>294</sup> For instance, the standard resection group had surgery many years before the extended mesenteric excision group at a time when surveillance was performed differently, medical management was less effective, and postoperative medical therapy to maintain patients in remission was not as commonly utilized. In addition, the standard resection group had longer follow-up potentially allowing for the detection of a higher recurrence rate. The underlying theory behind the Coffey study was also called into question by preliminary data from a trial involving the Kono-S anastomosis that involves a limited mesenteric excision that showed a decreased risk of endoscopic CD recurrence 6 months postoperatively.<sup>295,296</sup>

**4. Following ileocecal resection, reconstruction using side-to-side, side-to-end, or end-to-end handsewn or stapled anastomosis based on surgeon preference and experience is reasonable. Grade of recommendation: Strong recommendation based on low-quality evidence, 1C.**

The data regarding anastomotic technique, leak, and recurrence after ileocolic anastomosis in CD are limited. A Cochrane database meta-analysis including 264 noncancer patients including patients with CD from 3 randomized, controlled trials compared stapled versus handsewn anastomoses in patients undergoing ileocelectomy and found no significant difference in leak rates.<sup>70</sup> This meta-analysis was largely based on data from 1 randomized trial that showed no difference in leak or CD recurrence rates related to anastomotic technique.<sup>72</sup> Case series regarding patients with CD have favored stapled anastomosis and oversewing of the stapled anastomosis that may be associated with a decreased leak rate; however, the quality of these data is low.<sup>297,298</sup> In addition, 1 larger retrospective review involving 233 patients with CD compared the results between side-to-side, side-to-end, and end-to-end stapled and handsewn anastomoses and identified no difference in the need for reoperation for recurrent disease over a median follow-up of 93 months.<sup>299</sup> Another large retrospective review of 1437 patients from 200 centers in Europe compared cutting with noncutting staplers and oversewing the staple line versus not oversewing the staple line following ileocelectomy (14% of the patients had CD) and found no differences in leak rates with any of the techniques used.<sup>300</sup> A single-institution review compared 60 patients with CD who underwent bowel resection with stapled side-to-side anastomosis to 68 patients who had a handsewn end-to-end anastomosis. In the 2 years after resection, patients in the stapled group had significantly more emergency department visits, hospitalizations, and

abdominal CT scans, and lower quality-of-life scores, but had comparable 30-day postoperative complications and 2-year clinical, endoscopic, and surgical recurrence.<sup>301</sup>

## POSTOPERATIVE CONSIDERATIONS

**1. After surgery for Crohn's disease, patients should be considered for medical therapy to treat residual active disease or to maintain disease remission. Grade of recommendation: Strong recommendation based on moderate-quality evidence, 1B.**

After an ileocectomy, 70% to 90% of patients have endoscopic recurrence in the neoterminal ileum at 1 year, and, by 3 years, endoscopic recurrence is ubiquitous.<sup>302,303</sup> At 5 years, an estimated 50% of patients will have evidence of clinical recurrence and 25% will experience a surgical recurrence. At 10 years, the rate of surgical recurrence may reach as high as 35%.<sup>14</sup> Perioperative risk factors for recurrence include age at diagnosis of CD <30 years, <10 years between diagnosis and surgery, presence of perianal disease, penetrating phenotype, 2 or more prior intestinal resections, and active tobacco use.<sup>302,304</sup> According to the American Gastroenterological Association guidelines, patients can be grouped according to their risk of recurrence as low risk (patient age >50 years, nonsmoker, first surgery for short segment of fibrostenotic disease less than 10–20 cm, and disease duration >10 years) or high risk (patient age <30 years, active smoking, 2 or more prior surgeries for penetrating disease with or without perianal disease).<sup>305</sup>

In low-risk patients without ongoing, active CD, pharmacologic prophylaxis is not typically recommended.<sup>305</sup> However, metronidazole or ornidazole can be considered for prevention of clinical postoperative recurrence, although, even with this prophylaxis, endoscopic recurrence remains problematic and patients risk having side effects from the long-term use of these agents.<sup>306–308</sup> In general, metronidazole use should be limited to about 3 months under these circumstances. At 6 months postoperatively, low-risk patients should typically undergo ileocolonoscopy with Rutgeerts scoring, a scoring system developed in the early 1990s to predict postoperative recurrence based on the extent and severity of lesions detected at the ileocecal anastomosis and neoterminal ileum, with scores ranging from i,0 (no lesions) to i,4 (diffuse inflammation with larger ulcers, nodules, and/or narrowing).<sup>13</sup> Asymptomatic patients with a Rutgeerts score <i>2 should typically repeat an ileocolonoscopy in 1 to 3 years. If the Rutgeerts score is  $\geq$ i,2, an anti-TNF (or other monoclonal antibody agent if the patient had previously lost response or had no response, per gastroenterology management) should typically be started with or without a thiopurine. The PREVENT trial randomly assigned 297 patients with CD after ileocectomy to infliximab or placebo and found that the

treatment group had lower endoscopic recurrence (22.4% versus 51.3%;  $p < 0.001$ ), but the clinical recurrence rates were similar between the 2 groups. A meta-analysis of 10 randomized, controlled trials evaluated CD recurrence and found that anti-TNF therapy was associated with the greatest reduction in clinical and endoscopic recurrence.<sup>309,310</sup> When comparing types of anti-TNF monotherapy for postoperative prophylaxis, a retrospective, multicenter, observational study found that infliximab and adalimumab were equivalent; meanwhile, anti-integrins (vedolizumab), anti-interleukins (ustekinumab), and small molecules have not yet been adequately studied in the setting of prophylaxis.<sup>311</sup>

In patients with residual disease after surgery or in patients who are otherwise high risk for recurrence, postoperative treatment or prophylaxis, depending on the circumstances, can typically start within 2 to 4 weeks after surgery, with input from gastroenterology and barring postoperative infectious complications. As with low-risk patients, an anti-TNF agent with or without a thiopurine is typically recommended. Patients receiving postoperative pharmacologic prophylaxis should typically undergo standardized ileocolonoscopy after 6 months to evaluate disease status and allow for further escalation of medical therapy, as needed. With this treatment approach, 18-month clinical and endoscopic recurrence are reduced compared with ongoing pharmacologic prophylaxis alone.<sup>304,312</sup>

## REFERENCES

- Dahlhamer JM, Zammitti EP, Ward BW, Wheaton AG, Croft JB. Prevalence of inflammatory bowel disease among adults aged  $\geq$ 18 years – United States, 2015. *MMWR Morb Mortal Wkly Rep.* 2016;65:1166–1169.
- Colombel JF, Sandborn WJ, Rutgeerts P, et al. Adalimumab for maintenance of clinical response and remission in patients with Crohn's disease: the CHARM trial. *Gastroenterology.* 2007;132:52–65.
- Hanauer SB, Feagan BG, Lichtenstein GR, et al; ACCENT I Study Group. Maintenance infliximab for Crohn's disease: the ACCENT I randomised trial. *Lancet.* 2002;359:1541–1549.
- Hanauer SB, Sandborn WJ, Rutgeerts P, et al. Human anti-tumor necrosis factor monoclonal antibody (adalimumab) in Crohn's disease: the CLASSIC-I trial. *Gastroenterology.* 2006;130:323–333.
- Sandborn WJ, Feagan BG, Stoinov S, et al; PRECISE 1 Study Investigators. Certolizumab pegol for the treatment of Crohn's disease. *N Engl J Med.* 2007;357:228–238.
- Schreiber S, Khaliq-Kareemi M, Lawrance IC, et al; PRECISE 2 Study Investigators. Maintenance therapy with certolizumab pegol for Crohn's disease. *N Engl J Med.* 2007;357:239–250.
- Rutgeerts P, Feagan BG, Lichtenstein GR, et al. Comparison of scheduled and episodic treatment strategies of infliximab in Crohn's disease. *Gastroenterology.* 2004;126:402–413.
- Sandborn WJ, Rutgeerts P, Enns R, et al. Adalimumab induction therapy for Crohn disease previously treated with infliximab: a randomized trial. *Ann Intern Med.* 2007;146:829–838.

9. Bonovas S, Fiorino G, Allocca M, et al. Biologic therapies and risk of infection and malignancy in patients with inflammatory bowel disease: a systematic review and network meta-analysis. *Clin Gastroenterol Hepatol*. 2016;14:1385–1397.e10.
10. Frolkis AD, Dykeman J, Negrón ME, et al. Risk of surgery for inflammatory bowel diseases has decreased over time: a systematic review and meta-analysis of population-based studies. *Gastroenterology*. 2013;145:996–1006.
11. Ma C, Moran GW, Benchimol EI, et al. Surgical rates for Crohn's disease are decreasing: a population-based time trend analysis and validation study. *Am J Gastroenterol*. 2017;112:1840–1848.
12. Olaison G, Smedh K, Sjö Dahl R. Natural course of Crohn's disease after ileocolic resection: endoscopically visualised ileal ulcers preceding symptoms. *Gut*. 1992;33:331–335.
13. Rutgeerts P, Geboes K, Vantrappen G, Beys J, Kerremans R, Hiele M. Predictability of the postoperative course of Crohn's disease. *Gastroenterology*. 1990;99:956–963.
14. Frolkis AD, Lipton DS, Fiest KM, et al. Cumulative incidence of second intestinal resection in Crohn's disease: a systematic review and meta-analysis of population-based studies. *Am J Gastroenterol*. 2014;109:1739–1748.
15. Strong S, Steele SR, Boutrous M, et al; Clinical Practice Guidelines Committee of the American Society of Colon and Rectal Surgeons. Clinical Practice Guideline for the Surgical Management of Crohn's Disease. *Dis Colon Rectum*. 2015;58:1021–1036.
16. Migaly J, Bafford AC, Francone TD, et al; Clinical Practice Guidelines Committee of the American Society of Colon and Rectal Surgeons. The American Society of Colon and Rectal Surgeons Clinical Practice Guidelines for the Use of Bowel Preparation in Elective Colon and Rectal Surgery. *Dis Colon Rectum*. 2019;62:3–8.
17. Carmichael JC, Keller DS, Baldini G, et al. Clinical Practice Guidelines for Enhanced Recovery After Colon and Rectal Surgery From the American Society of Colon and Rectal Surgeons and Society of American Gastrointestinal and Endoscopic Surgeons. *Dis Colon Rectum*. 2017;60:761–784.
18. Fleming F, Gaertner W, Ternent CA, et al. The American Society of Colon and Rectal Surgeons Clinical Practice Guideline for the Prevention of Venous Thromboembolic Disease in Colorectal Surgery. *Dis Colon Rectum*. 2018;61:14–20.
19. Vogel JD, Johnson EK, Morris AM, et al. Clinical Practice Guideline for the Management of Anorectal Abscess, Fistula-in-Ano, and Rectovaginal Fistula. *Dis Colon Rectum*. 2016;59:1117–1133.
20. Guyatt G, Gutterman D, Baumann MH, et al. Grading strength of recommendations and quality of evidence in clinical guidelines: report from an American College of Chest Physicians task force. *Chest*. 2006;129:174–181.
21. Schünemann HJ, Jaeschke R, Cook DJ, et al; ATS Documents Development and Implementation Committee. An official ATS statement: grading the quality of evidence and strength of recommendations in ATS guidelines and recommendations. *Am J Respir Crit Care Med*. 2006;174:605–614.
22. Panaccione R, Steinhart AH, Bressler B, et al. Canadian Association of Gastroenterology Clinical Practice Guideline for the Management of Luminal Crohn's Disease. *Clin Gastroenterol Hepatol*. 2019;17:1680–1713.
23. D'Haens G, Lemmens L, Geboes K, et al. Intravenous cyclosporine versus intravenous corticosteroids as single therapy for severe attacks of ulcerative colitis. *Gastroenterology*. 2001;120:1323–1329.
24. Sands BE, Tremaine WJ, Sandborn WJ, et al. Infliximab in the treatment of severe, steroid-refractory ulcerative colitis: a pilot study. *Inflamm Bowel Dis*. 2001;7:83–88.
25. Lichtiger S, Present DH, Kornbluth A, et al. Cyclosporine in severe ulcerative colitis refractory to steroid therapy. *N Engl J Med*. 1994;330:1841–1845.
26. Azzopardi N, Ellul P. Risk factors for osteoporosis in Crohn's disease: infliximab, corticosteroids, body mass index, and age of onset. *Inflamm Bowel Dis*. 2013;19:1173–1178.
27. Hudesman D, Lichtiger S, Sands B. Risk of extraintestinal solid cancer with anti-TNF therapy in adults with inflammatory bowel disease: review of the literature. *Inflamm Bowel Dis*. 2013;19:644–649.
28. Dignass A, Van Assche G, Lindsay JO, et al; European Crohn's and Colitis Organisation (ECCO). The second European evidence-based consensus on the diagnosis and management of Crohn's disease: current management. *J Crohns Colitis*. 2010;4:28–62.
29. Gomollón F, Dignass A, Annese V, et al; ECCO. 3rd European evidence-based consensus on the diagnosis and management of Crohn's disease 2016: Part 1: diagnosis and medical management. *J Crohns Colitis*. 2017;11:3–25.
30. Yang ZP, Hong L, Wu Q, Wu KC, Fan DM. Preoperative infliximab use and postoperative complications in Crohn's disease: a systematic review and meta-analysis. *Int J Surg*. 2014;12:224–230.
31. Ponsioen CY, de Groof EJ, Eshuis EJ, et al; LIR!C study group. Laparoscopic ileocaecal resection versus infliximab for terminal ileitis in Crohn's disease: a randomised controlled, open-label, multicentre trial. *Lancet Gastroenterol Hepatol*. 2017;2:785–792.
32. Hanauer SB. Inflammatory bowel disease. *N Engl J Med*. 1996;334:841–848.
33. Sinagra E, Orlando A, Mocchiari F, et al. Clinical course of severe colitis: a comparison between Crohn's disease and ulcerative colitis. *J Biol Regul Homeost Agents*. 2018;32:415–423.
34. Truelove SC, Witts LJ. Cortisone in ulcerative colitis; final report on a therapeutic trial. *Br Med J*. 1955;2:1041–1048.
35. Sheth SG, LaMont JT. Toxic megacolon. *Lancet*. 1998;351:509–513.
36. Autenrieth DM, Baumgart DC. Toxic megacolon. *Inflamm Bowel Dis*. 2012;18:584–591.
37. Lewis JD. The utility of biomarkers in the diagnosis and therapy of inflammatory bowel disease. *Gastroenterology*. 2011;140:1817–1826.e2.
38. Carter MJ, Lobo AJ, Travis SP; IBD Section, British Society of Gastroenterology. Guidelines for the management of inflammatory bowel disease in adults. *Gut*. 2004;53(suppl 5):V1–16.
39. Carbonnel F, Gargouri D, Lémann M, et al. Predictive factors of outcome of intensive intravenous treatment for attacks of ulcerative colitis. *Aliment Pharmacol Ther*. 2000;14:273–279.
40. Pola S, Patel D, Ramamoorthy S, et al. Strategies for the care of adults hospitalized for active ulcerative colitis. *Clin Gastroenterol Hepatol*. 2012;10:1315–1325.e4.
41. Sheasgreen C, Nguyen GC. The evolving evidence for therapeutic drug monitoring of monoclonal antibodies in inflammatory bowel disease. *Curr Gastroenterol Rep*. 2017;19:19.
42. Mantzaris GJ, Petraki K, Archavlis E, et al. A prospective randomized controlled trial of intravenous ciprofloxacin as an adjunct to corticosteroids in acute, severe ulcerative colitis. *Scand J Gastroenterol*. 2001;36:971–974.



43. Whaley KG, Rosen MJ. Contemporary medical management of acute severe ulcerative colitis. *Inflamm Bowel Dis*. 2019;25:56–66.
44. D'Haens G, Sandborn WJ, Feagan BG, et al. A review of activity indices and efficacy end points for clinical trials of medical therapy in adults with ulcerative colitis. *Gastroenterology*. 2007;132:763–786.
45. Järnerot G, Hertervig E, Friis-Liby I, et al. Infliximab as rescue therapy in severe to moderately severe ulcerative colitis: a randomized, placebo-controlled study. *Gastroenterology*. 2005;128:1805–1811.
46. D'Haens GR, Panaccione R, Higgins PD, et al. The London Position Statement of the World Congress of Gastroenterology on Biological Therapy for IBD with the European Crohn's and Colitis Organization: when to start, when to stop, which drug to choose, and how to predict response? *Am J Gastroenterol*. 2011;106:199–213.
47. Gibson DJ, Heetun ZS, Redmond CE, et al. An accelerated infliximab induction regimen reduces the need for early colectomy in patients with acute severe ulcerative colitis. *Clin Gastroenterol Hepatol*. 2015;13:330–335.e1.
48. Sjöberg M, Magnuson A, Björk J, et al; Swedish Organization for the Study of Inflammatory Bowel Disease (SOIBD). Infliximab as rescue therapy in hospitalised patients with steroid-refractory acute ulcerative colitis: a long-term follow-up of 211 Swedish patients. *Aliment Pharmacol Ther*. 2013;38:377–387.
49. Hyman NH, Cataldo P, Osler T. Urgent subtotal colectomy for severe inflammatory bowel disease. *Dis Colon Rectum*. 2005;48:70–73.
50. Allen BC, Leyendecker JR. MR enterography for assessment and management of small bowel Crohn disease. *Radiol Clin North Am*. 2014;52:799–810.
51. Rieder F, Latella G, Magro F, et al. European Crohn's and Colitis Organisation topical review on prediction, diagnosis and management of fibrostenosing Crohn's disease. *J Crohns Colitis*. 2016;10:873–885.
52. Allocca M, Fiorino G, Bonifacio C, Peyrin-Biroulet L, Danese S. Noninvasive multimodal methods to differentiate inflamed vs fibrotic strictures in patients with Crohn's disease. *Clin Gastroenterol Hepatol*. 2019;17:2397–2415.
53. Bettenworth D, Bokemeyer A, Baker M, et al; Stenosis Therapy and Anti-Fibrotic Research (STAR) Consortium. Assessment of Crohn's disease-associated small bowel strictures and fibrosis on cross-sectional imaging: a systematic review. *Gut*. 2019;68:1115–1126.
54. Rieder F, Bettenworth D, Ma C, et al. An expert consensus to standardise definitions, diagnosis and treatment targets for anti-fibrotic stricture therapies in Crohn's disease. *Aliment Pharmacol Ther*. 2018;48:347–357.
55. Qiu Y, Mao R, Chen BL, et al. Systematic review with meta-analysis: magnetic resonance enterography vs. computed tomography enterography for evaluating disease activity in small bowel Crohn's disease. *Aliment Pharmacol Ther*. 2014;40:134–146.
56. Spektor M, Mathur M, Santacana G, et al. Does MR enterography offer added value after a recent CT in the evaluation of abdominal pain in Crohn's disease patients? *Clin Imaging*. 2019;54:78–83.
57. Bouhnik Y, Carbonnel F, Laharie D, et al; GETAID CREOLE Study Group. Efficacy of adalimumab in patients with Crohn's disease and symptomatic small bowel stricture: a multicentre, prospective, observational cohort (CREOLE) study. *Gut*. 2018;67:53–60.
58. Navaneethan U, Lourdasamy V, Njei B, Shen B. Endoscopic balloon dilation in the management of strictures in Crohn's disease: a systematic review and meta-analysis of non-randomized trials. *Surg Endosc*. 2016;30:5434–5443.
59. Shivashankar R, Edakkanambeth Varayil J, Scott Harmsen W, et al. Outcomes of endoscopic therapy for luminal strictures in Crohn's disease. *Inflamm Bowel Dis*. 2018;24:1575–1581.
60. Wibmer AG, Kroesen AJ, Gröne J, Buhr HJ, Ritz JP. Comparison of strictureplasty and endoscopic balloon dilatation for stricturing Crohn's disease—review of the literature. *Int J Colorectal Dis*. 2010;25:1149–1157.
61. Bettenworth D, Mücke MM, Lopez R, et al. Efficacy of endoscopic dilation of gastroduodenal Crohn's disease strictures: a systematic review and meta-analysis of individual patient data. *Clin Gastroenterol Hepatol*. 2019;17:2514–2522.e8.
62. Lopes S, Rodrigues-Pinto E, Andrade P, et al. Endoscopic balloon dilation of Crohn's disease strictures—safety, efficacy and clinical impact. *World J Gastroenterol*. 2017;23:7397–7406.
63. Atreja A, Aggarwal A, Dwivedi S, et al. Safety and efficacy of endoscopic dilation for primary and anastomotic Crohn's disease strictures. *J Crohns Colitis*. 2014;8:392–400.
64. East JE, Brooker JC, Rutter MD, Saunders BP. A pilot study of intrastricture steroid versus placebo injection after balloon dilatation of Crohn's strictures. *Clin Gastroenterol Hepatol*. 2007;5:1065–1069.
65. Ambe R, Campbell L, Cagir B. A comprehensive review of strictureplasty techniques in Crohn's disease: types, indications, comparisons, and safety. *J Gastrointest Surg*. 2012;16:209–217.
66. Aaltonen G, Ristimäki A, Keränen I, Carpelan-Holmström M, Lepistö A. Does a histologically inflamed resection margin increase postoperative complications in patients with Crohn's disease? *Scand J Gastroenterol*. 2018;53:279–283.
67. Fazio VW, Marchetti F, Church M, et al. Effect of resection margins on the recurrence of Crohn's disease in the small bowel. A randomized controlled trial. *Ann Surg*. 1996;224:563–571.
68. Setoodeh S, Liu L, Boukhar SA, et al. The clinical significance of Crohn disease activity at resection margins. *Arch Pathol Lab Med*. 2019;143:505–509.
69. Coffey CJ, Kiernan MG, Sahebally SM, et al. Inclusion of the mesentery in ileocolic resection for Crohn's disease is associated with reduced surgical recurrence. *J Crohns Colitis*. 2018;12:1139–1150.
70. Choy PY, Bissett IP, Docherty JG, Parry BR, Merrie A, Fitzgerald A. Stapled versus handsewn methods for ileocolic anastomoses. *Cochrane Database Syst Rev*. 2011;CD004320.
71. Huang W, Tang Y, Nong L, Sun Y. Risk factors for postoperative intra-abdominal septic complications after surgery in Crohn's disease: a meta-analysis of observational studies. *J Crohns Colitis*. 2015;9:293–301.
72. McLeod RS, Wolff BG, Ross S, Parkes R, McKenzie M; Investigators of the CAST Trial. Recurrence of Crohn's disease after ileocolic resection is not affected by anastomotic type: results of a multicenter, randomized, controlled trial. *Dis Colon Rectum*. 2009;52:919–927.
73. Gionchetti P, Dignass A, Danese S, et al; ECCO. 3rd European evidence-based consensus on the diagnosis and management of

- Crohn's disease 2016: Part 2: surgical management and special situations. *J Crohns Colitis*. 2017;11:135–149.
74. Roy P, Kumar D. Strictureplasty. *Br J Surg*. 2004;91:1428–1437.
  75. Rieder F, Zimmermann EM, Remzi FH, Sandborn WJ. Crohn's disease complicated by strictures: a systematic review. *Gut*. 2013;62:1072–1084.
  76. Bellolio F, Cohen Z, MacRae HM, et al. Strictureplasty in selected Crohn's disease patients results in acceptable long-term outcome. *Dis Colon Rectum*. 2012;55:864–869.
  77. Geltzeiler CB, Young JI, Diggs BS, et al. Strictureplasty for treatment of Crohn's disease: an ACS-NSQIP database analysis. *J Gastrointest Surg*. 2015;19:905–910.
  78. Campbell L, Ambe R, Weaver J, Marcus SM, Cagir B. Comparison of conventional and nonconventional strictureplasties in Crohn's disease: a systematic review and meta-analysis. *Dis Colon Rectum*. 2012;55:714–726.
  79. Michelassi F. Side-to-side isoperistaltic strictureplasty for multiple Crohn's strictures. *Dis Colon Rectum*. 1996;39:345–349.
  80. de Buck van Overstraeten A, Wolthuis AM, D'Hoore A. Modified side-to-side isoperistaltic strictureplasty over the ileocaecal valve for the surgical treatment of terminal ileal Crohn's disease: the ultimate bowel sparing technique? *Colorectal Dis*. 2016;18:O311–O313.
  81. Yamamoto T, Fazio VW, Tekkis PP. Safety and efficacy of strictureplasty for Crohn's disease: a systematic review and meta-analysis. *Dis Colon Rectum*. 2007;50:1968–1986.
  82. Dietz DW, Laureti S, Strong SA, et al. Safety and longterm efficacy of strictureplasty in 314 patients with obstructing small bowel Crohn's disease. *J Am Coll Surg*. 2001;192:330–337.
  83. Geltzeiler CB, Hart KD, Lu KC, Deveney KE, Herzig DO, Tsikitis VL. Trends in the surgical management of Crohn's disease. *J Gastrointest Surg*. 2015;19:1862–1868.
  84. Yamamoto T, Keighley MR. Factors affecting the incidence of postoperative septic complications and recurrence after strictureplasty for jejunoileal Crohn's disease. *Am J Surg*. 1999;178:240–245.
  85. Hesham W, Kann BR. Strictureplasty. *Clin Colon Rectal Surg*. 2013;26:80–83.
  86. Goldberg HI, Caruthers SB Jr, Nelson JA, Singleton JW. Radiographic findings of the National Cooperative Crohn's Disease Study. *Gastroenterology*. 1979;77(4 pt 2):925–937.
  87. Sonnenberg A, Genta RM. Epithelial dysplasia and cancer in IBD strictures. *J Crohns Colitis*. 2015;9:769–775.
  88. Yamazaki Y, Ribeiro MB, Sachar DB, Aufses AH Jr, Greenstein AJ. Malignant colorectal strictures in Crohn's disease. *Am J Gastroenterol*. 1991;86:882–885.
  89. Fumery M, Pineton de Chambrun G, et al. Detection of dysplasia or cancer in 3.5% of patients with inflammatory bowel disease and colonic strictures. *Clin Gastroenterol Hepatol*. 2015;13:1770–1775.
  90. Kontzoglou K, Moulakakis KG, Alexiou D, et al. The role of liquid-based cytology in the investigation of colorectal lesions: a cytohistopathological correlation and evaluation of diagnostic accuracy. *Langenbecks Arch Surg*. 2007;392:189–195.
  91. Broering DC, Eisenberger CE, Koch A, et al. Strictureplasty for large bowel stenosis in Crohn's disease: quality of life after surgical therapy. *Int J Colorectal Dis*. 2001;16:81–87.
  92. Doh YS, Kim YS, Bae SI, et al. The clinical characteristics of patients with free perforation in Korean Crohn's disease: results from the CONNECT study. *BMC Gastroenterol*. 2015;15:31.
  93. Greenstein AJ, Sachar DB, Mann D, Lachman P, Heimann T, Aufses AH Jr. Spontaneous free perforation and perforated abscess in 30 patients with Crohn's disease. *Ann Surg*. 1987;205:72–76.
  94. Ikeuchi H, Yamamura T. Free perforation in Crohn's disease: review of the Japanese literature. *J Gastroenterol*. 2002;37:1020–1027.
  95. Katz S, Schulman N, Levin L. Free perforation in Crohn's disease: a report of 33 cases and review of literature. *Am J Gastroenterol*. 1986;81:38–43.
  96. Kim JW, Lee HS, Ye BD, et al. Incidence of and risk factors for free bowel perforation in patients with Crohn's disease. *Dig Dis Sci*. 2017;62:1607–1614.
  97. Werbin N, Haddad R, Greenberg R, Karin E, Skornick Y. Free perforation in Crohn's disease. *Isr Med Assoc J*. 2003;5:175–177.
  98. Veroux M, Angriman I, Ruffolo C, et al. A rare surgical complication of Crohn's diseases: free peritoneal perforation. *Mi-nerva Chir*. 2003;58:351–354.
  99. Feagins LA, Holubar SD, Kane SV, Spechler SJ. Current strategies in the management of intra-abdominal abscesses in Crohn's disease. *Clin Gastroenterol Hepatol*. 2011;9:842–850.
  100. Casola G, vanSonnenberg E, Neff CC, Saba RM, Withers C, Emarine CW. Abscesses in Crohn disease: percutaneous drainage. *Radiology*. 1987;163:19–22.
  101. Gervais DA, Hahn PF, O'Neill MJ, Mueller PR. Percutaneous abscess drainage in Crohn disease: technical success and short- and long-term outcomes during 14 years. *Radiology*. 2002;222:645–651.
  102. Golfieri R, Cappelli A, Giampalma E, et al. CT-guided percutaneous pelvic abscess drainage in Crohn's disease. *Tech Colo-proctol*. 2006;10:99–105.
  103. Jawhari A, Kamm MA, Ong C, Forbes A, Bartram CI, Hawley PR. Intra-abdominal and pelvic abscess in Crohn's disease: results of noninvasive and surgical management. *Br J Surg*. 1998;85:367–371.
  104. Lambiase RE, Cronan JJ, Dorfman GS, Paolella LP, Haas RA. Percutaneous drainage of abscesses in patients with Crohn disease. *AJR Am J Roentgenol*. 1988;150:1043–1045.
  105. Sahai A, Bélair M, Gianfelice D, Coté S, Gratton J, Lahaie R. Percutaneous drainage of intra-abdominal abscesses in Crohn's disease: short and long-term outcome. *Am J Gastroenterol*. 1997;92:275–278.
  106. Bermejo F, Garrido E, Chaparro M, et al. Efficacy of different therapeutic options for spontaneous abdominal abscesses in Crohn's disease: are antibiotics enough? *Inflamm Bowel Dis*. 2012;18:1509–1514.
  107. da Luz Moreira A, Stocchi L, Tan E, Tekkis PP, Fazio VW. Outcomes of Crohn's disease presenting with abdominopelvic abscesses. *Dis Colon Rectum*. 2009;52:906–912.
  108. Gutierrez A, Lee H, Sands BE. Outcome of surgical versus percutaneous drainage of abdominal and pelvic abscesses in Crohn's disease. *Am J Gastroenterol*. 2006;101:2283–2289.
  109. He X, Lin X, Lian L, et al. Preoperative percutaneous drainage of spontaneous intra-abdominal abscess in patients with Crohn's disease: a meta-analysis. *J Clin Gastroenterol*. 2015;49:e82–e90.
  110. Lobatón T, Guardiola J, Rodríguez-Moranta F, et al. Comparison of the long-term outcome of two therapeutic strategies for the management of abdominal abscess complicating Crohn's disease: percutaneous drainage or immediate surgical treatment. *Colorectal Dis*. 2013;15:1267–1272.

111. Clancy C, Boland T, Deasy J, McNamara D, Burke JP. A meta-analysis of percutaneous drainage versus surgery as the initial treatment of Crohn's disease-related intra-abdominal abscess. *J Crohns Colitis*. 2016;10:202–208.
112. Kumar RR, Kim JT, Haukoos JS, et al. Factors affecting the successful management of intra-abdominal abscesses with antibiotics and the need for percutaneous drainage. *Dis Colon Rectum*. 2006;49:183–189.
113. Lee H, Kim YH, Kim JH, et al. Nonsurgical treatment of abdominal or pelvic abscess in consecutive patients with Crohn's disease. *Dig Liver Dis*. 2006;38:659–664.
114. de Groof EJ, Carbonnel F, Buskens CJ, Bemelman WA. Abdominal abscess in Crohn's disease: multidisciplinary management. *Dig Dis*. 2014;32(suppl 1):103–109.
115. García JC, Persky SE, Bonis PA, Topazian M. Abscesses in Crohn's disease: outcome of medical versus surgical treatment. *J Clin Gastroenterol*. 2001;32:409–412.
116. Levy C, Tremaine WJ. Management of internal fistulas in Crohn's disease. *Inflamm Bowel Dis*. 2002;8:106–111.
117. Nguyen DL, Sandborn WJ, Loftus EV Jr, et al. Similar outcomes of surgical and medical treatment of intra-abdominal abscesses in patients with Crohn's disease. *Clin Gastroenterol Hepatol*. 2012;10:400–404.
118. Ibáñez-Samaniego L, Díaz-Fontenla F, Miranda-Bautista José, et al. Safety and efficacy of anti-TNF $\alpha$  treatment in Crohn's disease patients with abdominal abscesses. *Hepato-gastroenterology*. 2015;62:647–652.
119. Maconi G, Sampietro GM, Parente F, et al. Contrast radiology, computed tomography and ultrasonography in detecting internal fistulas and intra-abdominal abscesses in Crohn's disease: a prospective comparative study. *Am J Gastroenterol*. 2003;98:1545–1555.
120. Poritz LS, Gagliano GA, McLeod RS, MacRae H, Cohen Z. Surgical management of entero and colocolic fistulae in Crohn's disease: 17 year's experience. *Int J Colorectal Dis*. 2004;19:481–486.
121. Kobayashi T, Hishida A, Tanaka H, et al. Real-world experience of anti-tumor necrosis factor therapy for internal fistulas in Crohn's disease: a retrospective multicenter cohort study. *Inflamm Bowel Dis*. 2017;23:2245–2251.
122. Best WR, Beckett JM, Singleton JW, Kern F Jr. Development of a Crohn's disease activity index. National Cooperative Crohn's Disease Study. *Gastroenterology*. 1976;70:439–444.
123. Kaimakliotis P, Simillis C, Harbord M, Kontovounisios C, Rasheed S, Tekkis PP. A systematic review assessing medical treatment for rectovaginal and enterovesical fistulae in Crohn's disease. *J Clin Gastroenterol*. 2016;50:714–721.
124. Taxonera C, Barreiro-de-Acosta M, Bastida G, et al. Outcomes of medical and surgical therapy for entero-urinary fistulas in Crohn's disease. *J Crohns Colitis*. 2016;10:657–662.
125. Melton GB, Stocchi L, Wick EC, Appau KA, Fazio VW. Contemporary surgical management for ileosigmoid fistulas in Crohn's disease. *J Gastrointest Surg*. 2009;13:839–845.
126. Saint-Marc O, Vaillant JC, Frileux P, Balladur P, Tiret E, Parc R. Surgical management of ileosigmoid fistulas in Crohn's disease: role of preoperative colonoscopy. *Dis Colon Rectum*. 1995;38:1084–1087.
127. Young-Fadok TM, Wolff BG, Meagher A, Benn PL, Dozois RR. Surgical management of ileosigmoid fistulas in Crohn's disease. *Dis Colon Rectum*. 1997;40:558–561.
128. Gruner JS, Sehon JK, Johnson LW. Diagnosis and management of enterovesical fistulas in patients with Crohn's disease. *Am Surg*. 2002;68:714–719.
129. Yamamoto T, Keighley MR. Enterovesical fistulas complicating Crohn's disease: clinicopathological features and management. *Int J Colorectal Dis*. 2000;15:211–216.
130. Belaiche J, Louis E, D'Haens G, et al. Acute lower gastrointestinal bleeding in Crohn's disease: characteristics of a unique series of 34 patients. Belgian IBD Research Group. *Am J Gastroenterol*. 1999;94:2177–2181.
131. Cirocco WC, Reilly JC, Rusin LC. Life-threatening hemorrhage and exsanguination from Crohn's disease. Report of four cases. *Dis Colon Rectum*. 1995;38:85–95.
132. Driver CP, Anderson DN, Keenan RA. Massive intestinal bleeding in association with Crohn's disease. *J R Coll Surg Edinb*. 1996;41:152–154.
133. Kim KJ, Han BJ, Yang SK, et al. Risk factors and outcome of acute severe lower gastrointestinal bleeding in Crohn's disease. *Dig Liver Dis*. 2012;44:723–728.
134. Papi C, Gili L, Tarquini M, Antonelli G, Capurso L. Infliximab for severe recurrent Crohn's disease presenting with massive gastrointestinal hemorrhage. *J Clin Gastroenterol*. 2003;36:238–241.
135. Robert JR, Sachar DB, Greenstein AJ. Severe gastrointestinal hemorrhage in Crohn's disease. *Ann Surg*. 1991;213:207–211.
136. Daperno M, Sostegni R, Rocca R. Lower gastrointestinal bleeding in Crohn's disease: how (un-)common is it and how to tackle it? *Dig Liver Dis*. 2012;44:721–722.
137. García-Blázquez V, Vicente-Bártulos A, Olavarria-Delgado A, Plana MN, van der Winden D, Zamora J; EBM-Connect Collaboration. Accuracy of CT angiography in the diagnosis of acute gastrointestinal bleeding: systematic review and meta-analysis. *Eur Radiol*. 2013;23:1181–1190.
138. Wu LM, Xu JR, Yin Y, Qu XH. Usefulness of CT angiography in diagnosing acute gastrointestinal bleeding: a meta-analysis. *World J Gastroenterol*. 2010;16:3957–3963.
139. Podugu A, Tandon K, Castro FJ. Crohn's disease presenting as acute gastrointestinal hemorrhage. *World J Gastroenterol*. 2016;22:4073–4078.
140. Raphaeli T, Menon R. Current treatment of lower gastrointestinal hemorrhage. *Clin Colon Rectal Surg*. 2012;25:219–227.
141. Farraye FA, Odze RD, Eaden J, Itzkowitz SH. AGA technical review on the diagnosis and management of colorectal neoplasia in inflammatory bowel disease. *Gastroenterology*. 2010;138:746–774, 774.e1.
142. Samadder NJ, Valentine JF, Guthery S, et al. Family history associates with increased risk of colorectal cancer in patients with inflammatory bowel diseases. *Clin Gastroenterol Hepatol*. 2019;17:1807–1813.e1.
143. Asklng J, Dickman PW, Karlén P, et al. Colorectal cancer rates among first-degree relatives of patients with inflammatory bowel disease: a population-based cohort study. *Lancet*. 2001;357:262–266.
144. Itzkowitz SH, Harpaz N. Diagnosis and management of dysplasia in patients with inflammatory bowel diseases. *Gastroenterology*. 2004;126:1634–1648.
145. Jess T, Simonsen J, Jørgensen KT, Pedersen BV, Nielsen NM, Frisch M. Decreasing risk of colorectal cancer in patients with inflammatory bowel disease over 30 years. *Gastroenterology*. 2012;143:375–381.e1.

146. Shah SC, Ten Hove JR, Castaneda D, et al. High risk of advanced colorectal neoplasia in patients with primary sclerosing cholangitis associated with inflammatory bowel disease. *Clin Gastroenterol Hepatol*. 2018;16:1106–1113.e3.
147. Kiran RP, Khoury W, Church JM, Lavery IC, Fazio VW, Remzi FH. Colorectal cancer complicating inflammatory bowel disease: similarities and differences between Crohn's and ulcerative colitis based on three decades of experience. *Ann Surg*. 2010;252:330–335.
148. Cremer A, Demetter P, De Vos M, et al; Belgian Inflammatory Bowel Disease Research and Development (BIRD) Group. Risk of development of more-advanced lesions in patients with inflammatory bowel diseases and dysplasia. *Clin Gastroenterol Hepatol*. 2019;S1542-3565(19)30645-7.
149. Eluri S, Parian AM, Limketkai BN, et al. Nearly a third of high-grade dysplasia and colorectal cancer is undetected in patients with inflammatory bowel disease. *Dig Dis Sci*. 2017;62:3586–3593.
150. Friedman S, Rubin PH, Bodian C, Harpaz N, Present DH. Screening and surveillance colonoscopy in chronic Crohn's colitis: results of a surveillance program spanning 25 years. *Clin Gastroenterol Hepatol*. 2008;6:993–998.
151. American Society for Gastrointestinal Endoscopy Standards of Practice Committee; Shergill AK, Lightdale JR, Bruining DH, et al. The role of endoscopy in inflammatory bowel disease. *Gastrointest Endosc* 2015;81:1101-21 e1-13.
152. Annese V, Daperno M, Rutter MD, et al; European Crohn's and Colitis Organisation. European evidence based consensus for endoscopy in inflammatory bowel disease. *J Crohns Colitis*. 2013;7:982–1018.
153. Cairns SR, Scholefield JH, Steele RJ, et al; British Society of Gastroenterology; Association of Coloproctology for Great Britain and Ireland. Guidelines for colorectal cancer screening and surveillance in moderate and high risk groups (update from 2002). *Gut*. 2010;59:666–689.
154. Laine L, Kaltenbach T, Barkun A, McQuaid KR, Subramanian V, Soetikno R; SCENIC Guideline Development Panel. SCENIC international consensus statement on surveillance and management of dysplasia in inflammatory bowel disease. *Gastrointest Endosc*. 2015;81:489–501.e26.
155. Clarke WT, Feuerstein JD. Colorectal cancer surveillance in inflammatory bowel disease: practice guidelines and recent developments. *World J Gastroenterol*. 2019;25:4148–4157.
156. Magro F, Gionchetti P, Eliakim R, et al; European Crohn's and Colitis Organisation [ECCO]. Third European evidence-based consensus on diagnosis and management of ulcerative colitis. Part 1: definitions, diagnosis, extra-intestinal manifestations, pregnancy, cancer surveillance, surgery, and ileo-anal pouch disorders. *J Crohns Colitis*. 2017;11:649–670.
157. Shergill AK, Lightdale JR, Bruining DH, et al; American Society for Gastrointestinal Endoscopy Standards of Practice Committee. The role of endoscopy in inflammatory bowel disease. *Gastrointest Endosc*. 2015;81:1101–1121.
158. Rubin DT, Ananthakrishnan AN, Siegel CA, Sauer BG, Long MD. ACG Clinical Guideline: ulcerative colitis in adults. *Am J Gastroenterol*. 2019;114:384–413.
159. Baars JE, Vogelaar L, Wolfhagen FH, Biermann K, Kuipers EJ, van der Woude CJ. A short course of corticosteroids prior to surveillance colonoscopy to decrease mucosal inflammation in inflammatory bowel disease patients: results from a randomized controlled trial. *J Crohns Colitis*. 2010;4:661–668.
160. Chiu K, Riddell RH, Schaeffer DF. DALM, rest in peace: a pathologist's perspective on dysplasia in inflammatory bowel disease in the post-DALM era. *Mod Pathol*. 2018;31:1180–1190.
161. Odze RD, Goldblum J, Noffsinger A, Alsaigh N, Rybicki LA, Fogt F. Interobserver variability in the diagnosis of ulcerative colitis-associated dysplasia by telepathology. *Mod Pathol*. 2002;15:379–386.
162. Wanders LK, Mooiweer E, Wang J, et al. Low interobserver agreement among endoscopists in differentiating dysplastic from non-dysplastic lesions during inflammatory bowel disease colitis surveillance. *Scand J Gastroenterol*. 2015;50:1011–1017.
163. Itzkowitz SH, Present DH; Crohn's and Colitis Foundation of America Colon Cancer in IBD Study Group. Consensus conference: colorectal cancer screening and surveillance in inflammatory bowel disease. *Inflamm Bowel Dis*. 2005;11:314–321.
164. Goldstone R, Itzkowitz S, Harpaz N, Ullman T. Progression of low-grade dysplasia in ulcerative colitis: effect of colonic location. *Gastrointest Endosc*. 2011;74:1087–1093.
165. Navaneethan U, Jegadeesan R, Gutierrez NG, et al. Progression of low-grade dysplasia to advanced neoplasia based on the location and morphology of dysplasia in ulcerative colitis patients with extensive colitis under colonoscopic surveillance. *J Crohns Colitis*. 2013;7:e684–e691.
166. Rubin PH, Friedman S, Harpaz N, et al. Colonoscopic polypectomy in chronic colitis: conservative management after endoscopic resection of dysplastic polyps. *Gastroenterology*. 1999;117:1295–1300.
167. Gulati S, Emmanuel A, Burt M, Dubois P, Hayee B, Haji A. Outcomes of endoscopic resections of large laterally spreading colorectal lesions in inflammatory bowel disease: a single United Kingdom center experience. *Inflamm Bowel Dis*. 2018;24:1196–1203.
168. Kinoshita S, Uraoka T, Nishizawa T, et al. The role of colorectal endoscopic submucosal dissection in patients with ulcerative colitis. *Gastrointest Endosc*. 2018;87:1079–1084.
169. Kochhar G, Steele S, Sanaka M, Gorgun E. Endoscopic submucosal dissection for flat colonic polyps in patients with inflammatory bowel disease, a single-center experience. *Inflamm Bowel Dis*. 2018;24:e14–e15.
170. Shergill AK, Farraye FA. Toward a consensus on endoscopic surveillance of patients with colonic inflammatory bowel disease. *Gastrointest Endosc Clin N Am*. 2014;24:469–481.
171. Kisiel JB, Loftus EV Jr, Harmsen WS, Zinsmeister AR, Sandborn WJ. Outcome of sporadic adenomas and adenoma-like dysplasia in patients with ulcerative colitis undergoing polypectomy. *Inflamm Bowel Dis*. 2012;18:226–235.
172. Odze RD, Farraye FA, Hecht JL, Hornick JL. Long-term follow-up after polypectomy treatment for adenoma-like dysplastic lesions in ulcerative colitis. *Clin Gastroenterol Hepatol*. 2004;2:534–541.
173. Rutter MD, Saunders BP, Wilkinson KH, Kamm MA, Williams CB, Forbes A. Most dysplasia in ulcerative colitis is visible at colonoscopy. *Gastrointest Endosc*. 2004;60:334–339.
174. van Schaik FD, Mooiweer E, van der Have M, et al; Dutch Initiative on Crohn Colitis. Adenomas in patients with inflammatory bowel disease are associated with an increased risk of advanced neoplasia. *Inflamm Bowel Dis*. 2013;19:342–349.

175. Wanders LK, Dekker E, Pullens B, Bassett P, Travis SP, East JE. Cancer risk after resection of polypoid dysplasia in patients with longstanding ulcerative colitis: a meta-analysis. *Clin Gastroenterol Hepatol*. 2014;12:756–764.
176. Kiran RP, Nisar PJ, Goldblum JR, et al. Dysplasia associated with Crohn's colitis: segmental colectomy or more extended resection? *Ann Surg*. 2012;256:221–226.
177. Maser EA, Sachar DB, Kruse D, Harpaz N, Ullman T, Bauer JJ. High rates of metachronous colon cancer or dysplasia after segmental resection or subtotal colectomy in Crohn's colitis. *Inflamm Bowel Dis*. 2013;19:1827–1832.
178. Derikx LAAP, Nissen LHC, Smits LJT, Shen B, Hoentjen F. Risk of neoplasia after colectomy in patients with inflammatory bowel disease: a systematic review and meta-analysis. *Clin Gastroenterol Hepatol*. 2016;14:798–806.e20.
179. Choi WT, Rabinovitch PS, Wang D, Westerhoff M. Outcome of “indefinite for dysplasia” in inflammatory bowel disease: correlation with DNA flow cytometry and other risk factors of colorectal cancer. *Hum Pathol*. 2015;46:939–947.
180. Deepak P, Hanson GJ, Fletcher JG, et al. Incremental diagnostic yield of chromoendoscopy and outcomes in inflammatory bowel disease patients with a history of colorectal dysplasia on white-light endoscopy. *Gastrointest Endosc*. 2016;83:1005–1012.
181. Zisman TL, Bronner MP, Rulyak S, et al. Prospective study of the progression of low-grade dysplasia in ulcerative colitis using current cancer surveillance guidelines. *Inflamm Bowel Dis*. 2012;18:2240–2246.
182. Fumery M, Dulai PS, Gupta S, et al. Incidence, risk factors, and outcomes of colorectal cancer in patients with ulcerative colitis with low-grade dysplasia: a systematic review and meta-analysis. *Clin Gastroenterol Hepatol*. 2017;15:665–674.e5.
183. Murphy J, Kalkbrenner KA, Pemberton JH, et al. Dysplasia in ulcerative colitis as a predictor of unsuspected synchronous colorectal cancer. *Dis Colon Rectum*. 2014;57:993–998.
184. Ullman T, Croog V, Harpaz N, Sachar D, Itzkowitz S. Progression of flat low-grade dysplasia to advanced neoplasia in patients with ulcerative colitis. *Gastroenterology*. 2003;125:1311–1319.
185. Parker B, Buchanan J, Wordsworth S, Keshav S, George B, East JE. Surgery versus surveillance in ulcerative colitis patients with endoscopically invisible low-grade dysplasia: a cost-effectiveness analysis. *Gastrointest Endosc*. 2017;86:1088–1099.e5.
186. Laukoetter MG, Mennigen R, Hannig CM, et al. Intestinal cancer risk in Crohn's disease: a meta-analysis. *J Gastrointest Surg*. 2011;15:576–583.
187. Jaskowiak NT, Michelassi F. Adenocarcinoma at a strictureplasty site in Crohn's disease: report of a case. *Dis Colon Rectum*. 2001;44:284–287.
188. Marchetti F, Fazio VW, Ozuner G. Adenocarcinoma arising from a strictureplasty site in Crohn's disease. Report of a case. *Dis Colon Rectum*. 1996;39:1315–1321.
189. Partridge SK, Hodin RA. Small bowel adenocarcinoma at a strictureplasty site in a patient with Crohn's disease: report of a case. *Dis Colon Rectum*. 2004;47:778–781.
190. Tonelli F, Bargellini T, Leo F, Nesi G. Duodenal adenocarcinoma arising at the strictureplasty site in a patient with Crohn's disease: report of a case. *Int J Colorectal Dis*. 2009;24:475–477.
191. Schwartzberg DM, Brandstetter S, Grucela AL. Crohn's disease of the esophagus, duodenum, and stomach. *Clin Colon Rectal Surg*. 2019;32:231–242.
192. Kelly SM, Hunter JO. Endoscopic balloon dilatation of duodenal strictures in Crohn's disease. *Postgrad Med J*. 1995;71:623–624.
193. Mege D, Panis Y. Unmet therapeutic needs: focus on intestinal fibrosis surgical approach: resection, strictureplasty and others. *Dig Dis*. 2017;35:38–44.
194. Mottet C, Vader JP, Felley C, et al; EPACT II Study Group. Appropriate management of special situations in Crohn's disease (upper gastro-intestinal; extra-intestinal manifestations; drug safety during pregnancy and breastfeeding): Results of a multidisciplinary international expert panel-EPACT II. *J Crohns Colitis*. 2009;3:257–263.
195. Reese GE, Purkayastha S, Tilney HS, von Roon A, Yamamoto T, Tekkis PP. Strictureplasty vs resection in small bowel Crohn's disease: an evaluation of short-term outcomes and recurrence. *Colorectal Dis*. 2007;9:686–694.
196. Shapiro M, Greenstein AJ, Byrn J, et al. Surgical management and outcomes of patients with duodenal Crohn's disease. *J Am Coll Surg*. 2008;207:36–42.
197. Takesue Y, Yokoyama T, Akagi S, et al. Strictureplasty for short duodenal stenosis in Crohn's disease. *J Gastroenterol*. 2000;35:929–932.
198. Tonelli F, Alemanno G, Bellucci F, Focardi A, Sturiale A, Giudici F. Symptomatic duodenal Crohn's disease: is strictureplasty the right choice? *J Crohns Colitis*. 2013;7:791–796.
199. Worsley MJ, Hull T, Ryland L, Fazio V. Strictureplasty is an effective option in the operative management of duodenal Crohn's disease. *Dis Colon Rectum*. 1999;42:596–600.
200. Yamamoto T, Bain IM, Connolly AB, Allan RN, Keighley MR. Outcome of strictureplasty for duodenal Crohn's disease. *Br J Surg*. 1999;86:259–262.
201. Lightner AL. Duodenal Crohn's disease. *Inflamm Bowel Dis*. 2018;24:546–551.
202. Peyrin-Biroulet L, Loftus EV Jr, Colombel JF, Sandborn WJ. The natural history of adult Crohn's disease in population-based cohorts. *Am J Gastroenterol*. 2010;105:289–297.
203. de Groof EJ, Stevens TW, Eshuis EJ, et al; LIR!C study group. Cost-effectiveness of laparoscopic ileocaecal resection versus infliximab treatment of terminal ileitis in Crohn's disease: the LIR!C Trial. *Gut*. 2019;68:1774–1780.
204. de Buck van Overstraeten A, Vermeire S, Vanbeckevoort D, et al. Modified side-to-side isoperistaltic strictureplasty over the ileocaecal valve: an alternative to ileocaecal resection in extensive terminal ileal Crohn's disease. *J Crohns Colitis*. 2016;10:437–442.
205. Teeuwen PH, Stommel MW, Bremers AJ, van der Wilt GJ, de Jong DJ, Bleichrodt RP. Colectomy in patients with acute colitis: a systematic review. *J Gastrointest Surg*. 2009;13:676–686.
206. Carter FM, McLeod RS, Cohen Z. Subtotal colectomy for ulcerative colitis: complications related to the rectal remnant. *Dis Colon Rectum*. 1991;34:1005–1009.
207. McKee RF, Keenan RA, Munro A. Colectomy for acute colitis: is it safe to close the rectal stump? *Int J Colorectal Dis*. 1995;10:222–224.
208. Ng RL, Davies AH, Grace RH, Mortensen NJ. Subcutaneous rectal stump closure after emergency subtotal colectomy. *Br J Surg*. 1992;79:701–703.

209. Trickett JP, Tilney HS, Gudgeon AM, Mellor SG, Edwards DP. Management of the rectal stump after emergency sub-total colectomy: which surgical option is associated with the lowest morbidity? *Colorectal Dis.* 2005;7:519–522.
210. Karch LA, Bauer JJ, Gorfine SR, Gelernt IM. Subtotal colectomy with Hartmann's pouch for inflammatory bowel disease. *Dis Colon Rectum.* 1995;38:635–639.
211. Angriman I, Pirozzolo G, Bardini R, Cavallin F, Castoro C, Scarpa M. A systematic review of segmental vs subtotal colectomy and subtotal colectomy vs total proctocolectomy for colonic Crohn's disease. *Colorectal Dis.* 2017;19:e279–e287.
212. Tekkis PP, Purkayastha S, Lanitis S, et al. A comparison of segmental vs subtotal/total colectomy for colonic Crohn's disease: a meta-analysis. *Colorectal Dis.* 2006;8:82–90.
213. de Buck van Overstraeten A, Wolthuis AM, Vermeire S, et al. Intersphincteric proctectomy with end-colostomy for anorectal Crohn's disease results in early and severe proximal colonic recurrence. *J Crohns Colitis.* 2013;7:e227–e231.
214. D'Hoore A. Persistent mesorectal inflammatory activity is associated with complications after proctectomy in Crohn's disease: immediate surgical implications! *J Crohn's Colitis.* 2019;13:271–272.
215. de Groof EJ, van der Meer JHM, Tanis PJ, et al. Persistent mesorectal inflammatory activity is associated with complications after proctectomy in Crohn's disease. *J Crohns Colitis.* 2019;13:285–293.
216. Zeitels JR, Fiddian-Green RG, Dent TL. Intersphincteric proctectomy. *Surgery.* 1984;96:617–623.
217. Panis Y, Poupard B, Nemeth J, Lavergne A, Hautefeuille P, Valleur P. Ileal pouch/anal anastomosis for Crohn's disease. *Lancet.* 1996;347:854–857.
218. Brown CJ, Maclean AR, Cohen Z, Macrae HM, O'Connor BI, McLeod RS. Crohn's disease and indeterminate colitis and the ileal pouch-anal anastomosis: outcomes and patterns of failure. *Dis Colon Rectum.* 2005;48:1542–1549.
219. Grucela AL, Bauer JJ, Gorfine SR, Chessin DB. Outcome and long-term function of restorative proctocolectomy for Crohn's disease: comparison to patients with ulcerative colitis. *Colorectal Dis.* 2011;13:426–430.
220. Le Q, Melmed G, Dubinsky M, et al. Surgical outcome of ileal pouch-anal anastomosis when used intentionally for well-defined Crohn's disease. *Inflamm Bowel Dis.* 2013;19:30–36.
221. Mandel D, Zaghyan K, Fleshner P. Long-term surgical outcome of ileal pouch-anal anastomosis when used for well-defined Crohn's disease. *J Crohn's Colitis.* 2018;12(suppl 1):S332.
222. Regimbeau JM, Panis Y, Pocard M, et al. Long-term results of ileal pouch-anal anastomosis for colorectal Crohn's disease. *Dis Colon Rectum.* 2001;44:769–778.
223. Shen B, Patel S, Lian L. Natural history of Crohn's disease in patients who underwent intentional restorative proctocolectomy with ileal pouch-anal anastomosis. *Aliment Pharmacol Ther.* 2010;31:745–753.
224. Tekkis PP, Heriot AG, Smith O, Smith JJ, Windsor AC, Nicholls RJ. Long-term outcomes of restorative proctocolectomy for Crohn's disease and indeterminate colitis. *Colorectal Dis.* 2005;7:218–223.
225. Braveman JM, Schoetz DJ Jr, Marcello PW, et al. The fate of the ileal pouch in patients developing Crohn's disease. *Dis Colon Rectum.* 2004;47:1613–1619.
226. Melton GB, Fazio VW, Kiran RP, et al. Long-term outcomes with ileal pouch-anal anastomosis and Crohn's disease: pouch retention and implications of delayed diagnosis. *Ann Surg.* 2008;248:608–616.
227. Fazio VW, Kiran RP, Remzi FH, et al. Ileal pouch anal anastomosis: analysis of outcome and quality of life in 3707 patients. *Ann Surg.* 2013;257:679–685.
228. Bemelman WA, Warusavitarne J, Sampietro GM, et al. ECCO-ESCP consensus on surgery for Crohn's disease. *J Crohns Colitis.* 2018;12:1–16.
229. Lightner AL, McKenna NP, Tse CS, Raffals LE, Loftus EV Jr, Mathis KL. Postoperative outcomes in vedolizumab-treated Crohn's disease patients undergoing major abdominal operations. *Aliment Pharmacol Ther.* 2018;47:573–580.
230. Aberra FN, Lewis JD, Hass D, Rombeau JL, Osborne B, Lichtenstein GR. Corticosteroids and immunomodulators: postoperative infectious complication risk in inflammatory bowel disease patients. *Gastroenterology.* 2003;125:320–327.
231. Subramanian V, Pollok RC, Kang JY, Kumar D. Systematic review of postoperative complications in patients with inflammatory bowel disease treated with immunomodulators. *Br J Surg.* 2006;93:793–799.
232. Ahmed Ali U, Martin ST, Rao AD, Kiran RP. Impact of preoperative immunosuppressive agents on postoperative outcomes in Crohn's disease. *Dis Colon Rectum.* 2014;57:663–674.
233. Brouquet A, Maggiori L, Zerbib P, et al; GETAID chirurgie group. Anti-TNF therapy is associated with an increased risk of postoperative morbidity after surgery for ileocolonic Crohn disease: results of a prospective nationwide cohort. *Ann Surg.* 2018;267:221–228.
234. Fumery M, Seksik P, Auzolle C, et al; REMIND study group investigators. Postoperative complications after ileocecal resection in Crohn's disease: a prospective study from the REMIND Group. *Am J Gastroenterol.* 2017;112:337–345.
235. Kotze PG, Ghosh S, Bemelman WA, Panaccione R. Preoperative use of anti-tumor necrosis factor therapy in Crohn's disease: promises and pitfalls. *Intest Res.* 2017;15:160–165.
236. Kotze PG, Magro DO, Martinez CAR, et al. Adalimumab and postoperative complications of elective intestinal resections in Crohn's disease: a propensity score case-matched study. *Colorectal Dis.* 2017;20:20.
237. Kotze PG, Saab MP, Saab B, et al. Tumor necrosis factor alpha inhibitors did not influence postoperative morbidity after elective surgical resections in Crohn's disease. *Dig Dis Sci.* 2017;62:456–464.
238. Kulaylat AS, Kulaylat AN, Schaefer EW, et al. Association of preoperative anti-tumor necrosis factor therapy with adverse postoperative outcomes in patients undergoing abdominal surgery for ulcerative colitis. *JAMA Surg.* 2017;152:e171538.
239. McKenna NP, Habermann EB, Glasgow AE, Dozois EJ, Lightner AL. Intra-abdominal sepsis after ileocolic resection in Crohn's disease: the role of combination immunosuppression. *Dis Colon Rectum.* 2018;61:1393–1402.
240. Saab M, Saab B, Olandoski M, Coy CSR, Kotze PG. Impact of anti-TNF agents in postoperative complications in Crohn's disease: a review. *J Coloproctol (Rio J).* 2015;35:128–136.
241. Yadav A, Kurada S, Foromera J, Falchuk KR, Feuerstein JD. Meta-analysis comparing the efficacy and adverse events of monoclonal antibodies and thiopurines for Crohn's disease after surgery for ulcerative colitis. *Dig Liver Dis.* 2018;30:30.

242. Law CCY, Narula A, Lightner AL, McKenna NP, Colombel JF, Narula N. Systematic review and meta-analysis: preoperative vedolizumab treatment and postoperative complications in patients with inflammatory bowel disease. *J Crohns Colitis*. 2018;12:538–545.
243. Lightner AL, Mathis KL, Tse CS, et al. Postoperative outcomes in vedolizumab-treated patients undergoing major abdominal operations for inflammatory bowel disease: retrospective multicenter cohort study. *Inflamm Bowel Dis*. 2018;24:871–876.
244. Yamada A, Komaki Y, Patel N, et al. Risk of postoperative complications among inflammatory bowel disease patients treated preoperatively with vedolizumab. *Am J Gastroenterol*. 2017;112:1423–1429.
245. Cohen BL FP, Kane SV, Herfarth HH, et al. Prospective cohort of ulcerative colitis and Crohn's disease patients undergoing surgery to identify risk factors for post-operative infection. Paper presented at: Digestive Disease Week; May 18–21, 2019; San Diego, CA.
246. Lin YS, Cheng SW, Wang YH, Chen KH, Fang CJ, Chen C. Systematic review with meta-analysis: risk of post-operative complications associated with pre-operative exposure to anti-tumour necrosis factor agents for Crohn's disease. *Aliment Pharmacol Ther*. 2019;49:966–977.
247. Lau C, Dubinsky M, Melmed G, et al. The impact of preoperative serum anti-TNF $\alpha$  therapy levels on early postoperative outcomes in inflammatory bowel disease surgery. *Ann Surg*. 2015;261:487–496.
248. Lightner AL, Raffals LE, Mathis KL, et al. Postoperative outcomes in vedolizumab-treated patients undergoing abdominal operations for inflammatory bowel disease. *J Crohns Colitis*. 2017;11:185–190.
249. Ferrante M, de Buck van Overstraeten A, Schils N, et al. Perioperative use of vedolizumab is not associated with postoperative infectious complications in patients with ulcerative colitis undergoing colectomy. *J Crohns Colitis*. 2017;11:1353–1361.
250. Yung DE, Horesh N, Lightner AL, et al. Systematic review and meta-analysis: vedolizumab and postoperative complications in inflammatory bowel disease. *Inflamm Bowel Dis*. 2018;24:2327–2338.
251. Lightner AL, McKenna NP, Tse CS, et al. Postoperative outcomes in ustekinumab-treated patients undergoing abdominal operations for Crohn's disease. *J Crohns Colitis*. 2018;12:402–407.
252. Novello M, Stocchi L, Holubar S, et al. Surgical outcomes of patients treated with ustekinumab vs. vedolizumab in inflammatory bowel disease: a matched case analysis. *Int J Colorectal Dis*. 2019;34:451–457.
253. Lightner AL, McKenna NP, Alsughayer A, et al. Biologics and 30-day postoperative complications after abdominal operations for Crohn's disease: are there differences in the safety profiles? *Dis Colon Rectum*. 2019;62:1352–1362.
254. Barnes EL, Lightner AL, Regueiro M. Peri-operative and post-operative management of patients with Crohn's disease and ulcerative colitis. *Clin Gastroenterol Hepatol*. 2019;S1542-3565(19)31091-2.
255. Forbes A, Escher J, Hébuterne X, et al. ESPEN guideline: clinical nutrition in inflammatory bowel disease. *Clin Nutr*. 2017;36:321–347.
256. Goh J, O'Morain CA. Review article: nutrition and adult inflammatory bowel disease. *Aliment Pharmacol Ther*. 2003;17:307–320.
257. Jacobson S. Early postoperative complications in patients with Crohn's disease given and not given preoperative total parenteral nutrition. *Scand J Gastroenterol*. 2012;47:170–177.
258. Grass F, Pache B, Martin D, Hahnloser D, Demartines N, Hübner M. Preoperative nutritional conditioning of Crohn's patients-systematic review of current evidence and practice. *Nutrients*. 2017;9:9.
259. Ge X, Tang S, Yang X, et al. The role of exclusive enteral nutrition in the preoperative optimization of laparoscopic surgery for patients with Crohn's disease: a cohort study. *Int J Surg*. 2019;65:39–44.
260. Wang H, Zuo L, Zhao J, et al. Impact of preoperative exclusive enteral nutrition on postoperative complications and recurrence after bowel resection in patients with active Crohn's disease. *World J Surg*. 2016;40:1993–2000.
261. Heerasing N, Thompson B, Hendy P, et al. Exclusive enteral nutrition provides an effective bridge to safer interval elective surgery for adults with Crohn's disease. *Aliment Pharmacol Ther*. 2017;45:660–669.
262. Li G, Ren J, Wang G, et al. Preoperative exclusive enteral nutrition reduces the postoperative septic complications of fistulizing Crohn's disease. *Eur J Clin Nutr*. 2014;68:441–446.
263. Li Y, Zuo L, Zhu W, et al. Role of exclusive enteral nutrition in the preoperative optimization of patients with Crohn's disease following immunosuppressive therapy. *Medicine (Baltimore)*. 2015;94:e478.
264. Parkes GC, Whelan K, Lindsay JO. Smoking in inflammatory bowel disease: impact on disease course and insights into the aetiology of its effect. *J Crohns Colitis*. 2014;8:717–725.
265. Kulaylat AN, Hollenbeak CS, Sangster W, Stewart DB Sr. Impact of smoking on the surgical outcome of Crohn's disease: a propensity-score matched National Surgical Quality Improvement Program analysis. *Colorectal Dis*. 2015;17:891–902.
266. Joyce MR, Hannaway CD, Strong SA, Fazio VW, Kiran RP. Impact of smoking on disease phenotype and postoperative outcomes for Crohn's disease patients undergoing surgery. *Langenbecks Arch Surg*. 2013;398:39–45.
267. Maartense S, Dunker MS, Slors JF, et al. Laparoscopic-assisted versus open ileocolic resection for Crohn's disease: a randomized trial. *Ann Surg*. 2006;243:143–150.
268. Milsom JW, Hammerhofer KA, Böhm B, Marcello P, Elson P, Fazio VW. Prospective, randomized trial comparing laparoscopic vs. conventional surgery for refractory ileocolic Crohn's disease. *Dis Colon Rectum*. 2001;44:1–8.
269. Stocchi L, Milsom JW, Fazio VW. Long-term outcomes of laparoscopic versus open ileocolic resection for Crohn's disease: follow-up of a prospective randomized trial. *Surgery*. 2008;144:622–627.
270. Aydinli HH, Aytac E, Grucela A, Bernstein M, Remzi FH. The adoption of laparoscopic colon resection for Crohn's disease: a study from NSQIP database. *Gastroenterology*. 2017;152(suppl 1):S1280–S1.
271. Aydinli HH, Aytac E, Remzi FH, Bernstein M, Grucela AL. Factors associated with short-term morbidity in patients undergoing colon resection for Crohn's disease. *J Gastrointest Surg*. 2018;22:1434–1441.
272. Skancke MD, Vaziri K, Graham AE, Amdur RL, Umaphathi BA, Obias VJ. Improved morbidity for emergent laparoscopic surgery in Crohn's disease: an analysis using the American College

- of Surgeons-NSQIP targeted colectomy database. *J Am Coll Surg*. 2017;225(suppl 2):e69.
273. Lee Y, Fleming FJ, Deeb AP, Gunzler D, Messing S, Monson JR. A laparoscopic approach reduces short-term complications and length of stay following ileocolic resection in Crohn's disease: an analysis of outcomes from the NSQIP database. *Colorectal Dis*. 2012;14:572–577.
  274. Aquina CT, Probst CP, Becerra AZ, et al. Missed opportunity: laparoscopic colorectal resection is associated with lower incidence of small bowel obstruction compared to an open approach. *Ann Surg*. 2016;264:127–134.
  275. Heimann TM, Swaminathan S, Greenstein AJ, et al. Can laparoscopic surgery prevent incisional hernia in patients with Crohn's disease: a comparison study of 750 patients undergoing open and laparoscopic bowel resection. *Surg Endosc*. 2017;31:5201–5208.
  276. Kristo I, Stift A, Argeny S, Mittlböck M, Riss S. Minimal-invasive approach for penetrating Crohn's disease is not associated with increased complications. *Surg Endosc*. 2016;30:5239–5244.
  277. Parés D, Shamali A, Flashman K, et al. Laparoscopic surgical treatment of ileocecal Crohn's disease: impact of obesity on short term results. *Cir Esp*. 2017;95:17–23.
  278. Raskin ER, Gorrepati ML, Mehendale S, Gaertner WB. Robotic-assisted ileocolic resection for Crohn's disease: outcomes from an early national experience. *J Robot Surg*. 2019;13:429–434.
  279. Moghadamyeghaneh Z, Hanna MH, Carmichael JC, Pigazzi A, Stamos MJ, Mills S. Comparison of open, laparoscopic, and robotic approaches for total abdominal colectomy. *Surg Endosc*. 2016;30:2792–2798.
  280. Leo CA, Samaranyake SF, Chandrasinghe PC, Shaikh IA, Hodgkinson JD, Warusavitarne JH. Single port laparoscopic surgery for complex Crohn's disease is safe with a lower conversion rate. *J Laparoendosc Adv Surg Tech A*. 2017;27:1095–1100.
  281. Maeda K, Nagahara H, Shibutani M, et al. The feasibility and short-term clinical outcomes of single-incision laparoscopic surgery for patients with complex Crohn's disease. *Surg Today*. 2018;48:242–247.
  282. Mizushima T, Nakajima K, Takeyama H, et al. Single-incision laparoscopic surgery for stricturing and penetrating Crohn's disease. *Surg Today*. 2016;46:203–208.
  283. Carvello M, de Groof EJ, de Buck van Overstraeten A, et al. Single port laparoscopic ileocaecal resection for Crohn's disease: a multicentre comparison with multi-port laparoscopy. *Colorectal Dis*. 2018;20:53–58.
  284. Zamboni D, Giudici F, Ficari F, Rogai F, Scaringi S. Short- and long-term outcome of minimally invasive approach for Crohn's disease: comparison between single incision, robotically assisted and conventional laparoscopy. *J Crohn's Colitis*. 2018;12(suppl 1):S411–S2.
  285. Maeda K, Noda E, Nagahara H, et al. A comparative study of single-incision versus conventional multiport laparoscopic ileocecal resection for Crohn's disease with strictures. *Asian J Endosc Surg*. 2012;5:118–122.
  286. Neary PM, Stocchi L, Shawki S, et al. High-risk elective ileocolic anastomoses for Crohn's disease: when is diversion indicated? *Dis Colon Rectum*. 2018;61:e54.
  287. Fish DR, Mancuso CA, Garcia-Aguilar JE, et al. Readmission after ileostomy creation: retrospective review of a common and significant event. *Ann Surg*. 2017;265:379–387.
  288. Johnston WF, Stafford C, Francone TD, et al. What is the risk of anastomotic leak after repeat intestinal resection in patients with Crohn's disease? *Dis Colon Rectum*. 2017;60:1299–1306.
  289. McKenna NP, Glasgow AE, Habermann EB, Lightner AL. Risk factors for intra-abdominal sepsis after ileocolic resection for Crohn's disease: an analysis of 621 cases. *Dis Colon Rectum*. 2018;61:e55–e56.
  290. Lightner A, McKenna N, Warusavitarne J, Spinelli A. Intra-abdominal sepsis following ileocolic resection for Crohn's disease: what are the risk factors and are they consistent internationally? *J Crohn's Colitis*. 2018;12(suppl 1):S176.
  291. Bolckmans R, Ratnatunga K, Singh S, et al. Resection for primary ileocecal Crohn's disease: is temporary ileostomy associated with less surgical recurrence. *Colorectal Dis*. 2018;20(suppl 4):47.
  292. Sensi B, D'Ugo S, Bagagli G, Di Giorgio A, Fazzolari L, Sica G. Impact of ileostomy on recurrence rate after ileo-colic resection for Crohn's disease: a critical appraisal from a referral centre. *J Crohn's Colitis*. 2018;12(suppl 1):S441.
  293. Eder P, Michalak M, Katulska K, et al. Magnetic resonance enterographic predictors of one-year outcome in ileal and ileocolonic Crohn's disease treated with anti-tumor necrosis factor antibodies. *Sci Rep*. 2015;5:10223.
  294. Buskens CJ, Bemelman WA. Inclusion of the mesentery in ileocolic resection for Crohn's disease is associated with reduced surgical recurrence: editorial by Coffey et al. *J Crohn's Colitis*. 2018;12:1137–1138.
  295. Luglio G, Giglio MC, Rispo A, et al. Supreme-CD study: surgical prevention of anastomotic recurrence by excluding mesentery in Crohn's disease. preliminary results and trial protocol. *Dig Liver Dis*. 2018;50(suppl 1):e138.
  296. Kono T, Ashida T, Ebisawa Y, et al. A new antimesenteric functional end-to-end handsewn anastomosis: surgical prevention of anastomotic recurrence in Crohn's disease. *Dis Colon Rectum*. 2011;54:586–592.
  297. Resegotti A, Astegiano M, Farina EC, et al. Side-to-side stapled anastomosis strongly reduces anastomotic leak rates in Crohn's disease surgery. *Dis Colon Rectum*. 2005;48:464–468.
  298. Widmar M, Cummings DR, Steinhagen E, et al. Oversewing staple lines to prevent anastomotic complications in primary ileocolic resections for Crohn's disease. *J Gastrointest Surg*. 2015;19:911–916.
  299. Anuj P, Yoon YS, Yu CS, et al. Does anastomosis configuration influence long-term outcomes in patients with Crohn disease? *Ann Coloproctol*. 2017;33:173–177.
  300. 2015 European Society of Coloproctology Collaborating Group. The impact of stapling technique and surgeon specialism on anastomotic failure after right-sided colorectal resection: an international multicentre, prospective audit. *Colorectal Dis*. 2018;20:1028–1040.
  301. Gajendran M, Bauer AJ, Buchholz BM, et al. Ileocecal anastomosis type significantly influences long-term functional status, quality of life, and healthcare utilization in postoperative Crohn's disease patients independent of inflammation recurrence. *Am J Gastroenterol*. 2018;113:576–583.
  302. Buisson A, Chevaux JB, Allen PB, Bommelaer G, Peyrin-Biroulet L. Review article: the natural history of postoperative Crohn's disease recurrence. *Aliment Pharmacol Ther*. 2012;35:625–633.



303. Greenstein AJ, Sachar DB, Pasternack BS, Janowitz HD. Reoperation and recurrence in Crohn's colitis and ileocolitis crude and cumulative rates. *N Engl J Med.* 1975;293:685–690.
304. Regueiro M, Velayos F, Greer JB, et al. American Gastroenterological Association Institute Technical Review on the management of Crohn's disease after surgical resection. *Gastroenterology.* 2017;152:277–295.e3.
305. Nguyen GC, Loftus EV Jr, Hirano I, Falck-Ytter Y, Singh S, Sultan S; AGA Institute Clinical Guidelines Committee. American Gastroenterological Association Institute Guideline on the management of Crohn's disease after surgical resection. *Gastroenterology.* 2017;152:271–275.
306. D'Haens GR, Vermeire S, Van Assche G, et al. Therapy of metronidazole with azathioprine to prevent postoperative recurrence of Crohn's disease: a controlled randomized trial. *Gastroenterology.* 2008;135:1123–1129.
307. Rutgeerts P, Hiele M, Geboes K, et al. Controlled trial of metronidazole treatment for prevention of Crohn's recurrence after ileal resection. *Gastroenterology.* 1995;108:1617–1621.
308. Glick LR, Sossenheimer PH, Ollech JE, et al. Low-dose metronidazole is associated with a decreased rate of endoscopic recurrence of Crohn's disease after ileal resection: a retrospective cohort study. *J Crohns Colitis.* 2019;13:1158–1162.
309. Burr NE, Hall B, Hamlin PJ, Selinger CP, Ford AC, O'Connor A. Systematic review and network meta-analysis of medical therapies to prevent recurrence of post-operative Crohn's disease. *J Crohns Colitis.* 2019;13:693–701.
310. Regueiro M, Feagan BG, Zou B, et al; PREVENT Study Group. Infliximab reduces endoscopic, but not clinical, recurrence of Crohn's disease after ileocolonic resection. *Gastroenterology.* 2016;150:1568–1578.
311. Cañete F, Mañosa M, Casanova MJ, et al; ENEIDA registry by GETECCU. Adalimumab or infliximab for the prevention of early postoperative recurrence of Crohn Disease: results from the ENEIDA Registry. *Inflamm Bowel Dis.* 2019;25:1862–1870.
312. De Cruz P, Kamm MA, Hamilton AL, et al. Crohn's disease management after intestinal resection: a randomised trial. *Lancet.* 2015;385:1406–1417.