

# The American Society of Colon and Rectal Surgeons Clinical Practice Guidelines for the Management of Rectal Cancer

Y. Nancy You, M.D., M.H.Sc.<sup>1</sup> • Karin M. Hardiman, M.D.<sup>2</sup> • Andrea Bafford, M.D.<sup>3</sup>  
 Vitaliy Poylin, M.D.<sup>4</sup> • Todd D. Francone, M.D., M.P.H.<sup>5</sup> • Kurt Davis, M.D.<sup>6</sup>  
 Ian M. Paquette, M.D.<sup>7</sup> • Scott R. Steele, M.D., M.B.A.<sup>8</sup> • Daniel L. Feingold, M.D.<sup>9</sup>  
 On Behalf of the Clinical Practice Guidelines Committee of the American Society of  
 Colon and Rectal Surgeons

- 1 Department of Surgical Oncology, University of Texas MD Anderson Cancer Center, Houston, Texas
- 2 University of Alabama at Birmingham, Birmingham, Alabama
- 3 Department of Surgery, University of Maryland, Baltimore, Maryland
- 4 Gastrointestinal Surgery, Northwestern University Feinberg School of Medicine, Chicago, Illinois
- 5 Department of Surgery, Tufts University Medical School, Boston, Massachusetts
- 6 Department of Surgery, Louisiana State University School of Medicine, New Orleans, Louisiana
- 7 Department of Surgery, University of Cincinnati, Cincinnati, Ohio
- 8 Department of Colorectal Surgery, Cleveland Clinic, Cleveland, Ohio
- 9 Section of Colorectal Surgery, Rutgers University, New Brunswick, New Jersey

The American Society of Colon and Rectal Surgeons (ASCRS) is dedicated to ensuring high-quality patient care by advancing the science, prevention, and management of disorders and diseases of the colon, rectum, and anus. The Clinical Practice Guidelines Committee is composed of society members who are chosen because they have demonstrated expertise in the specialty of colon and rectal surgery. This committee was created to lead international efforts in defining quality care for conditions related to the colon, rectum, and anus and to develop clinical practice guidelines based on the best available evidence. Although they are not proscriptive, these guidelines provide information on which decisions can be made and do not dictate a specific form of treatment. These guidelines are intended for the use of all practitioners, health care workers, and patients who desire information about the management of the conditions addressed by the topics covered in these guidelines.

These guidelines should not be deemed inclusive of all proper methods of care nor exclusive of methods of care reasonably directed toward obtaining the same results. The ultimate judgment regarding the propriety of any spe-

cific procedure must be made by the physician in light of all the circumstances presented by the individual patient.

## STATEMENT OF THE PROBLEM

Colorectal cancer remains the third most common cancer for both men and women, and the second leading cause of cancer-related deaths in the United States annually. It is projected that 145,600 new colorectal cancer cases will have been diagnosed and an estimated 51,020 deaths from colorectal cancer will have occurred in 2019.<sup>1</sup> It is difficult to estimate statistics attributable specifically to rectal cancer because, historically, much of the reporting for rectal cancer has been combined with colon cancer as the single disease entity of “colorectal cancer.”<sup>1</sup> Overall, the incidence of colorectal cancer has declined over the past decades, largely because of risk factor modification and screening.<sup>2</sup> However, the 18- to 50-year age group represents a unique cohort of patients in whom the incidence of rectal cancer has been increasing. In contrast to overall trends, rectal cancer incidence increased by 1.8% annually in younger adults between 1990 and 2013.<sup>1</sup>

In an effort to ensure that patients with rectal cancer receive appropriate care using a multidisciplinary approach, the ASCRS collaborated with a multispecialty effort to develop the National Accreditation Program in Rectal Cancer to create educational modules and a set of clinical standards focusing on program management, clinical services, and quality improvement regarding rectal cancer.<sup>3,4</sup> Because rectal cancer management involves

**CME** Earn Continuing Education (CME) credit online at [cme.lww.com](http://cme.lww.com). This activity has been approved for AMA PRA Category I credit.<sup>TM</sup>

Dis Colon Rectum 2020; 63: 1191–1222  
 DOI: 10.1097/DCR.0000000000001762  
 © The ASCRS 2020

DISEASES OF THE COLON & RECTUM VOLUME 63: 9 (2020)

multiple disciplines working in conjunction with one another, the surgical guidelines presented here must be viewed within that context and represent only a portion of the treatment necessary for the optimal care of patients with rectal cancer. Colorectal cancer screening, bowel preparation, enhanced recovery pathways, surveillance after curative treatment, and prevention of thromboembolic disease, while relevant to the management of patients with rectal cancer, are beyond of the scope of these guidelines and are addressed in other guidelines.<sup>5-9</sup> A guideline focusing on colorectal surgery and frailty is forthcoming.

## METHODOLOGY

These guidelines are based on the last set of ASCRS Practice Parameters for the Management of Rectal Cancer published in 2013.<sup>10</sup> A systematic search of MEDLINE, PubMed, Embase, and the Cochrane Database of Collected Reviews was performed from January 1, 2013 through January 15, 2020. Individual literature searches were conducted for each of the different sections of the guideline (Fig. 1). An additional limitation to core clinical journals was applied if the initial word combination search returned more than 500 articles. Directed searches using embedded references from primary articles were performed in selected circumstances. The 1812 screened articles were evaluated for their level of evidence, favoring clinical trials, meta-analysis/systematic reviews, comparative studies, and large registry retrospective studies over single institutional series, retrospective reviews, and peer-reviewed, observational studies. Additional references identified through embedded references and other sources as well as practice guidelines or consensus statements from relevant societies were also reviewed. A final list of 361 sources was evaluated for methodologic quality, the evidence base was examined, and a treatment guideline was formulated by the subcommittee for this guideline. The final grade of recommendation and level of evidence for each statement were determined using the Grades of Recommendation, Assessment, Development, and Evaluation system (Table 1). When agreement was incomplete regarding the evidence base or treatment guideline, consensus from the committee chair, vice chair, and 2 assigned reviewers determined the outcome. Members of the ASCRS Clinical Practice Guidelines Committee worked in joint production of these guidelines from inception to final publication. Recommendations formulated by the subcommittee were reviewed by the entire Clinical Practice Guidelines Committee. Final recommendations were approved by the ASCRS Executive Council. In general, each ASCRS Clinical Practice Guideline is updated every 5 years. No funding was received for preparing this guideline, and the authors have declared no competing interests related this material. This guideline conforms to the Appraisal of Guidelines for Research and Evaluation (AGREE) checklist.

## Defining the Rectum

The lower limit of the rectum is usually defined by the anorectal ring, an anatomic landmark palpable on physical examination or visible radiographically as the upper border of the anal sphincter and puborectalis muscles.<sup>11</sup> The upper limit of the rectum has been variably defined by the splaying of the teniae coli, the sacral promontory, the proximal valve of Houston, or the level of the peritoneal reflection. A recent consensus conference defined the point of the sigmoid take-off (ie, the junction of the sigmoid mesocolon and mesorectum) as seen on cross-sectional imaging as the upper limit of the rectum.<sup>12</sup> Given that the correlation among these landmarks is imperfect and the presence of all 3 valves of Houston is inconsistent, the upper limit of the rectum, from a clinical perspective, can be somewhat elusive. In practice, the location of a rectal cancer is most commonly assessed by the distance from its distal margin to the anal verge, defined as the beginning of the hair-bearing skin. Tumors within 15 cm of the anal verge are typically classified as rectal cancers, although the total length of the rectum can vary by body habitus and sex.<sup>11</sup>

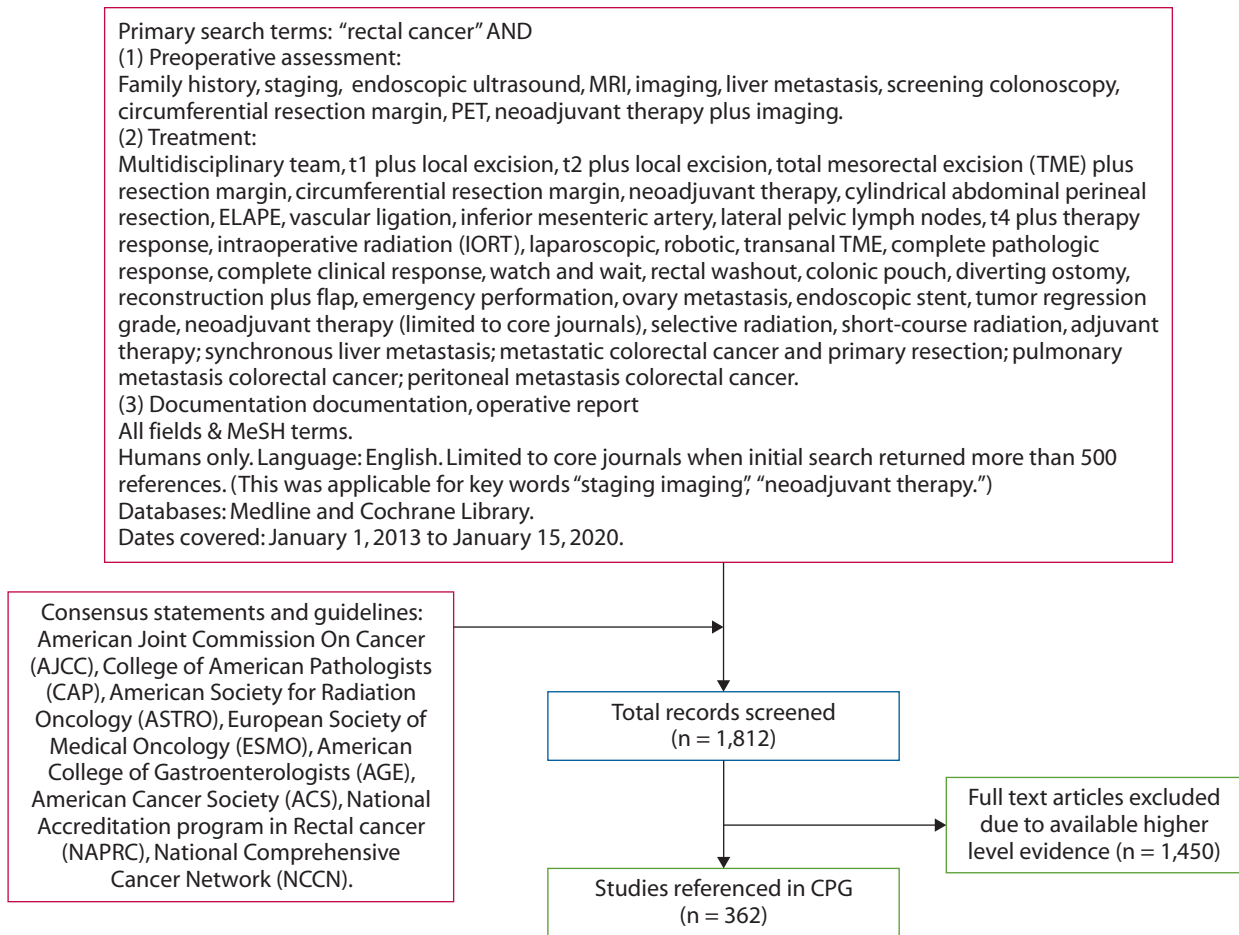
## PREOPERATIVE ASSESSMENT

### Evaluation

1. **A cancer-specific history should be obtained eliciting disease-specific symptoms, associated symptoms, family history, and perioperative medical risk. Routine laboratory values, including CEA level, should also be evaluated, as indicated. Grade of recommendation: Strong recommendation based on moderate-quality evidence, 1B.**

A cancer-specific history remains a cornerstone of the preoperative evaluation. Bleeding, pain, or symptoms related to obstruction should be assessed to help determine the urgency and sequence of evaluation and intervention; this consideration is particularly relevant when neoadjuvant therapy is being considered. Urinary, sexual, and bowel function should be reviewed and symptoms indicative of malignant fistulas or severe radiating pain may alert the surgeon to locally advanced disease involving adjacent pelvic organs. The patient's medical fitness to undergo multimodality treatment should be assessed to guide treatment planning and perioperative management. A thorough discussion of perioperative risk stratification is beyond the scope of this guideline.<sup>13-15</sup>

A family history should typically document relevant premalignant lesions and cancers including details like the age at diagnosis and the lineage of affected first- and second-degree relatives. Patients should be asked about known predisposing hereditary cancer syndromes, prior genetic testing, and family ancestry or ethnicity that may be relevant.<sup>16</sup> Patients with findings suggestive of an inherited susceptibility to colorectal cancer should typically



**FIGURE 1.** PRISMA literature search flow sheet. CPG = Clinical Practice Guideline.

be referred for genetic counseling. Guidelines on the management of patients with inherited colorectal cancer have been previously published.<sup>17,18</sup>

Routine laboratory bloodwork and a CEA level are part of the preoperative evaluation. The baseline CEA level before initiating elective treatment is prognostic of long-term survival and is used as a reference during post-therapy surveillance.<sup>19</sup> Although CEA levels assessed at different time points during multimodality treatment can correlate with treatment response, CEA does not reliably predict pathologic response to neoadjuvant therapy.<sup>20–23</sup> There is insufficient evidence to support the routine use of other tumor markers such as CA19-9 in the evaluation of patients with rectal cancer.<sup>24</sup>

**2. As a part of a complete physical examination, the distance of the distal extent of the cancer from the anal verge and the cancer's relation to the sphincter complex should typically be assessed. Grade of recommendation: Strong recommendation based on low-quality evidence, 1C.**

Assessment of the relationship between the distal extent of the lesion to both the anorectal ring (ie, top of the sphincter complex) as well as the anal verge is essential for

treatment planning and for evaluating the patient's candidacy for sphincter preservation and should ideally be performed before initiating neoadjuvant therapy, which may cause regression of the lesion. The distance should be assessed by digital examination and endoscopically (rigid proctoscopy may provide a more accurate measurement than flexible sigmoidoscopy). Endoscopic tattooing for purposes of anticipated intraoperative localization or to facilitate mucosal surveillance in the event of a clinical complete response may be helpful.<sup>25–29</sup>

**3. Before elective treatment, the histological diagnosis of invasive adenocarcinoma should be confirmed, and patients should typically undergo a full colonic evaluation so the treatment plan can address synchronous pathology, as needed. Grade of recommendation: Strong recommendation based on moderate-quality evidence, 1B.**

It is important to confirm the histological diagnosis of invasive adenocarcinoma before initiating therapy in the elective setting, because rectal neoplasms of other histologies may be amenable to nonresectional or different multimodality treatment options.<sup>30</sup> Because endoscopic biopsy may be nondiagnostic or incongruent with the clinical

**TABLE 1.** The GRADE system: grading recommendations

Grade	Description	Benefit versus risk and burdens	Methodologic quality of supporting evidence	Implications
1A	Strong recommendation, High-quality evidence	Benefits clearly outweigh risk and burdens or vice versa	RCTs without important limitations or overwhelming evidence from observational studies	Strong recommendation, can apply to most patients in most circumstances without reservation
1B	Strong recommendation, Moderate-quality evidence	Benefits clearly outweigh risk and burdens or vice versa	RCTs with important limitations (inconsistent results, methodologic flaws, indirect or imprecise) or exceptionally strong evidence from observational studies	Strong recommendation, can apply to most patients in most circumstances without reservation
1C	Strong recommendation, Low- or very-low quality evidence	Benefits clearly outweigh risk and burdens or vice versa	Observational studies or case series	Strong recommendation but may change when higher-quality evidence becomes available
2A	Weak recommendation, High-quality evidence	Benefits closely balanced with risks and burdens	RCTs without important limitations or overwhelming evidence from observational studies	Weak recommendation, best action may differ depending on circumstances or patients' or societal values
2B	Weak recommendations, Moderate-quality evidence	Benefits closely balanced with risks and burdens	RCTs with important limitations (inconsistent results, methodologic flaws, indirect or imprecise) or exceptionally strong evidence from observational studies	Weak recommendation, best action may differ depending on circumstances or patients' or societal values
2C	Weak recommendation, Low- or very-low quality evidence	Uncertainty in the estimates of benefits, risks and burden; benefits, risk, and burden may be closely balanced	Observational studies or case series	Very weak recommendations; other alternatives may be equally reasonable

GRADE = Grades of Recommendation, Assessment, Development, and Evaluation; RCT = randomized controlled trial.

Adapted from Guyatt G, Guterman D, Baumann MH, et al. Grading strength of recommendations and quality of evidence in clinical guidelines: report from an American College of Chest Physicians Task Force. *Chest*. 2006;129:174–181.<sup>362</sup> Used with permission.

impression of invasive adenocarcinoma because of a sampling error, repeat endoscopic or operative biopsies may be required to establish the histological diagnosis for purposes of treatment planning. Operative excisional biopsy is typically not performed unless it is done as a curative-intent transanal full-thickness excision with adequate radial margins as discussed in detail later.

Patients newly diagnosed with rectal cancer should typically undergo a full colon evaluation. Although the incidence of synchronous colorectal cancer is low, in the range of 1% to 3%, the incidence of synchronous adenomas or other polyps can be as high as 30%.<sup>31–34</sup> Colonoscopy is a preferred evaluation method because it offers a therapeutic platform to treat synchronous polyps.<sup>35,36</sup> In cases where a colonoscopy is not completed, for instance, due to an obstructing cancer, CT colonography may be used.<sup>37–40</sup> Computed tomography colonography has been shown to be a superior diagnostic study compared with double-contrast barium enema among patients with symptoms suggestive of colorectal cancer and can detect synchronous lesions.<sup>41</sup> In patients receiving neoadjuvant therapy, colonoscopy may be reattempted if there is sufficient tumor regression to permit passage of a colonoscope. If a preoperative colon evaluation is not performed, typically in cases where urgent intervention is needed for

obstructing lesions, a complete colonoscopy should be planned postoperatively.

### Staging

- 1. Rectal cancer should typically be staged according to the American Joint Committee on Cancer TNM system before initiating treatment. Grade of recommendation: Strong recommendation based on moderate-quality evidence, 1B.**

Rectal cancer should be staged according to the TNM system before treatment, except when emergent surgery is required. The TNM system, as defined by the American Joint Committee on Cancer, describes the depth of local tumor invasion (T stage), the extent of regional lymph node involvement (N stage), and the presence of distant metastasis (M stage).<sup>42,43</sup> Updated 8th edition staging definitions categorize lymph nodes harboring micrometastasis (clusters of 20 or more cancer cells or metastases measuring >0.2 mm and <2 mm in diameter) as N1 disease, the presence of tumor deposits (N1c disease) as stage III regardless of the status of the lymph nodes, and peritoneal metastases as M1c disease.<sup>42,43</sup> Rectal cancer should be described by both its initial clinical stage (cTNM), which guides treatment decisions, as well as the final pathologic

stage (pTNM), which can provide prognostic information.<sup>42</sup> Clinical stage can be further prefixed to designate the staging modality used, including u for ultrasound, mr for MRI, and ct for CT scan. For patients treated with preoperative therapy, pathologic tumor response is reported as ypTNM.<sup>44,45</sup>

**2. Rectal cancer protocol pelvic MRI is the preferred modality for locoregional clinical staging. Endorectal ultrasound (EUS) may be considered when differentiating between early T stages (ie, T1 versus T2 tumors) or when MRI is contraindicated. Grade of recommendation: Strong recommendation based on moderate-quality evidence, 1B.**

Magnetic resonance imaging staging of rectal cancer, using standardized technical protocols and reporting templates, assesses the depth of tumor penetration, presence of locoregional nodal metastases, and the relationship between lesions (tumor and/or nodes) within the mesorectum and the mesorectal fascia.<sup>46,47</sup> Thus, MRI can help predict surgical clearance of the circumferential resection margin (CRM), the shortest distance between disease (tumor and/or malignant nodes) and the mesorectal fascia.<sup>47–49</sup> A positive CRM has been variably defined as cancer within 1 mm or within 2 mm<sup>50,51</sup> of the mesorectal fascia or levator ani muscle; the National Comprehensive Cancer Network currently defines it as within 1 mm.<sup>52</sup> A positive CRM is associated with increased risk for local recurrence and decreased survival (5-year local recurrence: HR = 3.50; 95% CI, 1.53–8.00;  $p < 0.05$ ; 5-year overall survival: HR = 1.97; 95% CI, 1.27–3.04;  $p < 0.01$ ).<sup>53–55</sup> Primary tumor features including T4 status, extramural vascular invasion, CRM within 1 mm, or extramural tumor depth of at least 5 mm are considered high-risk features.<sup>56,57</sup> These factors should be considered as a critical part of clinical staging and are vital for planning preoperative therapy as discussed in Multidisciplinary Treatment Planning.

Endorectal ultrasound should typically be considered complementary to MRI for purposes of clinical staging and is most useful in differentiating between early T stages (ie, T1 versus T2 tumors).<sup>57</sup> Magnetic resonance imaging may also be contraindicated when certain implantable medical devices are present (ie, metallic implants, MR incompatible pacemakers).<sup>58,59</sup> Disadvantages of EUS include operator dependency, limited accuracy in assessing bulky or locally advanced lesions, patient discomfort, and inability to evaluate stenotic lesions that preclude passage of the transducer.<sup>58,59</sup>

Accurately staging potentially involved pelvic lymph nodes (including mesorectal, lateral pelvic, and inguinal compartments) remains a diagnostic challenge for all imaging modalities.<sup>60</sup> Sensitivity and specificity for clinical nodal staging have been reported as 55% and 74% for CT, 67% and 78% for EUS, and 66% and 76% for MRI.<sup>48,61</sup> Nodal staging accuracy may be improved by incorporat-

ing criteria such as a spiculated border and mixed signal intensity as seen on MRI.<sup>57,62,63</sup>

**3. Clinical staging for metastatic disease should typically be conducted in patients with rectal cancer. Grade of recommendation: Strong recommendation based on moderate-quality evidence, 1B.**

Clinical staging of distant metastatic disease should typically be completed before initiating treatment, because the presence of metastatic disease influences the treatment plan. In patients with metastatic rectal cancer from the Swedish Cancer Registry, the most common sites of metastasis were liver (70%), lung (47%), bone (12%), and nervous system (8%).<sup>64</sup> Clinical staging should typically include contrast-enhanced CT scan of the chest, abdomen, and pelvis. Pulmonary CT, with its increased sensitivity and better ability to arbitrate otherwise indeterminate lesions over time, is recommended rather than chest x-ray.<sup>65,66</sup> Computed tomography without intravenous contrast followed by triphasic (arterial, venous, and portal) contrast is generally the modality of choice for detecting and characterizing hepatic lesions.<sup>67–69</sup> For smaller lesions, and to evaluate a liver with background fatty liver changes, MRI may be superior to multidetector CT and positron emission tomography (PET).

There is insufficient evidence to support the routine use of PET/CT alone in the clinical staging of primary rectal cancer.<sup>60</sup> Although PET/CT has been used for staging patients with suspected disease recurrence or for excluding other sites of distant disease in patients with stage IV rectal cancer being considered for curative-intent surgery, the evidence supporting added clinical value is limited.<sup>70,71</sup> Positron emission tomography /CT may have a role in evaluating equivocal findings on contrast-enhanced CT.<sup>72,73</sup>

**4. Restaging evaluation should be considered after neoadjuvant therapy in patients with locally advanced rectal cancer. Grade of recommendation: Strong recommendation based on low-quality evidence, 1C.**

Restaging evaluation consisting of clinical and endoscopic assessment and cross-sectional imaging should typically be considered after neoadjuvant therapy, in particular, if the assessment of local tumor response would influence the need for additional therapy and/or alter the surgical approach, or if there is a unique concern for interval development of metastatic disease. Importantly, restaging evaluates patients for a possible clinical complete response (cCR) and can adjust patient expectations. Some studies have demonstrated a change in treatment strategy after restaging in 11% to 15% of patients, typically due to identification of metastatic disease, but others have shown limited or no benefit to restaging.<sup>74,75</sup> Although restaging is typically performed by repeating the same imaging studies that were done initially, the assessment of tumor response

to neoadjuvant therapy has been challenging because of limited T and N staging accuracy for MRI, CT, or EUS in this setting.<sup>76-79</sup> Advanced functional MRI (ie, diffusion-weighted MRI) and/or PET/CT scan may potentially improve the accuracy of assessing treatment response.<sup>70,80</sup>

### **Multidisciplinary Treatment Planning**

- 1. The treatment of patients with rectal cancer should typically incorporate a multidisciplinary team tumor board discussion. Grade of recommendation: Strong recommendation based on low-quality evidence, 1C.**

Optimal management of patients with rectal cancer requires input and coordination among a team of clinicians including expertise from surgery, pathology, radiology, radiation, and medical oncology, and other ancillary team members. Although discussion of rectal cancer management by an multidisciplinary team can improve preoperative clinical staging, modify and individualize multimodality treatment, plan technical aspects of surgery, and review pathologic staging, more studies are needed to demonstrate a potential impact on disease-free and overall survival (OS).<sup>81-83</sup>

- 2. If either a temporary or permanent ostomy is being considered, preoperative education and stoma site marking should typically be performed. Grade of recommendation: Strong recommendation based on moderate-quality evidence, 1B.**

Consultation with an enterostomal therapist is typically recommended for patients whose rectal cancer treatment may involve stoma creation. Preoperative stoma site marking and patient education can improve time to ostomy proficiency and decrease ostomy-related complications.<sup>84-86</sup> Guidelines on stoma marking and surgery have been previously published.<sup>87,88</sup>

## **TREATMENT**

### **Surgical Techniques and Operative Considerations**

#### **Local Excision**

- 1. Local excision is an appropriate treatment modality for carefully selected patients with cT1N0 rectal cancer without high-risk features. Grade of recommendation: Strong recommendation based on moderate-quality evidence, 1B.**

Local excision is an acceptable curative-intent treatment in highly selected patients with cT1N0 rectal cancer with favorable clinical and histological features. Transanal excision may also be appropriate for patients with more advanced cT disease but who are considered medically unfit for radical cancer surgery. Whereas local excision offers advantages of minimizing operative risk and functional

sequelae, it does not adequately remove or pathologically stage the mesorectal lymph nodes. The risk of occult nodal metastasis from T1 lesions ranges from 6% to 11% with greater risk associated with pathologic features such as SM3 invasion, poor differentiation, tumor budding, and lymphovascular or perineural invasion.<sup>89,90</sup> Accurate preoperative staging and careful patient selection are essential when contemplating local excision. Distinguishing early depth of invasion (ie, Tis, T1, T2) may be difficult with MRI, and EUS may be utilized as a complementary staging tool in certain situations. Clinical criteria for local excision typically include small (<3 cm) adenocarcinomas limited to <30% of the rectal circumference, that are well or moderately differentiated, without lymphovascular invasion, perineural invasion, tumor budding on tissue biopsy, and no clinical nodal involvement, and that are accessible transanally for full-thickness excision.<sup>52</sup> Given our current understanding of the applicability of local excision, the grade of this statement has been changed from a 2B in the 2013 guidelines to a 1B.<sup>10</sup>

Technically, local excision involves full-thickness excision, ideally with a  $\geq 10$  mm grossly normal circumferential margin with a depth down to perirectal fat providing a minimum of a 2-mm-deep margin.<sup>52</sup> The surgeon should typically orient the specimen to facilitate pathologic assessment, and tangential, piecemeal, or fragmented excision should be avoided, if possible. The procedure can be performed as a conventional transanal excision or by using a transanal endoscopic platform like transanal endoscopic microsurgery (TEMS) or transanal minimally invasive surgery (TAMIS). While there is a paucity of well-designed randomized, controlled trials, studies suggest that TEMS offers better visualization and access to more proximal lesions than conventional transanal excision, and TEMS and TAMIS appear to be comparable.<sup>91-93</sup> Endoscopic submucosal dissection, an advanced colonoscopic procedure, can potentially treat lesions with very superficial submucosal invasion, but the optimal patient selection criteria for this approach remain controversial.<sup>94</sup>

The rate of local recurrence following local excision varies from 7% to 21% for T1 lesions and is consistently higher than that after radical resection.<sup>95-97</sup> Patients should appreciate that if pathologic examination reveals significant risk factors like deeper T stage, inadequate margins, poor differentiation, deep submucosal (SM3) invasion, tumor budding, or lymphovascular or perineural invasion, subsequent radical resection will typically be recommended.

In general, local excision is considered an oncologically inadequate treatment for cT2 lesions because the local recurrence rate ranges from 26% to 47%, and these tumors have an elevated risk for harboring occult nodal disease.<sup>98</sup> Radical resection should typically be recommended under these circumstances.

When patients with high-risk T1 and T2 lesions refuse radical resection or prioritize sphincter preservation, adjuvant chemoradiation in combination with local excision has been considered. In a systematic review of patients with pT1/T2 rectal lesions removed by local excision, those who went on to receive adjuvant chemoradiation ( $n = 405$ ) were compared to those who underwent radical resection ( $n = 130$ ). Despite the limited retrospective data and selection bias, the weighted average local recurrence rates for adjuvant chemoradiation and radical resection were 10% (95% CI, 4–21) versus 6% (95% CI, 3–15) for pT1 lesions and 15% (95% CI, 11–21) versus 10% (95% CI, 4–22) for pT2 lesions.<sup>99</sup> Thus, in high-risk patients who refuse or are unfit for radical resection, adjuvant chemoradiation should typically be recommended after local excision and should be followed by surveillance for a potentially salvageable recurrence.<sup>100</sup>

Local excision has also been performed after neoadjuvant chemoradiation for select T1/T2 lesions. This approach has been studied in clinical trials.<sup>101–104</sup> Two prospective trials randomly assigned 50<sup>104</sup> and 47<sup>103</sup> patients with cT2 rectal cancer to neoadjuvant chemoradiation and local excision versus standard resection. Long-term data reported no statistically significant differences in local recurrence or disease-free survival. However, a pooled analysis demonstrated high rates of morbidity (22.3%), in particular, postoperative pain and suture line dehiscence (9.7% for each).<sup>105,106</sup> These patients require counseling regarding possible long-term outcomes, and the safety and efficacy of this approach remain unestablished in routine clinical practice.

### Radical Resection

**1. A thorough surgical exploration should typically be performed at the time of operation. Grade of recommendation: Strong recommendation based on low-quality evidence, 1C.**

Surgical exploration should typically include a thorough assessment of the peritoneal cavity and the abdominal organs to detect or rule out metastatic disease (eg, radiographically occult metastasis, carcinomatosis), more advanced local disease (eg, fixation to adjacent organs), synchronous lesions, or coexisting pathology.<sup>107</sup> Unexpected findings that impact the operative plan and the decision to proceed with the operation should, ideally, be discovered before ligating the vascular pedicle and committing to a resection.

**2. For curative resection of tumors of the upper third of the rectum, a tumor-specific mesorectal excision should typically be performed as part of a low anterior resection (LAR) with the mesorectum divided, ideally, at least 5 cm below the distal margin of the tumor. For tumors of the middle and lower thirds of the rectum, total mesorectal**

**excision (TME) should typically be performed as a part of an ultralow anterior resection or abdominoperineal resection (APR). A 2-cm distal mural margin is usually adequate for distal rectal cancers when combined with TME. A 1-cm distal mural margin is generally acceptable for cancers located at or below the mesorectal margin. Grade of recommendation: Strong recommendation based on the high-quality evidence, 1A.**

Appropriate surgical technique is integral to optimizing oncological outcomes and minimizing morbidity, and should follow the principles and anatomic planes of a TME. Dissection between the visceral and parietal layers of the endopelvic fascia facilitates en bloc removal of the rectal cancer and associated mesentery, lymphatics, and tumor deposits. Mesorectal excision can preserve the autonomic nerves and reduce intraoperative bleeding and the rate of local recurrence.<sup>108</sup> Among patients registered in Medical Research Council (MRC) CR07 and NCIC-CTG CO16 trial, the 3-year local recurrence rate was 4% for the group with a good (ie, mesorectal) plane of dissection compared with 13% for the group with a poor (ie, muscularis propria) plane of dissection ( $p = 0.003$ ).<sup>109</sup>

Importantly, distal mesorectal spread of rectal cancer often extends further than distal intramural spread. Although distal intramural spread is relatively uncommon (found beyond 1 cm from the distal edge of the intraluminal cancer in only 4% to 10% of rectal cancers), deposits of distal mesorectal nodal spread can occur up to 3 to 4 cm distal to the primary cancer.<sup>110,111</sup> To address the propensity for both intramural and mesorectal involvement, for tumors of the upper rectum, the mesorectal excision should typically extend 5 cm below the distal edge of the tumor; for tumors of the middle and lower rectum, a TME (ie, excision of all mesorectum to its most distal extent) is required with a distal rectal resection margin of, ideally, at least 2 cm. For tumors of the very distal rectum at or below the mesorectal margin, a mural margin of 1 cm appears acceptable in conjunction with a TME in appropriately selected patients.<sup>112</sup> Even shorter distal margins may be acceptable in selected patients who are highly motivated for sphincter preservation and who have demonstrated favorable tumor regression after neoadjuvant therapy.<sup>113–115</sup> In cases where preoperative anal function and distal pathologic clearance are adequate, TME may be followed by creation of an ultralow colorectal anastomosis or coloanal anastomosis. In cases where the tumor directly involves the anal sphincter or the levator muscles, where there is loss of integrity of the intersphincteric plane, or where a margin-negative resection of the tumor would result in unacceptable sphincter function, an APR should typically be performed.

In addition to addressing the distal resection margin, obtaining an adequate CRM is critical, because a positive CRM independently predicts worse local recurrence and

disease-free survival (DFS).<sup>109,116</sup> A positive CRM is more likely when disease (tumor, adenopathy, or tumor deposit) is present within 1 mm of the mesorectal fascia<sup>55</sup> and/or when an inappropriate dissection plane within the mesorectum is used rather than a TME.<sup>109</sup>

Abdominoperineal resection, compared with LAR, has historically been associated with higher risks for a positive CRM and tumor perforation, which are adverse prognostic indicators for local recurrence and reduced OS.<sup>117–121</sup> Extralevator abdominoperineal excision (ELAPE), a surgical technique that emphasizes wide division of the levator ani muscle en bloc with the rectum and the anal canal, aims to minimize the risks of CRM positivity and intraoperative tumor perforation and results in a cylindrical pathologic specimen without the “waist” typically seen after conventional APR.<sup>122–124</sup> The procedure can be performed in a lithotomy or prone jackknife position and is associated with larger perineal defects and increased risk for perineal wound complications like hernia and poor wound healing.<sup>125</sup> Although the conclusions of systematic reviews comparing ELAPE and conventional APR have been inconsistent, ELAPE is likely best used selectively in the subgroup of patients with bulky and locally advanced rectal cancers that involve the levator muscle, are anteriorly located, or are otherwise at higher risk for intraoperative perforation.<sup>126–131</sup>

**3. Vascular ligation at the origin of the superior rectal artery with resection of the associated lymphatic drainage is typically appropriate for rectal cancer resection. Grade of recommendation: Strong recommendation based on moderate-quality evidence, 1B.**

Curative resection of rectal cancer involves removing the blood supply and lymphatics from the origin of the superior rectal artery. Ligating the inferior mesenteric artery (IMA) just distal to the takeoff of the left colic artery at the origin of the superior rectal artery has been termed “low tie,” whereas ligating the IMA at its takeoff from the aorta has been termed “high tie.” Routine low tie with resection of all associated lymphatic tissue is typically appropriate for rectal cancer resection.<sup>107,132</sup> Given the evidence, this guideline grade was adjusted from a 1A in 2013 to a 1B.

High tie of the IMA with resection of associated lymph nodes is indicated in selected patients when clinically suspicious lymph nodes are present at the level of the IMA. Nodal metastasis at this level is prognostic for systemic spread including extended periaortic nodal metastases.<sup>133,134</sup> Suspicious periaortic lymph nodes should typically be biopsied, and a more extended lymph node dissection can be performed at the discretion of the surgeon.<sup>107</sup> A high tie may also be indicated when vascular ligation at the level of the IMA is needed to provide mobilization to afford adequate length for a tension-free anastomosis.

There is currently insufficient evidence to support routine high tie practice. This technique raises a theoretical concern for possible increased risk of anastomotic leak, and its purported oncologic superiority remains unestablished. Systematic reviews comparing low tie and high tie have shown no significant differences in blood loss, surgical times, defecatory function, postoperative complications, or survival, whereas low tie has been shown to better preserve genitourinary function.<sup>135,136</sup>

**4. In the absence of a clinically positive lymph node in the lateral pelvic compartment, routine lateral pelvic lymph node dissection is not typically required. Grade of recommendation: Strong recommendation based on low-quality evidence, 1C.**

Lateral pelvic lymph node dissection (LPLND) removes the nodal compartment along the common iliac, internal iliac, and obturator arteries. A meta-analysis including 5502 patients from 20 studies (only one was randomized) compared TME with LPLND to TME without LPLND and found that LPLND did not confer a significant survival benefit, but increased male urinary and sexual dysfunction was suggested.<sup>137</sup> Nonetheless, since the lateral compartment is an area of concern for recurrent disease that may be difficult to salvage, ipsilateral LPLND of clinically positive lateral pelvic nodes is indicated.<sup>138,139</sup> Although the size criteria for a “clinically positive” lymph node in this setting remains controversial, the International Lateral Node Study Consortium found that patients with lateral pelvic nodes of more than 7 mm in the short axis on pretreatment MRI experienced significantly less local recurrence when treated with chemoradiation, TME, and LPLND (5.7%) in comparison with chemoradiation and TME without LPLND (19.5%,  $p = 0.04$ ).<sup>139</sup> For patients with clinically negative lateral nodes at diagnosis, the JCOG0212 trial randomly assigned 701 patients who were not treated with chemoradiation to TME versus TME plus LPLND. Among the 328 patients who underwent LPLND, the rate of pathologically positive lateral pelvic nodes was 7.3%.<sup>140</sup> Tumor below the peritoneal reflection (OR = 8.95; 95% CI, 1.18–68.04;  $p = 0.03$ ) and lateral pelvic node > 5 mm at diagnosis (OR = 4.06; 95% CI; 1.59–10.34;  $p = 0.003$ ) were associated with pathologically positive lateral nodes.<sup>140</sup> In the setting of no neoadjuvant chemoradiation, the TME plus LPLND group had a lower local recurrence rate than the TME group (7.4% versus 12.6%,  $p = 0.02$ ) although no difference in 5-year relapse-free survival (73.3% versus 73.4%).<sup>141</sup>

**5. In patients with T4 rectal cancer, curative-intent resection of involved adjacent organs should typically be performed en bloc. Grade of recommendation: Strong recommendation based on moderate-quality evidence, 1B.**

Curative-intent surgical management of patients with T4 rectal cancer should aim to achieve an R0 (microscopically



negative) resection margin, because surgical margin is a key determinant of overall prognosis.<sup>142,143</sup> R0 resection in these patients often requires an extended or multivisceral resection with dissection beyond the TME plane.<sup>144</sup> Careful preoperative evaluation is necessary to assess the likelihood of surgical curability, plan neoadjuvant therapy, and orchestrate a multispecialty surgical team. Magnetic resonance imaging can predict rectal cancers that are unlikely to be amenable to a curative resection.<sup>145</sup> Patients with disease invading adjacent organs within the central pelvic compartment, typically amenable to an R0 resection, usually undergo neoadjuvant chemoradiation which can decrease the risk of local failure.<sup>101</sup> Patients with disease breaching the central compartment and extending to the lateral pelvic sidewall and/or sacrum are more challenging; preoperative therapy in these patients aims to induce tumor regression and may include both systemic chemotherapy and otherwise standard chemoradiation as discussed in Multidisciplinary Treatment Planning.<sup>146,147</sup>

There is ongoing controversy regarding the most appropriate management of patients with tumor extension into an adjacent organ who undergo neoadjuvant therapy and experience a response such that the cancer no longer involves the adjacent structure. Although these patients, classically, have undergone en bloc resection of the previously involved tissues, an alternative approach involves individualizing therapy by changing the management strategy to allow for preservation of a pelvic organ or the anal sphincter complex. In a retrospective series of 101 patients with mrT4b disease, of 67 patients whose post-neoadjuvant restaging MRI showed significant tumor downstaging, a change in the surgical strategy allowing organ preservation was feasible in 42 patients (63%), and the responders' 3-year local recurrence rate was 14%; the local recurrence rate among the 34 nonresponders who had an inadequate response to neoadjuvant therapy was significantly higher (32%; HR = 1.6; 95% CI, 1.02–2.59;  $p = 0.04$ ).<sup>148</sup>

**6. Intraoperative radiation therapy may be used in selected patients with microscopically involved (R1) or close resection margins. Grade of recommendation: Weak recommendation based on low-quality evidence, 2C.**

Intraoperative radiation therapy (IORT), a dose escalation tool to potentially improve local control, allows targeted delivery of a high fraction of radiation to a resection bed intraoperatively and is available as high-dose rate IORT and intraoperative electron radiation therapy. Although reported doses range between 10 Gy and 20 Gy, the exact dose is tailored to margin status and the nature of the irradiated tissue.<sup>149</sup>

The utility of IORT remains controversial. A systematic review and meta-analysis including 3003 patients with colorectal cancer treated with IORT from 14 prospective and 15 retrospective studies reported that IORT was used

to treat locally advanced primary cancer in 61% of the patients and locally recurrent disease in 39% of the patients.<sup>150</sup> There is no role for routine IORT in the setting of an optimal R0 resection. A randomized, controlled trial of 142 patients with locally advanced primary rectal cancer treated with neoadjuvant chemoradiation and resection with or without IORT showed that 5-year local control exceeded 90% in both arms and that there was no added benefit to IORT.<sup>151</sup>

The most commonly reported indications for IORT are microscopically positive (R1) or narrowly negative (2 mm or less tumor-free margin) colorectal cancer resection margins, as determined by intraoperative frozen pathologic assessment.<sup>150,152–154</sup> Retrospective studies regarding the use of IORT for selected patients with high-risk primary rectal cancers have reported favorable 5-year local control rates of over 85%.<sup>149,150</sup> Intraoperative radiation therapy in the setting of locally recurrent rectal cancer has been associated with 5-year local control rates ranging from 25% to 79%, although patient selection bias influences these outcomes.<sup>150</sup> Despite the heterogeneity of the available studies, an aggregate review of comparative studies of patients with colorectal cancer reported that IORT was associated with improved local control (pooled OR = 0.22; 95% CI, 0.05–0.86;  $p = 0.03$ ) and improved DFS (HR = 0.51; 95% CI, 0.31–0.85;  $p = 0.009$ ) compared with patients who did not receive IORT.<sup>150</sup>

The complications most commonly attributed to IORT are wound infection and pelvic abscess, with reported rates of 25% or more.<sup>149</sup> The large systematic review summarized above showed that IORT was associated with increased wound complications (OR = 1.86; 95% CI, 1.03–3.38;  $p = 0.04$ ) but not overall (OR = 1.13; 95% CI, 0.77–1.65;  $p = 0.57$ ), urologic (OR = 1.35; 95% CI, 0.84–2.82;  $p = 0.47$ ), or anastomotic (OR = 0.94; 95% CI, 0.42–2.1;  $p = 0.98$ ) complications.<sup>150</sup>

**7. Minimally invasive approaches to TME can be considered and should typically be performed by experienced surgeons with technical expertise. Grade of recommendation: Strong recommendation based on high-quality evidence, 1A.**

Minimally invasive surgery (MIS) for rectal cancer improves short-term perioperative outcomes, but, in contrast to MIS for colon cancer, the long-term oncologic results of MIS for rectal cancer remain unclear.<sup>155</sup> Randomized, controlled trials have raised concerns regarding the pathologic outcomes of laparoscopic resection for rectal cancer, and the impact of these outcomes on long-term survival is still being elucidated. Before 2015, 3 phase III trials (COLOR II, CLASICC, and COREAN) randomly assigned patients with rectal cancer to laparoscopic versus open resection.<sup>153–157</sup> All 3 trials showed no significant differences in 3-year local recurrence rates or 5-year DFS rates; however, the CLASICC trial, which randomly as-

signed 794 patients at a 2:1 ratio to laparoscopic versus open resection, reported a slightly higher, although not statistically significant, CRM positivity rate in the laparoscopic group (16% versus 14%;  $p = 0.8$ ).<sup>156–159</sup> Given the currently available literature, the statement grade regarding MIS for rectal cancer was changed from a 1B in the 2013 guidelines to a 1A.<sup>10</sup>

Two more recent phase III, randomized, controlled trials each failed to demonstrate noninferiority of laparoscopy compared with open surgery for rectal cancer when composite pathologic end points were examined. The ACOSOG Z6051 trial randomly assigned patients with rectal cancer to laparoscopic ( $n = 244$ ) or open ( $n = 222$ ) surgery and reported that the composite primary end point (CRM  $>1$  mm, negative distal margin, and TME completeness) was met in significantly fewer patients in the laparoscopic arm (81.7%; 95% CI, 76.8%–86.6% versus 86%; 95% CI, 82.5%–91.4%).<sup>160</sup> The Australian trial, ALaCaRT, similarly determined the success of resection using a composite end point after randomly assigning patients to laparoscopy ( $n = 238$ ) or open ( $n = 237$ ) surgery. Successful resection was achieved in significantly fewer patients in the laparoscopic arm (82% versus 89%; risk difference of  $-7.0\%$ ; 95% CI,  $-12.4\%$  to  $\infty$ ;  $p = 0.38$  for noninferiority).<sup>161</sup> Meta-analyses of randomized, controlled trials have reported higher rates of incomplete resection defined as failure to resect an intact mesorectum with no defects deeper than 5 mm and no coning toward the distal margin (13.2% versus 10.4%; RR = 1.31; 95% CI, 1.05–1.64;  $p = 0.02$ ) in the laparoscopic groups.<sup>162,163</sup>

Although the pathologic outcomes related to MIS rectal cancer surgery are concerning, available survival outcomes from the relevant trials are still limited to less than a 5-year median follow-up duration. In the ACOSOG Z6051 trial, 462 patients were eligible for survival analysis at a median of 3.9 years after laparoscopic ( $n = 240$ ) or open ( $n = 222$ ) resection.<sup>164</sup> The surgical approaches did not differ with respect to 2-year DFS (laparoscopic 79.5%; 95% CI, 74.4–84.9 versus open 83.2%; 95% CI, 78.3–88.3), and had similar rates of locoregional recurrence (laparoscopic 4.6% versus open 4.5%), and distant recurrence (laparoscopic 14.6% versus open 16.7%). In this trial, worse DFS was associated with unsuccessful resection (HR = 1.87; 95% CI, 1.21–2.91), defined as the composite of incomplete specimen (HR = 1.65; 95% CI, 0.85–3.18), positive CRM (HR = 2.31; 95% CI, 1.40–3.79), and positive distal margin (HR = 2.53; 95% CI, 1.30–3.77).<sup>164</sup> In the ALaCaRT trial, 450 patients (225 laparoscopic and 225 open resections) were followed for a median of 3.2 years. The 2 groups did not significantly differ in 2-year local recurrence rate or 2-year DFS. Because event rates were low at the 2-year interval, longer follow-up is needed to better evaluate the oncologic impact of the surgical approach.<sup>165</sup>

Data regarding robotic rectal cancer surgery have yet to mature. The ROLARR trial randomly assigned patients to robotic ( $n = 237$ ) versus laparoscopic ( $n = 234$ ) rectal cancer surgery and did not demonstrate a significant reduction in the conversion rate (the primary end point) and showed no difference in the CRM positivity rate (5.1% robotic versus 6.3% laparoscopic; adjusted OR = 0.78; 95% CI, 0.35–1.76;  $p = 0.56$ ).<sup>166</sup> A meta-analysis of 1305 patients with rectal cancer from 8 randomized trials comparing robotic ( $n = 647$ ) versus laparoscopic ( $n = 658$ ) surgery showed lower rates of conversion to open in the robotic group (5.7% versus 11.9%; 95% CI, 1.36–3.61;  $p = 0.001$ ). Pathologic outcomes including resection margin status and number of lymph nodes harvested were similar between the groups, but no comparisons of oncologic outcomes were reported.<sup>167–169</sup>

**8. Transanal total mesorectal excision (taTME) remains controversial with regard to perioperative and long-term oncologic outcomes. Grade of recommendation: Strong recommendation based on moderate-quality evidence, 1B.**

Transanal TME (taTME), proposed to overcome some of the technical challenges of laparoscopic distal mesorectal surgery, builds on the techniques developed for transabdominal–transanal operations, TEMS and TAMIS. A systematic review of 7 retrospective studies comparing taTME ( $n = 270$ ) with laparoscopic TME ( $n = 303$ ) showed shorter operation times (weighted mean difference =  $-23.45$ ; 95% CI,  $-37.43$  to  $-9.46$ ;  $p < 0.01$ ) and a lower conversion rate (OR = 0.29; 95% CI, 0.11–0.81;  $p = 0.02$ ) for the taTME approach, and other systematic reviews have confirmed these trends.<sup>170–172</sup>

TaTME has been reported to be associated with a technical learning curve of approximately 40 cases.<sup>173,174</sup> Intraoperative adverse events reported by the International taTME Registry include dissecting incorrect tissue planes during the perineal phase of operation with attendant injuries to the urethra, bladder, vagina, and rectum; problems maintaining pneumopelvis have also been reported.<sup>175</sup> Recently, a collaborative retrospective study from 2 international taTME registries highlighted 25 cases of carbon dioxide (CO<sub>2</sub>) embolism among 6375 cases, yielding an estimated incidence of 0.4%.<sup>176</sup> CO<sub>2</sub> embolism under these circumstances occurs in the setting of venous bleeding and pneumopelvis and may be manifested by a fall in the end-tidal CO<sub>2</sub> (in 88% of the reported cases) or hemodynamic instability (in 52% of the reported cases) potentially leading to cardiovascular collapse requiring cardiopulmonary resuscitation.<sup>176,177</sup> When a CO<sub>2</sub> embolism is suspected, pneumopelvis should be released, the patient should be placed in left lateral decubitus and Trendelenburg position, and appropriate hemodynamic support should be instituted.<sup>177</sup>

A systematic analysis of 17 studies comparing 600 patients undergoing taTME and 639 patients undergoing laparoscopic/robotic TME found that taTME was associated with a lower risk of CRM positivity (OR = 0.47; 95% CI, 0.29–0.75;  $p = 0.002$ ).<sup>170</sup> However, a Norwegian case review of 110 taTME procedures found a local recurrence rate of 9.5% after a short, median postoperative interval of only 11 months.<sup>178</sup> The atypical recurrence pattern after taTME was described as rapid and multifocal in the pelvis and along the sidewalls, and recurrence was not always associated with intraoperative technical issues. These data led to a moratorium on taTME by the Norwegian health authorities until a national audit was completed.<sup>178</sup> Controversy regarding this approach persists, given its learning curve, the concern for complications, and the lack of long-term oncologic outcomes data. A multicenter, randomized, controlled trial comparing taTME with laparoscopic TME (COLOR III) is expected to enroll 1098 patients and may provide additional insight into this technique.<sup>179</sup>

**9. Patients with an apparent complete clinical response to neoadjuvant therapy should typically be offered radical resection. A “watch and wait” management approach can be considered for highly selected patients in the context of a protocolized setting. Grade of recommendation: Strong recommendation based upon moderate-quality evidence, 1B.**

Neoadjuvant chemoradiation therapy has been associated with a pathologic complete response (pCR) rate of up to 20% or higher.<sup>180</sup> The response rate varies by the neoadjuvant regimen used and the interval between treatment completion and response assessment.<sup>181</sup> Patients who achieve pCR have no gross or microscopic residual tumor in their surgical specimens and can generally expect excellent long-term outcomes.<sup>182–184</sup> However, there is currently no reliable way to accurately identify patients with a pCR short of histologically evaluating a TME resection specimen. For this reason, radical resection is typically offered to patients after completing neoadjuvant therapy.

Response to neoadjuvant therapy can be assessed clinically and a cCR is characterized by 1) no palpable tumor on digital rectal examination, 2) no visible pathology other than a flat scar on endoscopy, and 3) no evidence of disease on cross-sectional imaging.<sup>185</sup> The need for radical resection in the setting of an apparent cCR has been called into question, in particular, if this strategy would jeopardize sphincter preservation; however, a major concern is that the correlation between cCR and pCR is poor, and confident patient selection, in terms of which patients will actually have a pCR, remains elusive.

Endoscopic assessment alone is insufficient to accurately identify cCR. In a correlation study, 70 of 93 patients (75%) with no disease identified by clinical examination and endoscopy had pathologic foci of tumor found at the time of resection.<sup>186</sup> In another series, 19 of 31 patients

with a pCR (61%) after neoadjuvant chemoradiotherapy had a residual mucosal abnormality preoperatively.<sup>187</sup> Because up to 17% of patients with no mural disease (ypT0) may still harbor lymph node metastasis, clinical and endoscopic assessment of response alone cannot reliably predict pCR or obviate the need for radical excision.<sup>188</sup> Cross-sectional imaging with CT, MRI, or PET help identify patients with a cCR.<sup>189–191</sup> Postneoadjuvant MRI can show fibrosis as low signal intensity on T2-weighted images and residual tumor as high signal intensity on diffusion-weighted images and assesses extraluminal disease.<sup>189,190</sup>

Despite concerns regarding oncologic adequacy, a “watch and wait” nonoperative approach has been explored in selected patients who achieve a cCR, given the risks of and reluctance for undergoing radical resection in the setting of a possible pCR.<sup>192–196</sup> Evidence supporting this approach includes a pooled 2-year local recurrence rate of 15.7% (95% CI, 11.8–20.1) and that salvage surgery has been feasible in 83.8% to 95.4% of patients with a recurrence.<sup>197–199</sup> Data from the International Watch & Wait Database indicate that 97% of regrowth occurring during the first 2 years was local within the bowel wall.<sup>200</sup> When “watch and wait” patients were compared to patients who underwent radical resection and were found to have pCR, no differences in OS were detected in an early meta-analysis, but a more recent retrospective study showed inferior 5-year OS (73%; 95% CI, 60%–89% versus 94%; 95% CI, 90%–99%) as well as worse DFS (75%; 95% CI, 62%–90% versus 92%; 95% CI, 87%–98%) in “watch and wait” patients.<sup>201</sup> In addition, a higher rate of distant metastasis was observed among “watch and wait” patients who had local recurrence versus those who did not (36% versus 1%,  $p < 0.001$ ).<sup>201</sup> High-quality, prospective data with longer follow-up and larger sample sizes are necessary to better evaluate the “watch and wait” approach. Therefore, a “watch and wait” management approach can be implemented after informed consent in highly selected patients who achieve a cCR in a protocolized setting with a defined follow-up regimen.

**10. In patients undergoing a TME, rectal washout may be considered. Grade of recommendation: Weak recommendation based on low-quality evidence, 2C.**

Because viable exfoliated malignant cells have been demonstrated in the lumen of patients undergoing rectal cancer resection, circular staplers used to create colorectal anastomoses may provide a mechanism by which tumor cells can implant.<sup>202</sup> A rectal washout can be undertaken before stapling to potentially reduce the burden of exfoliated cells in the rectal lumen, possibly reducing recurrence due to this mechanism. Two meta-analyses using nonrandomized data show a lower local recurrence rate associated with using rectal washout, although the comparative patient groups were not controlled for other potential confounders for local recurrence.<sup>203,204</sup>

**11. During LAR, a colonic reservoir may be considered. Grade of recommendation: Weak recommendation based on moderate-quality evidence, 2B.**

Low anterior resection syndrome with postoperative bowel dysfunction that may include urgency, clustering, and increased frequency of bowel movements, and fecal incontinence has been attributed, in part, to the loss of the reservoir function of the rectum after proctectomy.<sup>205</sup> Various surgical techniques have been developed, including colonic J-pouch, transverse colectomy, and the side-to-end (Baker) colorectal anastomosis to augment the residual reservoir after proctectomy and potentially improve postoperative function. Overall, meta-analyses have not demonstrated substantial differences among these options in terms of the risks of anastomotic leak or stricture or the need for reoperation, owing to wide, overlapping confidence intervals, and there are limited data regarding long-term functional outcomes.<sup>206,207</sup> A colonic J-pouch has been shown to reduce bowel frequency and urgency for up to 18 months postoperatively compared with a straight, end-to-end anastomosis.<sup>206–208</sup> Studies comparing colonic J-pouch to side-to-end anastomosis have shown similar outcomes, whereas evidence supporting the use of transverse colectomy is more limited.<sup>208–211</sup>

**12. During LAR, assessment of anastomotic integrity should typically be performed. Grade of recommendation: Strong recommendation based on moderate-quality evidence, 1B.**

The reported incidence of anastomotic leak after LAR ranges from 3% to 23% with the variation possibly influenced by the differences in patient populations and in surgical techniques, use of neoadjuvant radiotherapy, formation of a diverting ostomy, definition of an anastomotic leak, and use of different radiological modalities to demonstrate a leak.<sup>212,213</sup> Anastomotic leak contributes to postoperative morbidity and has been associated with decreased OS and increased local recurrence.<sup>214–217</sup>

Intraoperative maneuvers to assess an anastomosis, including leak testing, endoscopic examination, and microperfusion evaluation, facilitate immediate intervention which, in turn, may reduce subsequent leak-related complications. Options for intraoperative correction include primary suture repair, taking down the faulty anastomosis and constructing a new anastomosis, and/or creating a diversion. Performing a leak test has been associated with lower leak rates in systematic reviews of retrospective data, presumably by facilitating intraoperative correction.<sup>218,219</sup> A positive intraoperative leak test can occur in 1.5% to 24.7% of cases and is associated with a significant risk of having a subsequent clinical leak in comparison with a negative leak test (11.4% versus 4.2%,  $p < 0.001$ ).<sup>219,220</sup> Although intraoperative endoscopic evaluation of the anastomosis can detect anastomotic defects, systematic re-

views do not demonstrate a difference in the anastomotic complication rate related to performing an on-table endoscopy.<sup>219,220</sup> Intraoperative assessment using autofluorescent dyes, such as indocyanine green (ICG), can assess anastomotic perfusion. Pooled analysis of nonrandomized data showed that fluorescence imaging significantly reduced the leak rate after rectal cancer surgery (ICG group with 555 patients: 1.1% versus non-ICG group with 747 patients: 6.1%;  $p = 0.02$ ), but prospective data from randomized trials are not yet available.<sup>218,221</sup>

**13. A diverting ostomy should be considered after LAR. Grade of recommendation: Strong recommendation based on moderate-quality evidence, 1B.**

Several meta-analyses have examined the protective utility of a diverting ostomy after LAR for rectal cancer.<sup>222–227</sup> In a recent pooled analysis of randomized trials and comparative studies, a diverting ostomy reduced the rate of clinical anastomotic leak (OR = 0.43; 95% CI, 0.28–0.67) and the rate of reoperation (OR = 0.62; 95% CI, 0.40–0.94) but diverted patients risked having stoma-related morbidity (OR = 1.32; 95% CI, 1.05–1.65).<sup>225</sup> A review of 23 studies examining risk factors for anastomotic leak found that patients with a low rectal anastomosis (variably defined as within 5–8 cm of the anal verge; OR = 3.26; 95% CI, 2.31–4.62), male sex (OR = 1.48; 95% CI, 1.37–1.60), or preoperative radiotherapy (OR = 1.65; 95% CI, 1.06–2.56) may benefit the most from fecal diversion.<sup>228</sup> Loop ileostomy is generally preferred over loop colostomy because of the typical ease of reversal; however, loop ileostomy has been associated with an increased incidence of high stoma output and dehydration.<sup>226,229</sup>

**14. A management plan for the perineal defect after rectal cancer resection should typically be established preoperatively, incorporating options such as omentoplasty or reconstruction with a myocutaneous flap. Grade of recommendation: Weak recommendation based on moderate-quality evidence, 2B.**

Perineal wound complications are relatively common after primary perineal closure during APR. A meta-analysis of 32 studies including 7247 patients reported that the perineal complication rates after APR without and with neoadjuvant radiation were 15.3% (95% CI, 12.1–19.2) and 30.2% (95% CI, 19.2–44.0), and the corresponding rates after ELAPE were 14.8% (95% CI, 9.5–22.4) and 37.6% (95% CI, 18.6–61.4), whereas perineal hernia rates were 1.8% (95% CI, 0.4–8.3) and 2.0% (95% CI, 0.5–7.0) after APR and ELAPE.<sup>230</sup> An analysis of the American College of Surgeons National Surgical Quality Improvement Program database showed that patient-related factors may also contribute to the risk of perineal wound dehiscence, including ASA classification  $\geq 4$  (OR = 2.2,  $p = 0.003$ ), history of smoking (OR = 2.2,  $p < 0.001$ ), history of chronic obstructive pulmonary disease (OR = 1.7,  $p = 0.03$ ), BMI

$\geq 35$  (OR = 1.9,  $p = 0.001$ ), and surgeon-anticipated need for closure with a flap (OR = 2.9,  $p < 0.001$ ).<sup>231</sup> The authors concluded that modifying or optimizing risk factors, to the degree it is practical, may be as important as the specific perineal wound closure technique used.

Although direct comparison of flap versus primary wound closure is challenging due to selection bias and the heterogeneous nature of flaps used in practice, a systematic review of 10 studies including 566 patients (226 flaps and 340 primary closures) revealed that primary closure was associated with significantly greater likelihood of both overall (OR = 2.17; 95% CI, 1.34–3.14;  $p = 0.001$ ) and major (OR = 3.64; 95% CI, 1.43–7.79;  $p = 0.005$ ) perineal wound complications.<sup>232</sup> When omentoplasty was examined in a recent meta-analysis of 1894 patients (including 839 patients undergoing omentoplasty), omentoplasty did not significantly reduce 30-day perineal wound complications (RR = 1.0; 95% CI, 0.92–1.82) or the chronic perineal sinus rate (RR = 1.08; 95% CI, 0.53–2.20).<sup>233</sup>

**15. Oophorectomy is typically advised for grossly abnormal ovaries or contiguous extension of rectal cancer, but routine prophylactic oophorectomy is not recommended. Grade of recommendation: Strong recommendation based on low-quality evidence, 1C.**

In patients with apparent direct rectal cancer extension involving an ovary, en bloc oophorectomy should typically be performed as part of a curative-intent resection. In patients with suspected or known metastatic disease involving an ovary, oophorectomy has been associated with a survival benefit in retrospective series of selected patients.<sup>234</sup> In these situations, bilateral oophorectomy should typically be performed even if 1 ovary appears grossly normal.<sup>234–236</sup>

In patients with grossly normal-appearing ovaries, there are insufficient data to support routine prophylactic oophorectomy at the time of rectal cancer resection.<sup>237</sup> Prophylactic oophorectomy should be considered in women with rectal cancer with an inherited risk for developing ovarian cancer and in postmenopausal women desiring risk reduction. In *BRCA1* or *BRCA2* carriers, preventive oophorectomy has been associated with an 80% reduction in the risk of ovarian, fallopian tube, or peritoneal cancer and a 77% reduction in all-cause mortality.<sup>238</sup> In patients with Lynch syndrome, prophylactic hysterectomy together with bilateral salpingo-oophorectomy effectively prevents endometrial and ovarian cancer.<sup>17,239</sup>

### Tumor-Related Emergencies

**1. The management of patients with rectal cancer presenting with tumor-related emergencies should follow the principles of optimal oncologic therapy when possible, depending on the specific clinical circumstances. Grade of recommendation: Strong recommendation based on low-quality evidence, 1C.**

Emergencies related to rectal cancer typically include bleeding, obstruction, and perforation. Up to 20% of all patients with colorectal cancer present as emergencies and the management of such patients can be challenging because of competing treatment priorities and the generally higher risk of morbidity.<sup>240–242</sup> For patients presenting with synchronous metastatic disease where the disease burden warrants palliative-intent treatment, optimal management should typically involve multidisciplinary input regarding treatment options and shared decision making that considers life expectancy as well as patient wishes and priorities. The management of patients who present with obstruction or potentially resectable synchronous metastatic disease is discussed below. Among patients with nonmetastatic cancer whose disease is amenable to curative intent treatment, optimal management should typically address immediate threats to life while preserving the opportunity to pursue multimodality treatment, as indicated. Emergent resection of a locally advanced rectal cancer omitting multimodality therapy should typically be avoided because this may potentially compromise oncologic outcomes.<sup>243,244</sup>

For bleeding rectal tumors, radiation can effectively palliate 87% to 100% of patients and is considered the first-line approach; emergency resection can typically be avoided in this situation.<sup>245,246</sup> Bleeding may also be managed endoscopically, via interventional angiography or with topical therapies, but studies comparing the different approaches are lacking.<sup>247</sup>

Management of tumor-related perforation depends on the clinical presentation but the mortality related to a perforation in this setting may be as high as 65%.<sup>248</sup> Although the main priority in an operation dealing with a perforation is typically to control the septic source, resection with or without anastomosis according to oncologic principles should typically be performed. If the perforation is proximal to the tumor, an extended resection addressing both pathologies may be considered.<sup>243,248</sup>

**2. In patients with obstruction due to extraperitoneal rectal cancer, decompression with a proximal diverting stoma should be considered. Grade of recommendation: Strong recommendation based on low-quality evidence, 1C.**

Patients with acute or subacute obstructive symptoms such as tenesmus and multiple small-volume liquid stools due to a narrowed lumen should be counseled appropriately and should typically be treated expeditiously to try to prevent worsening symptoms and progression to complete obstruction and even perforation. Treatment decisions should consider disease status, prognosis, the patient's clinical condition, and available expertise.

In patients with potentially curable colon cancer, endoluminal stents have been used as a bridge to surgery, allowing for bowel decompression and, potentially,

a subsequent single-stage resection with primary anastomosis.<sup>249</sup> Although stenting proximal rectal cancer may similarly be performed as a bridge to further therapy, stenting an obstructing distal rectal cancer is typically not recommended because a stent at this level can cause chronic pain, tenesmus, and worse quality of life and can migrate.<sup>250</sup> In addition, although systematic reviews have not definitively shown an adverse impact of stenting on colorectal cancer local recurrence rates, some series have reported increased risk of local recurrence, possibly related to tissue inflammation and particularly in the setting of stent-related perforation.<sup>251,252</sup>

A proximal diverting ostomy for decompression under these circumstances usually incorporates a loop configuration to allow for distal venting.<sup>253</sup> Decompression via stoma or stenting allows for staging and appropriate multimodality therapy before resection, as indicated. The timing and method of decompression should be individualized and the anticipated response to neoadjuvant therapy should also be considered when deciding whether or not to decompress a patient with a partial obstruction.

Stenting is not typically recommended in patients in whom chemotherapy with an antiangiogenic agent (eg, bevacizumab) is being used because of an increased risk of stenting-related perforation compared with chemotherapy without an antiangiogenic agent (12.5%; 95% CI, 6.4%–22.8% versus 7.0%; 95% CI, 4.8%–10.0%).<sup>254</sup> For palliative decompression of obstructing rectal cancer in patients with terminal life expectancy or whose operative risk is prohibitive, endoluminal stenting may be a preferred option. In the palliative setting, stenting is associated with relatively high technical success rates, low mortality and morbidity rates, and relatively short hospitalization. After initial successful decompression by stenting, some patients may require reintervention such as repeat stenting or subsequent diversion.<sup>255,256</sup>

## Multimodality Therapy for Nonmetastatic Rectal Cancer

### Neoadjuvant Therapy

1. **Neoadjuvant therapy should typically be recommended for patients with clinical stage II/III rectal cancer. Grade of recommendation: Strong recommendation based on high-quality evidence, 1A.**

The most commonly utilized regimen for neoadjuvant therapy is “long-course” chemoradiotherapy (LCCRT) using conventional doses of 1.8 to 2 Gy per fraction over 5 to 6 weeks for a total dose of 45 to 50.4 Gy with concurrent 5-fluorouracil (5FU)-based chemotherapy. “Short-course” radiotherapy (SCRT) with 5 Gy daily for 5 days without chemotherapy is an alternative regimen less commonly used in the United States. Clinical scenarios where omission of pelvic radiation as a component of neoadjuvant therapy may be considered are discussed in the next section.

The Swedish Rectal Cancer trial randomly assigned 1168 patients to SCRT followed by surgery versus surgery alone, and the SCRT arm was associated with reduced local recurrence (9% versus 26%,  $p < 0.001$ ) and prolonged survival (5-year OS, 38% versus 30%;  $p = 0.008$ ) with a median follow-up of 13 years.<sup>257,258</sup> The Dutch TME trial randomly assigned 1861 patients to SCRT followed by TME surgery versus TME surgery alone, and, even in the setting of standardized TME surgery, local recurrence was significantly reduced with neoadjuvant SCRT.<sup>259</sup> At 10 years, the local recurrence rate was 11% after TME alone versus 5% after SCRT and TME ( $p < 0.001$ ), but there was no benefit in OS (49% after TME versus 48% after SCRT and TME,  $p = 0.86$ ).<sup>260</sup> The benefit of radiotherapy appeared to be the greatest among tumors with nodal involvement located 5 to 10 cm from the anal verge with negative resection margins; neoadjuvant SCRT did not offset the risk for local failure in low rectal tumors with positive resection margins.<sup>260</sup> The addition of SCRT to TME resulted in more long-term toxicity; specifically, higher rates of fecal incontinence (62% versus 38%,  $p < 0.001$ ), pad use (56% versus 33%,  $p < 0.001$ ), and mucus leakage (27% versus 15%,  $p = 0.005$ ) were reported in patients who received radiation.<sup>261</sup> Irradiated men also reported more erectile problems.<sup>261,262</sup> Posttreatment sequelae persisted even after prolonged follow-up (median 14 years) among patients undergoing SCRT and TME without a stoma. A Cochrane database meta-analysis demonstrated that patients undergoing SCRT followed by surgery was associated with reduced local recurrence rates compared with patients who underwent surgery alone but did not significantly increase sphincter-preservation rates or perioperative complication rates.<sup>263</sup>

“Long-course” chemoradiotherapy, the most common neoadjuvant regimen used in the United States, was studied in the German Rectal Cancer trial (CAO/ARO/AIO-94) which randomly assigned patients with clinical stage II/III rectal cancer ( $n = 823$ ) to either preoperative or postoperative LCCRT.<sup>264</sup> Chemoradiotherapy consisted of 5.4 Gy in 28 fractions with concurrent infusional 5FU. Standard TME was performed and all patients received an additional 4 cycles of adjuvant 5FU-based chemotherapy. The local recurrence rate was lower in the preoperative treatment group (6% versus 13%,  $p = 0.006$ ) and this benefit persisted at long-term (10-year) follow-up (7.1% versus 10%,  $p = 0.04$ ). Meanwhile, there were no significant differences in 10-year OS, DFS, or rate of distant metastasis between the groups.<sup>264</sup> Compared with postoperative therapy, preoperative LCCRT led to significantly less severe (grade 3 or 4), acute (27% versus 40%;  $p = 0.001$ ), and long-term (14% versus 24%;  $p = 0.01$ ) toxicity. The most common acute toxicities related to preoperative therapy were diarrhea and hematologic and dermatologic toxicities, whereas the most common long-term toxicities included chronic diarrhea, bowel obstruction, anastomotic

stricture, and bladder and sexual dysfunction.<sup>265</sup> Although neoadjuvant LCCRT has not consistently demonstrated a statistically significant difference in the rate of sphincter preservation in meta-analyses, chemoradiotherapy may facilitate sphincter preservation by reducing tumor volume in the deep pelvis.<sup>266</sup>

Two randomized trials that compared neoadjuvant SCRT and LCCRT and reported long-term oncologic outcomes are the Polish trial (316 patients) and the Trans-Tasman Radiation Oncology Group trial (TROG) 01.04 (326 patients).<sup>267</sup> The local recurrence, 5-year distant metastasis, and OS rates did not differ significantly between the arms in either trial. Significantly less acute toxicity was associated with SCRT than with LCCRT (3% versus 18%,  $p < 0.001$  in the Polish trial and 1.9% versus 28%,  $p < 0.001$  in the TROG trial), although the rates of high-grade late toxicity did not significantly differ in either trial.<sup>267–269</sup> Importantly, LCCRT was consistently more effective in inducing pathologic downstaging and tumor regression than SCRT. Although pooled analysis showed no difference in the rates of sphincter preservation or R0 resection, the rate of pCR was 16% after LCCRT versus only 1% after SCRT ( $p < 0.001$ ).<sup>269,270</sup>

The Stockholm III trial provided data on 385 patients with rectal cancer randomly assigned to SCRT with immediate surgery (SCRT), SCRT with delayed surgery at 4 to 8 weeks (SCRT-delay), or LCCRT with delayed surgery at 4 to 8 weeks (LCCRT-delay), as well as data on an additional 455 patients randomly assigned to SCRT or SCRT-delay.<sup>271</sup> After a median follow-up of 5.2 years, the overall local recurrence rate did not statistically differ among the 3 groups. Although there were no differences in postoperative complication rates among patients in the 3-arm randomization, pooled analysis comparing patients treated by SCRT versus SCRT-delay showed a significantly lower risk of postoperative complications after SCRT-delay (41% versus 53%; OR = 0.61; 95% CI, 0.45–0.83;  $p = 0.001$ ) and a higher rate of pCR (11.8% versus 1.7%,  $p = 0.001$ ), suggesting that SCRT-delay may provide the tumor regression more typically attributed to LCCRT.<sup>272,273</sup>

## 2. The neoadjuvant regimen should typically be tailored to the individual patient after multidisciplinary team discussion. Grade of recommendation: Strong recommendation based on high-quality evidence, 1A.

The exact components of the neoadjuvant regimen impact treatment morbidity and the degree of tumor response. In an effort to allow for a more patient-centered approach to neoadjuvant therapy, studies have investigated various neoadjuvant regimens with respect to both their toxicity and their impact on pathologic response. Because the heterogeneity of rectal cancer has been increasingly appreciated, risk stratification based on clinicopathologic factors (eg, T and N staging and histological grade) and MRI-based assessments (eg, CRM involvement) have been pro-

posed as the basis for tailoring the neoadjuvant regimen to the individual patient.<sup>52</sup>

### Extended Neoadjuvant Therapy Regimens

Adding chemotherapy concurrently to radiation provides radiosensitization and increases the pCR rate, but can also increase toxicity depending on the regimen. A Cochrane database review compared neoadjuvant radiation alone to neoadjuvant radiation with concurrent 5-FU-based chemotherapy and demonstrated that chemoradiation increased the rate of pCR (OR = 2.12–5.84;  $p < 0.001$ ) and was associated with a lower 5-year local recurrence rate (OR = 0.39–0.72;  $p < 0.001$ ), but there were no differences in the rates of sphincter preservation at 5 years.<sup>273</sup>

The impact of adding oxaliplatin concurrently to neoadjuvant 5-FU-based LCCRT was investigated in several trials that showed significantly increased toxicity.<sup>274</sup> The STAR-01 trial reported grade 3 to 4 toxicity rates of 24% versus 8% ( $p < 0.001$ ) related to adding oxaliplatin.<sup>275</sup> Similarly, in the NSABP R04 trial, grade 3 and higher toxicities were substantially more common in the oxaliplatin-containing arms than in the 5-FU/capecitabine-only arms.<sup>276</sup> In terms of oncologic outcomes related to adding oxaliplatin, a higher pCR rate was only observed in oxaliplatin-containing regimens in the German study (17% versus 13%,  $p = 0.03$ ) and the FOWARC trial (27.5% versus 14%,  $p = 0.005$ ).<sup>277,278</sup> Taken together, the toxicities associated with adding oxaliplatin to 5-FU-based LCCRT outweigh the oncologic benefits. Similarly, adding targeted agents such as vascular endothelial growth factor or epidermal growth factor receptor inhibitors concurrently to LCCRT has been tested in several small, phase II trials without demonstrating significant improvements in pCR rates.<sup>278</sup>

Adding chemotherapy sequentially to 5FU-based LCCRT is another neoadjuvant strategy that was developed with the goal of theoretically addressing micrometastases earlier than the adjuvant setting. Total neoadjuvant therapy (TNT) most commonly refers to induction systemic chemotherapy followed by LCCRT; alternatively, it can involve LCCRT followed by consolidation systemic chemotherapy. The total duration of TNT treatment should not, in general, exceed 6 months.<sup>52</sup>

Induction chemotherapy followed by LCCRT has been evaluated in phase II clinical trials that enrolled patients with poor-risk disease characterized by low-lying, cT4 or cN2 rectal cancer or a threatened CRM as seen on MRI and most commonly utilizes FOLFOX or CAPOX for 8 cycles. Although some trials have reported encouragingly high pCR rates (24% in EXPERT and 29% in CONTRE)<sup>279</sup> others have not (14.3% in Spanish GCR-3).<sup>280,281</sup> “Long-course” chemoradiotherapy followed by consolidation FOLFOX chemotherapy was evaluated in a randomized, phase II trial that showed that adding increasing cycles of FOLFOX (0, 2, 4, and 6) significantly improved pCR rates (20%, 23%, 26%, and 37%;  $p = 0.04$ ) and DFS (50%, 81%,

86%, and 76%;  $p = 0.004$ ).<sup>282</sup> The main advantage of the TNT sequence may be the ability to deliver all planned systemic therapy to a greater proportion of patients, but comparative data regarding long-term toxicity and survival rates are limited.<sup>283</sup>

The sequential administration of systemic chemotherapy and LCCRT has made it possible to consider more selective use of radiotherapy after induction systemic chemotherapy. In a small, phase II pilot trial, 32 patients received neoadjuvant chemotherapy (FOLFOX with bevacizumab), but only those with stable or progressive disease went on to receive LCCRT before undergoing TME.<sup>284</sup> All patients had an R0 resection, and the pCR rate after chemotherapy alone was 25% (95% CI, 11%–43%), and the 4-year DFS was 84% (95% CI, 67%–94%). A randomized, phase III trial to further investigate the selective use of neoadjuvant chemoradiotherapy, the Preoperative Radiation or Selective Preoperative Radiation and Evaluation Before Chemotherapy and TME (PROSPECT), is currently ongoing.<sup>285</sup>

### **Moderated Neoadjuvant Therapy Regimens**

Selectively omitting pelvic radiation as a component of neoadjuvant therapy has been proposed for patients with relatively favorable prognostic factors including early T3 tumors with minimal invasion into the perirectal fat, tumors in the upper rectum, and tumors with wide CRM clearance on MRI.<sup>286,287</sup> Single institutional studies have reported that T3N0 tumors that are well differentiated, with minimal (< 2 mm) invasion into perirectal fat and without lymphovascular invasion, could be treated without radiation with a 10-year local control rate of 95%.<sup>288</sup> A pair of pooled analyses from 2002 and 2004 of North American randomized, controlled trials where patients with rectal cancer did or did not receive adjuvant chemotherapy and/or radiation highlighted the heterogeneity among patients with stage II and III rectal cancer, and, based on risks for disease relapse and death, T3N0 and T1-2N1 tumors were described as “intermediate risk,” given their lower risk for local recurrence compared with moderately high- and high-risk groups.<sup>289,290</sup> However, further studies have highlighted that T3N0 rectal tumors within 5 cm of the anal verge have a higher risk of local recurrence when treated with surgery alone<sup>291</sup> and that there is a substantial (22%) risk for clinical staging to underdetect nodal disease.<sup>292</sup> Although omitting neoadjuvant radiation can be considered in selected T3N0 patients, this approach requires accurate clinical staging and should typically be avoided in the low rectum.

Additional evidence supporting the practice of selectively omitting radiotherapy in treating rectal cancer includes a subgroup analysis of the long-term data from the Dutch TME trial that showed adding preoperative radiation was not associated with significant improvement in the local recurrence risk after TME surgery when tumors

were more than 10 cm from the anal verge (5-year local recurrence: 6.2% versus 3.7%,  $p = 0.12$ ) or did not have positive nodes (5-year local recurrence in TNM stage II: 5.3% versus 7.2%,  $p = 0.33$ ).<sup>293</sup> However, the authors cautioned that data from subgroup analyses highlight heterogeneity in the risk of recurrence, but should not be used as a sole criterion to determine radiation use.<sup>293</sup> A recent meta-analysis of 5 studies that compared patients with upper versus lower rectal cancers treated with upfront surgery found that upper rectal cancers were associated with lower rates of local (OR = 0.50; 95% CI, 0.30–0.81;  $p = 0.005$ ) and distant (OR = 0.61; 95% CI, 0.51–0.73;  $p < 0.001$ ) failure.<sup>294</sup> Finally, in the MERCURY trial, baseline MRI stratified patients with rectal cancer according to prognosis where patients with a good prognosis were characterized by MRI-predicted clear CRM (tumor >1 mm from the mesorectal fascia), no extramural venous invasion, and spread <5 mm from the bowel wall. Following a policy of omitting neoadjuvant chemoradiation for patients with a good prognosis, the study reported a 5-year local recurrence risk of 3.3%, 5-year DFS of 84.7% (95% CI, 76.0%–90.4%) and OS of 68.2% (95% CI, 60.3%–77.0%).<sup>295</sup> After long-term follow-up, MRI-predicted CRM clearance was the only independent predictor of local recurrence irrespective of cTNM staging (HR = 3.5; 95% CI, 1.53–8.00;  $p < 0.05$ ) suggesting that a policy of selective radiation based on MRI-predicted CRM was feasible.<sup>54</sup> Recently, the QuickSilver trial conducted in Canada replicated these findings, supporting the feasibility of using MRI criteria to select patients for upfront resection without radiation.<sup>296</sup>

### **3. Pathologic response to neoadjuvant therapy should be evaluated at the time of radical resection. Grade of recommendation: Strong recommendation based on moderate-quality evidence, 1B.**

Assessment of the clinical response to neoadjuvant therapy prior to surgical resection was discussed in Staging. Pathologic response to neoadjuvant therapy should be assessed as a routine part of pathology evaluation at the time of resection, because the degree of tumor response to neoadjuvant therapy is prognostic of long-term outcomes. A pCR after neoadjuvant therapy is associated with excellent long-term oncologic outcomes with local failure rates as low as 0.7% (range, 0%–2.6%) and 5-year OS and DFS rates as high as 90.2% and 87%.<sup>182,183,297</sup> Although there is currently no universally accepted tumor regression grading (TRG) system to document the response to neoadjuvant therapy, available systems include the Mandard 5-tier system (TRG 1–5), the Dowrak and Rödel adapted 5-tier system (TRG 0–4 that incorporates the percentage of tumor fibrosis), a reduced 3-tier system (TRG 1–3 that ranges from complete regression to no regression), and the American Joint Committee on Cancer (AJCC) 4-tier system (TRG 0–3 that ranges from no residual tumor to minimal response).<sup>298</sup> When compared with each other,



these systems were prognostic for recurrence-free survival, but the AJCC system performed slightly better.<sup>298</sup>

The interval between neoadjuvant LCCRT and surgery influences the degree of pathologic response and the timing of surgery in this setting remains controversial.<sup>299</sup> An interval of  $\geq 8$  weeks is associated with a higher pCR rate (RR = 1.25; 95% CI, 1.16–1.35;  $p < 0.001$ ) in comparison with an interval of  $< 8$  weeks, but does not significantly influence operative time, complications, local recurrence, DFS, or OS.<sup>300,301</sup> Meta-analyses have shown that downstaging and pCR rates peak about 6 to 7 weeks after completing either SCRT or LCCRT, and that waiting beyond 11 weeks may not result in additional downstaging and may be associated with increased postoperative morbidity.<sup>300–302</sup> The optimal interval associated with emerging neoadjuvant regimens other than LCCRT remains to be established.

### Adjuvant Therapy

**1. Adjuvant chemotherapy should typically be recommended for patients with clinical or pathologic stage II or III rectal cancer if systemic chemotherapy has not been given preoperatively and it should typically begin within 8 weeks of radical resection. Grade of recommendation: Strong recommendation based on moderate-quality evidence, 1B.**

For patients with pathologic stage II or III rectal cancer who have not been treated with upfront systemic chemotherapy, FOLFOX is an approved adjuvant therapy.<sup>52</sup> This recommendation is based on extrapolation of data from adjuvant colon cancer therapy because there is a paucity of data specifically for rectal cancer. In the MOSAIC and NSABP C-07 trials, the addition of oxaliplatin to 5-FU/leucovorin adjuvant therapy (FOLFOX regimen) significantly improved OS and DFS for stage II/III colon cancer compared with 5-FU alone.<sup>303,304</sup> Options for adjuvant therapy for colon cancer other than observation include 5-FU-based regimens with or without oxaliplatin for pathologic low-risk stage II (pT3N0), high-risk stage II (pT3N0 with poor differentiation, lymphovascular or perineural invasion, inadequate margin, fewer than 12 nodes harvested, obstruction or perforation, pT4N0), and stage III disease. In the absence of rectal cancer-specific data, a similar approach may be undertaken for patients who have rectal cancer with pathologic stage II or III disease who have not received neoadjuvant therapy.<sup>52</sup>

For patients with clinical stage II or III rectal cancer who were treated with neoadjuvant chemoradiation therapy, adjuvant chemotherapy is typically recommended regardless of the final pathologic (yp) stage.<sup>305</sup> However, the benefit of additional chemotherapy following preoperative chemoradiation is not uniform for all patients with rectal cancer, and the subgroups of patients who would likely benefit the most from this additional therapy have

not been definitively identified, leading to variations in clinical practice.<sup>269,305</sup> The ADORE trial randomly assigned patients with rectal cancer ( $n = 321$ ) treated with neoadjuvant LCCRT and surgery to adjuvant FOLFOX versus 5-FU therapy and the FOLFOX arm had higher 3-year DFS (71.6% versus 62.9%; HR = 0.66; 95% CI, 0.43–0.99;  $p = 0.04$ ).<sup>306</sup> In meta-analyses including randomized and nonrandomized data, oxaliplatin-containing adjuvant chemotherapy was associated with statistically significant improvement in DFS (HR = 0.7–0.85) compared with 5-FU-based regimens, but the OS benefit from oxaliplatin was inconsistent and appeared to be most significant among patients whose tumors were downstaged after neoadjuvant therapy.<sup>307–309</sup> The National Comprehensive Cancer Network recommends oxaliplatin-containing 5-FU regimens as the preferred regimens and consideration of possibly omitting oxaliplatin in patients whose initial clinical stage was cT3N0.<sup>52</sup>

Adjuvant chemotherapy is typically recommended even for the subgroup of patients with a ypCR.<sup>310–312</sup> A meta-analysis examining 2948 patients with rectal cancer with a ypCR (adjuvant group = 1324 patients; no-adjuvant group = 1624 patients) showed a significant improvement in OS after adjuvant therapy compared with observation (HR = 0.65; 95% CI, 0.46–0.90,  $p = 0.01$ ). In particular, these data support that patients with clinical node-positive disease (stage III) who went on to have a ypCR might benefit more from adjuvant chemotherapy.<sup>311</sup>

Several studies have demonstrated that the time interval between resection and initiating adjuvant chemotherapy impacts the survival benefit of the therapy. A meta-analysis of 6 studies across 12,584 patients showed that every 4-week increase in the time to adjuvant therapy was associated with a decrease in both OS (HR = 1.14; 95% CI, 1.10–1.17) and DFS (HR = 1.14; 95% CI, 1.10–1.18).<sup>313</sup> The most significant risk factors for delaying adjuvant therapy include prolonged postoperative stay (OR = 2.37; 95% CI, 2.10–2.68) and readmission (OR = 3.23; 95% CI, 1.66–6.26), and other relevant risk factors include age  $> 75$  years (OR = 1.44; 95% CI, 1.32–1.58), single marital status (OR = 1.32; 95% CI, 1.20–1.44), low socioeconomic status (OR = 1.67; 95% CI, 1.32–2.12), comorbidities (OR = 1.47; 95% CI, 1.14–1.90), and low-grade tumor (OR = 1.06; 95% CI, 1.02–1.11), whereas a minimally invasive approach facilitated earlier adjuvant initiation (OR = 0.70; 95% CI, 0.51–0.97).<sup>313–320</sup>

The recommended duration of adjuvant treatment for patients with rectal cancer remains controversial. In patients with rectal cancer who were already treated with preoperative LCCRT, an 8-cycle (4 month) course of adjuvant FOLFOX is generally accepted.<sup>52</sup> A pooled analysis from the IDEA collaboration questioned the feasibility of risk stratifying the duration of adjuvant FOLFOX in patients with colon cancer.<sup>321</sup> Motivated by the potential for reducing treatment toxicity without decreasing DFS,

3 months of adjuvant FOLFOX is being considered for patients with low-risk stage III colon cancer, whereas 6 months remains standard for patients with higher-risk tumors.<sup>322</sup> However, the impact, if any, of these data on the duration of adjuvant chemotherapy for patients with rectal cancer is unclear.<sup>323</sup>

**2. Adjuvant radiotherapy should typically be considered in selected patients with high-risk, pathologic stage II or III rectal cancer, in particular, if neoadjuvant therapy has not been given. Grade of recommendation: Strong recommendation based on moderate-quality evidence, 1B.**

In patients whose disease was understaged clinically and/or who did not receive neoadjuvant therapy for other reasons, postoperative LCCRT may be selectively considered in patients with high-risk pathologic stage II or III rectal cancer, characterized by close ( $\leq 1$  mm) CRM, T4 disease, intraoperative tumor perforation, or N1c/N2 disease.<sup>52</sup> However, postoperative LCCRT likely cannot fully compensate for the increased oncologic risks associated with a positive CRM.<sup>324,325</sup> In the MRC CR07/NCIC-CTG C016 randomized trial, 676 patients underwent TME followed by postoperative LCCRT only when the CRM was positive.<sup>326</sup> When compared to 674 patients treated with neoadjuvant chemoradiation and TME, patients treated with postoperative LCCRT had a higher 3-year local recurrence rate (10.6% versus 4.4%,  $p = 0.01$ ) and worse 3-year DFS (71.5% versus 77.5%,  $p = 0.04$ ). In the setting of TME with R0 margins, data showing an additional benefit of postoperative LCCRT is lacking. The use of LCCRT in the adjuvant setting is associated with several disadvantages including increased overall toxicity; higher risk of injuring bowel in the radiation field; potentially decreased efficacy due to a more radioresistant, hypoxic postsurgical bed; and perineal wound complications.<sup>324</sup>

**Multimodality Therapy for Rectal Cancer With Synchronous Metastatic Disease**

**1. Multidisciplinary assessment of patients with rectal cancer with synchronous metastases should establish the treatment intent as potentially curative or palliative. Grade of recommendation: Strong recommendation based upon moderate-quality evidence, 1B.**

Synchronous metastases have been defined as those detected before, at, or within 3 to 6 months after the diagnosis of a primary rectal cancer.<sup>67</sup> Clinical staging, as discussed previously, should define the extent of both local and distant disease and serves as the basis for treatment planning.

Systemic chemotherapy is the mainstay treatment for patients with rectal cancer with metastatic disease, and multidrug regimens typically include targeted agents potentially tailored to the cancer's somatic mutation profile. With significant advances in available systemic treatments, the median OS of patients with stage IV colorectal cancer

improved to 24 to 36 months over the past decades.<sup>327</sup> A subset of patients with stage IV rectal cancer may be considered for multimodality therapy with potentially curative intent. These are typically highly selected patients with limited metastatic disease or whose cancer demonstrated a favorable response to systemic chemotherapy and was confined to organs such as the liver, lung, and peritoneum where the role for metastasectomy has been established.<sup>52</sup> Arbitrating whether a patient may be a candidate for a potentially curative-intent approach and determining the optimal first-line treatment require a personalized assessment by a multidisciplinary team.<sup>328–330</sup> Key considerations include overall disease biology, patients' symptoms and physiology, technical feasibility for resecting the disease burden, organ functional reserve, and the balance between therapy aimed at metastatic disease versus primary disease. A multidisciplinary team approach has been associated with improved survival outcomes for patients with stage IV colorectal cancer.<sup>328–330</sup>

**2. In patients with symptomatic rectal cancer and unresectable metastatic disease, palliative intervention should typically be considered. Grade of recommendation: Strong recommendation based on low-quality evidence, 1C.**

Patients who have rectal cancer with an unresectable metastatic burden should ideally be assessed early and serially to determine if palliative intervention is needed. The decision to delay or interrupt systemic therapy to surgically palliate symptoms should typically be jointly made by the patient, the medical oncologist, and the surgeon.<sup>331</sup> Factors to consider when choosing a palliative intervention may include the overall prognosis and metastatic burden, the morbidity rate, as well as the efficacy of the intervention, and the magnitude of the intervention in relation to the anticipated expediency of starting or resuming oncologic therapy (return to intended oncologic treatment).<sup>332</sup> Bleeding, perforation, and obstruction related to rectal cancer were reviewed earlier in this guideline.

**3. In patients with asymptomatic rectal cancer and unresectable metastatic disease, chemotherapy is typically considered first-line therapy because the upfront resection of rectal cancer is usually not recommended under these circumstances. Grade of recommendation: Strong recommendation based on moderate-quality evidence, 1B.**

In the setting of colorectal cancer with unresectable metastatic disease, the role of resecting the primary tumor has been considered to potentially prevent future tumor-related complications and to possibly confer a survival benefit.<sup>52,67</sup> Unfortunately, much of the literature on this topic groups patients under the heading of colorectal cancer and does not specifically address patients with rectal cancer. Retrospective studies that have suggested a survival benefit in this setting typically did not distinguish whether

or not the resected primary tumor was symptomatic and were likely subject to selection bias, with resection being performed in patients with better performance status and prognosis.<sup>333</sup> A retrospective analysis of pooled data from 4 metastatic colorectal cancer trials identified 478 patients who had undergone primary tumor resection and 332 patients who did not. The median OS was 19.2 months (95% CI, 18.2–20.4) versus 13.3 months (95% CI, 12.0–14.8) favoring the resection group ( $p < 0.001$ ).<sup>334</sup> Another meta-analysis showed that resection of the primary tumor was associated with a survival advantage of 6.4 months (95% CI, 5.03–7.86;  $p < 0.001$ ) compared with chemotherapy. In this study, the resection group included more patients with limited metastases (eg, liver-only disease with less than 3 lesions) and nonrectal primary tumors, highlighting an underlying selection bias.<sup>325</sup>

Available data specifically focusing on patients who had stage IV disease with asymptomatic primary tumors do not support routine upfront resection. A Cochrane review of asymptomatic patients compared 722 patients who underwent primary colorectal cancer resection to 364 patients who did not and found no survival advantage (median survival ranged from 14 to 23 months versus 8 to 22 months).<sup>335</sup> In addition, the complication rates after either resection or chemotherapy as first-line treatment did not significantly differ.<sup>335</sup>

In general, among patients with metastatic colorectal cancer treated with systemic therapy, the risk of an asymptomatic primary tumor becoming symptomatic and requiring emergency intervention is low. Among 233 patients with colorectal cancer with metastatic disease, complications related to the primary tumor occurred in 11% and operative intervention (ie, diversion, bypass, or resection) was required in only 7%.<sup>336</sup> Having a rectal primary tumor did not confer higher risks for either operative or overall intervention than a colon primary tumor.<sup>336</sup> These findings corroborate data from the NSAPB C-10 trial that followed 90 patients with metastatic colon cancer and found that the morbidity rate related to the primary tumor was 16.3% and that operative intervention was required in only 11.1% of the patients.<sup>337</sup> A recent Surveillance, Epidemiology, and End Results Program (SEER)-Medicare database analysis reported a similar rate of 12% for otherwise unplanned operative intervention in the setting of stage IV colorectal cancer with an intact primary tumor.<sup>338</sup>

Although international, prospective trials investigating the role of primary tumor resection in the setting of unresectable metastatic disease are ongoing, routine upfront resection of an asymptomatic rectal primary tumor is not typically recommended, especially given the consequent delay in systemic chemotherapy in the context of the low potential for future complications from an intact primary tumor as well as the uncertain survival advantage related to proctectomy, and the established risk for perioperative morbidity under these circumstances.<sup>52,68,325</sup>

**4. In patients with rectal cancer and synchronous resectable (or potentially resectable) metastatic disease, individualized treatment should typically coordinate curative-intent therapies addressing all sites of disease. Grade of recommendation: Strong recommendation based upon moderate-quality evidence, 1B.**

Patients with synchronous resectable or potentially resectable metastatic disease may be considered for curative-intent therapy after multidisciplinary assessment. An individualized plan is needed to determine and optimally sequence the multimodality components of treatment. The management of patients with synchronous liver metastases, the most commonly encountered clinical scenario, will be reviewed, but the management of synchronous pulmonary and peritoneal metastases are beyond the scope of this guideline.<sup>68,339–343</sup>

Although preoperative systemic chemotherapy has been advocated as a means of assessing disease biology and minimizing the risk of relapse, its benefit in improving OS remains unclear.<sup>342</sup> For patients with initially resectable synchronous liver metastases, the EORTC 40983 trial showed that receiving perioperative systemic chemotherapy (ie, 12 total cycles of FOLFOX divided pre- and postoperatively) compared with no perioperative chemotherapy was associated with superior progression-free survival with 3-year progression-free survival of 39% (95% CI, 31.7–46.3) versus 29.9% (95% CI, 23.2%–36.9%;  $p = 0.03$ ); although, there was no statistically significant difference in OS.<sup>344</sup> For selected patients with initially unresectable synchronous metastases, systemic chemotherapy offers the opportunity to convert to potential resectability. Under these circumstances, the efficacy of chemotherapy may be as high as 30% to 40% and may be increased further with the addition of anti-vascular endothelial growth factor/epidermal growth factor receptor agents.<sup>345</sup> Given the toxicities of chemotherapeutic agents and the variable clinical course of these patients, patients should typically be reassessed every 2 to 3 months, and preoperative therapy should typically be limited to 6 to 8 cycles among resectable patients.<sup>346–348</sup>

Completing curative-intent resection of all disease with minimal morbidity and resuming systemic oncologic therapy are key priorities when individualizing treatment.<sup>349</sup> The 3 available treatment options include “classic” (primary rectal cancer is treated before the metastatic sites), “combined” or “synchronous” (all disease sites are addressed together), and “reversed” (metastatic disease is resected before the primary tumor).<sup>350,351</sup>

The “combined” approach is suitable for patients with an appropriate risk profile whose overall disease burden is amenable to a relatively safe, 1-stage operation. The efficiency of this synchronous approach in terms of postoperative recovery, convenience, and economics needs to be weighed against the potential for increased perioperative

morbidity.<sup>350–352</sup> Typical scenarios that favor a combined approach may include nonmajor hepatic resections, upper rectal tumors, or nonrestorative proctectomy.<sup>350,353</sup>

The “classic” and “reversed” approaches allow for staged treatment of the metastatic disease and the rectum and are generally favored when the management of either or both disease sites is relatively complex. The “reversed” approach, typically considered in patients whose primary rectal cancer is asymptomatic, has been utilized when hepatic metastatic disease requires a major hepatectomy or a 2-stage hepatectomy or when the primary disease requires ultralow, extended, or multivisceral resection.<sup>350,353</sup> The proposed rationale for this approach is to utilize an early window to intervene on a relatively significant burden of metastatic disease while avoiding the competing time otherwise spent on pelvis-directed neoadjuvant therapy and the risks of complications related to pelvic surgery.<sup>350,354</sup> The “classic” approach, less commonly utilized today, is generally considered when the primary rectal cancer is symptomatic and requires upfront treatment, but the extent or complexity of metastatic disease precludes a safe combined approach.<sup>67,350</sup>

The use of pelvic radiation in the setting of rectal cancer with synchronous hepatic metastases should be individualized. Because pelvic radiation can interfere with treating systemic disease, radiation use in the metastatic setting requires judicious consideration.<sup>354,355</sup> In these cases, omitting radiation for patients whose tumor is located in the upper rectum or demonstrates wide CRM clearance on imaging, as discussed earlier, or using short-course radiotherapy should typically be considered.<sup>286,356</sup>

## DOCUMENTATION

**1. The operative report should typically contain information regarding the diagnostic workup, intraoperative findings, and technical details of the procedure. Grade of recommendation: Strong recommendation based on low-quality evidence, 1C.**

The operative report should typically include preoperative details like histological diagnosis, clinical stage, distance of the tumor to the anal verge, confirmation that an ostomy site was marked preoperatively, and preoperative treatment. Relevant intraoperative factors should typically document incision type, an exploration for extrarectal disease, tumor location, adjacent organ involvement, extent of bowel resection, completeness of mesenteric excision, anastomotic technique, height, and leak test, if applicable, details of en bloc resection of involved organs, and an intraoperative assessment of the completeness of resection.<sup>10</sup> Intraoperative adverse events like tumor perforation should be documented because of its association with local recurrence and reduced 5-year survival.<sup>120,121</sup>

A number of tools are available to aide in the management of patients with rectal cancer. For example, the ASCRS developed The Rectal Cancer Surgery Checklist composed of 25 elements relevant to the pre-, intra-, and postoperative care of patients with rectal cancer. This tool was intended to serve as a comprehensive guide to enhance safety and quality of care for patients with rectal cancer undergoing surgery.<sup>357</sup> In addition, the American College of Surgeons Commission on Cancer National Accreditation Program for Rectal Cancer program requires the use of a synoptic surgical report and developed a list of 20 required elements for the report.<sup>4</sup> Utilization of a synoptic report standardizes reporting, enhances documentation compliance by including required elements, and facilitates timely communication with the multidisciplinary team to potentially improve surgical outcomes and care.<sup>358,359</sup>

**2. Accurate, detailed, and consistent rectal cancer pathology reporting is integral to determining prognosis, facilitating treatment planning, and improving quality assessment. Grade of recommendation: Strong recommendation based on low-quality evidence, 1C.**

Pathologists play a key role for patients with rectal cancer by confirming the histological diagnosis, determining tumor stage, grading the quality of the mesorectal excision, and assessing margin status and response to preoperative therapy. The College of American Pathologists rectal cancer guidelines are contained in the Protocol for the Examination of Specimens from Patients with Primary Carcinoma of the Colon and Rectum.<sup>360</sup> Documenting the required elements of pathologic assessment and using a synoptic format improve the completeness of reporting regardless of pathologists’ subspecialty interest.<sup>360,361</sup> In addition, photographs of the surgical specimen, including anterior, posterior, and lateral views, can display the integrity of the mesorectum which correlates with oncologic outcomes.

## REFERENCES

1. Cancer Facts & Figures 2019. Available at: <https://www.cancer.org/research/cancer-facts-statistics/all-cancer-facts-figures/cancer-facts-figures-2019.htm>. Accessed May 15, 2019.
2. Edwards BK, Ward E, Kohler BA, et al. Annual report to the nation on the status of cancer, 1975-2006, featuring colorectal cancer trends and impact of interventions (risk factors, screening, and treatment) to reduce future rates. *Cancer*. 2010;116:544–573.
3. Lee L, Dietz DW, Fleming FJ, et al. Accreditation readiness in US multidisciplinary rectal cancer care: a survey of OSTRICH member institutions. *JAMA Surg*. 2018;153:388–390.
4. The National Accreditation Program for Rectal Cancer. <https://www.facs.org/quality-programs/cancer/naprc> Accessed May 15, 2019.
5. Migaly J, Bafford AC, Francone TD, et al; Clinical Practice Guidelines Committee of the American Society of Colon and

- Rectal Surgeons. The American Society of Colon and Rectal Surgeons Clinical Practice Guidelines for the Use of Bowel Preparation in Elective Colon and Rectal Surgery. *Dis Colon Rectum*. 2019;62:3–8.
6. Carmichael JC, Keller DS, Baldini G, et al. Clinical Practice Guidelines for Enhanced Recovery After Colon and Rectal Surgery From the American Society of Colon and Rectal Surgeons and Society of American Gastrointestinal and Endoscopic Surgeons. *Dis Colon Rectum*. 2017;60:761–784.
  7. Fleming F, Gaertner W, Ternent CA, et al. The American Society of Colon and Rectal Surgeons Clinical Practice Guideline for the Prevention of Venous Thromboembolic Disease in Colorectal Surgery. *Dis Colon Rectum*. 2018;61:14–20.
  8. Steele SR, Chang GJ, Hendren S, et al; Clinical Practice Guidelines Committee of the American Society of Colon and Rectal Surgeons. Practice Guideline for the Surveillance of Patients After Curative Treatment of Colon and Rectal Cancer. *Dis Colon Rectum*. 2015;58:713–725.
  9. American Cancer Society updates its colorectal cancer screening guideline: new recommendation is to start screening at age 45 years. *Cancer*. 2018;124:3631–3632.
  10. Monson JR, Weiser MR, Buie WD, et al; Standards Practice Task Force of the American Society of Colon and Rectal Surgeons. Practice parameters for the management of rectal cancer (revised). *Dis Colon Rectum*. 2013;56:535–550.
  11. Wasserman MA, McGee MF, Helenowski IB, Halverson AL, Boller AM, Stryker SJ. The anthropometric definition of the rectum is highly variable. *Int J Colorectal Dis*. 2016;31:189–195.
  12. D'Souza N, de Neree Tot Babberich MPM, d'Hoore A, et al. Definition of the rectum: an international, expert-based Delphi Consensus. *Ann Surg*. 2019;270:955–959.
  13. Cohen ME, Bilimoria KY, Ko CY, Hall BL. Development of an American College of Surgeons National Surgery Quality Improvement Program: morbidity and mortality risk calculator for colorectal surgery. *J Am Coll Surg*. 2009;208:1009–1016.
  14. Lee TH, Marcantonio ER, Mangione CM, et al. Derivation and prospective validation of a simple index for prediction of cardiac risk of major noncardiac surgery. *Circulation*. 1999;100:1043–1049.
  15. Senagore AJ, Warmuth AJ, Delaney CP, Tekkis PP, Fazio VW. POSSUM, p-POSSUM, and Cr-POSSUM: implementation issues in a United States health care system for prediction of outcome for colon cancer resection. *Dis Colon Rectum*. 2004;47:1435–1441.
  16. Lu KH, Wood ME, Daniels M, et al; American Society of Clinical Oncology. American Society of Clinical Oncology Expert Statement: collection and use of a cancer family history for oncology providers. *J Clin Oncol*. 2014;32:833–840.
  17. Herzig DO, Buie WD, Weiser MR, et al. Clinical Practice Guidelines for the Surgical Treatment of Patients With Lynch Syndrome. *Dis Colon Rectum*. 2017;60:137–143.
  18. Herzig D, Hardiman K, Weiser M, et al. The American Society of Colon and Rectal Surgeons Clinical Practice Guidelines for the Management of Inherited Polyposis Syndromes. *Dis Colon Rectum*. 2017;60:881–894.
  19. Tarantino I, Warschkow R, Worni M, et al. Elevated preoperative CEA is associated with worse survival in stage I–III rectal cancer patients. *Br J Cancer*. 2012;107:266–274.
  20. Chung MJ, Nam TK, Jeong JU, et al. Can serum dynamics of carcinoembryonic antigen level during neoadjuvant chemoradiotherapy in rectal cancer predict tumor response and recurrence? A multi-institutional retrospective study. *Int J Colorectal Dis*. 2016;31:1595–1601.
  21. Gash KJ, Baser O, Kiran RP. Factors associated with degree of tumour response to neo-adjuvant radiotherapy in rectal cancer and subsequent corresponding outcomes. *Eur J Surg Oncol*. 2017;43:2052–2059.
  22. Lee JH, Kim DY, Kim SH, et al. Carcinoembryonic antigen has prognostic value for tumor downstaging and recurrence in rectal cancer after preoperative chemoradiotherapy and curative surgery: a multi-institutional and case-matched control study of KROG 14-12. *Radiother Oncol*. 2015;116:202–208.
  23. Probst CP, Becerra AZ, Aquina CT, et al. Watch and Wait?–Elevated pretreatment CEA is associated with decreased pathological complete response in rectal cancer. *J Gastrointest Surg*. 2016;20:43–52.
  24. Locker GY, Hamilton S, Harris J, et al; ASCO. ASCO 2006 update of recommendations for the use of tumor markers in gastrointestinal cancer. *J Clin Oncol*. 2006;24:5313–5327.
  25. Acuna SA, Elmi M, Shah PS, Coburn NG, Quereshey FA. Preoperative localization of colorectal cancer: a systematic review and meta-analysis. *Surg Endosc*. 2017;31:2366–2379.
  26. Kirchoff DD, Hang JH, Cekic V, et al. Endoscopic tattooing to mark distal margin for low anterior rectal and select sigmoid resections. *Surg Innov*. 2014;21:376–380.
  27. Cipe G, Cengiz MB, Idiz UO, et al. The effects of preoperative endoscopic tattooing on distal surgical margin and ileostomy rates in laparoscopic rectal cancer surgery: a prospective randomized study. *Surg Laparosc Endosc Percutan Tech*. 2016;26:301–303.
  28. Okada K, Sadahiro S, Ogimi T, et al. Tattooing improves the detection of small lymph nodes and increases the number of retrieved lymph nodes in patients with rectal cancer who receive preoperative chemoradiotherapy: A randomized controlled clinical trial. *Am J Surg*. 2018;215:563–569.
  29. Trakarnsanga A, Akaraviputh T. Endoscopic tattooing of colorectal lesions: is it a risk-free procedure? *World J Gastrointest Endosc*. 2011;3:256–260.
  30. Hangge PT, Calderon E, Habermann EB, Glasgow AE, Mishra N. Primary colorectal lymphoma: institutional experience and review of a national database. *Dis Colon Rectum*. 2019;62:1167–1176.
  31. Adloff M, Arnaud JP, Bergamaschi R, Schloegel M. Synchronous carcinoma of the colon and rectum: prognostic and therapeutic implications. *Am J Surg*. 1989;157:299–302.
  32. Barillari P, Ramacciato G, De Angelis R, et al. Effect of preoperative colonoscopy on the incidence of synchronous and metachronous neoplasms. *Acta Chir Scand*. 1990;156:163–166.
  33. Bat L, Neumann G, Shemesh E. The association of synchronous neoplasms with occluding colorectal cancer. *Dis Colon Rectum*. 1985;28:149–151.
  34. Isler JT, Brown PC, Lewis FG, Billingham RP. The role of preoperative colonoscopy in colorectal cancer. *Dis Colon Rectum*. 1987;30:435–439.
  35. Neilson LJ, Rutter MD, Saunders BP, Plumb A, Rees CJ. Assessment and management of the malignant colorectal polyp. *Frontline Gastroenterol*. 2015;6:117–126.
  36. Rex DK, Shaikat A, Wallace MB. Optimal management of malignant polyps, from endoscopic assessment and resection to decisions about surgery. *Clin Gastroenterol Hepatol*. 2019;17:1428–1437.

37. Fenlon HM, McAneny DB, Nunes DP, Clarke PD, Ferrucci JT. Occlusive colon carcinoma: virtual colonoscopy in the preoperative evaluation of the proximal colon. *Radiology*. 1999;210:423–428.
38. Macari M, Berman P, Dicker M, Milano A, Megibow AJ. Usefulness of CT colonography in patients with incomplete colonoscopy. *AJR Am J Roentgenol*. 1999;173:561–564.
39. Neri E, Giusti P, Battolla L, et al. Colorectal cancer: role of CT colonography in preoperative evaluation after incomplete colonoscopy. *Radiology*. 2002;223:615–619.
40. Sun L, Wu H, Guan YS. Colonography by CT, MRI and PET/CT combined with conventional colonoscopy in colorectal cancer screening and staging. *World J Gastroenterol*. 2008;14:853–863.
41. Halligan S, Dadswell E, Wooldrage K, et al. Computed tomographic colonography compared with colonoscopy or barium enema for diagnosis of colorectal cancer in older symptomatic patients: two multicentre randomised trials with economic evaluation (the SIGGAR trials). *Health Technol Assess*. 2015;19:1–134.
42. Amin MB, Edge S, Greene F, et al. *AJCC Cancer Staging Manual*. New York: Springer; 2017.
43. Weiser MR. AJCC 8<sup>th</sup> Edition: Colorectal Cancer. *Ann Surg Oncol*. 2018;25:1454–1455.
44. Kuo LJ, Liu MC, Jian JJ, et al. Is final TNM staging a predictor for survival in locally advanced rectal cancer after preoperative chemoradiation therapy? *Ann Surg Oncol*. 2007;14:2766–2772.
45. Rödel C, Martus P, Papadopoulos T, et al. Prognostic significance of tumor regression after preoperative chemoradiotherapy for rectal cancer. *J Clin Oncol*. 2005;23:8688–8696.
46. Faletti R, Gatti M, Arezzo A, et al. Preoperative staging of rectal cancer using magnetic resonance imaging: comparison with pathological staging. *Minerva Chir*. 2018;73:13–19.
47. Klessen C, Rogalla P, Taupitz M. Local staging of rectal cancer: the current role of MRI. *Eur Radiol*. 2007;17:379–389.
48. Lahaye MJ, Engelen SM, Nelemans PJ, et al. Imaging for predicting the risk factors—the circumferential resection margin and nodal disease—of local recurrence in rectal cancer: a meta-analysis. *Semin Ultrasound CT MR*. 2005;26:259–268.
49. Xie H, Zhou X, Zhuo Z, Che S, Xie L, Fu W. Effectiveness of MRI for the assessment of mesorectal fascia involvement in patients with rectal cancer: a systematic review and meta-analysis. *Dig Surg*. 2014;31:123–134.
50. Glynne-Jones R, Mawdsley S, Novell JR. The clinical significance of the circumferential resection margin following preoperative pelvic chemo-radiotherapy in rectal cancer: why we need a common language. *Colorectal Dis*. 2006;8:800–807.
51. Nagtegaal ID, Marijnen CA, Kranenbarg EK, van de Velde CJ, van Krieken JH; Pathology Review Committee; Cooperative Clinical Investigators. Circumferential margin involvement is still an important predictor of local recurrence in rectal carcinoma: not one millimeter but two millimeters is the limit. *Am J Surg Pathol*. 2002;26:350–357.
52. Benson AB, Venook AP, Al-Hawary MM, et al. Rectal Cancer, Version 3.2019, NCCN Clinical Practice Guidelines in Oncology. www.nccn.org. Accessed September 1, 2019.
53. Nagtegaal ID, Quirke P. What is the role for the circumferential margin in the modern treatment of rectal cancer? *J Clin Oncol*. 2008;26:303–312.
54. Taylor FG, Quirke P, Heald RJ, et al; Magnetic Resonance Imaging in Rectal Cancer European Equivalence Study Group. Preoperative magnetic resonance imaging assessment of circumferential resection margin predicts disease-free survival and local recurrence: 5-year follow-up results of the MERCURY study. *J Clin Oncol*. 2014;32:34–43.
55. Group MS; MERCURY Study Group. Diagnostic accuracy of preoperative magnetic resonance imaging in predicting curative resection of rectal cancer: prospective observational study. *BMJ*. 2006;333:779.
56. Fraum TJ, Owen JW, Fowler KJ. Beyond histologic staging: emerging imaging strategies in colorectal cancer with special focus on magnetic resonance imaging. *Clin Colon Rectal Surg*. 2016;29:205–215.
57. Beets-Tan RGH, Lambregts DMJ, Maas M, et al. Magnetic resonance imaging for clinical management of rectal cancer: updated recommendations from the 2016 European Society of Gastrointestinal and Abdominal Radiology (ESGAR) consensus meeting. *Eur Radiol*. 2018;28:1465–1475.
58. Garcia-Aguilar J, Pollack J, Lee SH, et al. Accuracy of endorectal ultrasonography in preoperative staging of rectal tumors. *Dis Colon Rectum*. 2002;45:10–15.
59. Marusch F, Koch A, Schmidt U, et al. Routine use of transrectal ultrasound in rectal carcinoma: results of a prospective multicenter study. *Endoscopy*. 2002;34:385–390.
60. Expert Panel on Gastrointestinal Imaging. Fowler KJ, Kaur H, Cash BD, et al. ACR Appropriateness criteria® pretreatment staging of colorectal cancer. *J Am Coll Radiol*. 2017;14:S234–S244.
61. Bipat S, Glas AS, Slors FJ, Zwinderman AH, Bossuyt PM, Stoker J. Rectal cancer: local staging and assessment of lymph node involvement with endoluminal US, CT, and MR imaging—a meta-analysis. *Radiology*. 2004;232:773–783.
62. Brown G, Richards CJ, Bourne MW, et al. Morphologic predictors of lymph node status in rectal cancer with use of high-spatial-resolution MR imaging with histopathologic comparison. *Radiology*. 2003;227:371–377.
63. Kim JH, Beets GL, Kim MJ, Kessels AG, Beets-Tan RG. High-resolution MR imaging for nodal staging in rectal cancer: are there any criteria in addition to the size? *Eur J Radiol*. 2004;52:78–83.
64. Riihimäki M, Hemminki A, Sundquist J, Hemminki K. Patterns of metastasis in colon and rectal cancer. *Sci Rep*. 2016;6:29765.
65. Choi DJ, Kwak JM, Kim J, Woo SU, Kim SH. Preoperative chest computerized tomography in patients with locally advanced mid or lower rectal cancer: its role in staging and impact on treatment strategy. *J Surg Oncol*. 2010;102:588–592.
66. Grossmann I, Avenarius JK, Mastboom WJ, Klaase JM. Preoperative staging with chest CT in patients with colorectal carcinoma: not as a routine procedure. *Ann Surg Oncol*. 2010;17:2045–2050.
67. Adam R, de Gramont A, Figueras J, et al; of the EGOSLIM (Expert Group on OncoSurgery management of Liver Metastases) group. Managing synchronous liver metastases from colorectal cancer: a multidisciplinary international consensus. *Cancer Treat Rev*. 2015;41:729–741.
68. Vera R, González-Flores E, Rubio C, et al. Multidisciplinary management of liver metastases in patients with colorectal cancer: a consensus of SEOM, AEC, SEOR, SERVEI, and SEMNIM. *Clin Transl Oncol*. 2020;22:647–662.
69. Expert Panel on Gastrointestinal Imaging. Kaur H, Hindman NM, Al-Refaie WB, et al. ACR Appropriateness criteria((R)) suspected liver metastases. *J Am Coll Radiol*. 2017;14:S314–S325.

70. Maffione AM, Marzola MC, Capirci C, Colletti PM, Rubello D. Value of (18)F-FDG PET for predicting response to neoadjuvant therapy in rectal cancer: systematic review and meta-analysis. *AJR Am J Roentgenol*. 2015;204:1261–1268.
71. Ramos E, Valls C, Martinez L, et al. Preoperative staging of patients with liver metastases of colorectal carcinoma. Does PET/CT really add something to multidetector CT? *Ann Surg Oncol*. 2011;18:2654–2661.
72. Cipe G, Ergul N, Hasbahceci M, et al. Routine use of positron-emission tomography/computed tomography for staging of primary colorectal cancer: does it affect clinical management? *World J Surg Oncol*. 2013;11:49.
73. Laurens ST, Oyen WJ. Impact of fluorodeoxyglucose PET/computed tomography on the management of patients with colorectal cancer. *PET Clin*. 2015;10:345–360.
74. Davids JS, Alavi K, Andres Cervera-Servin J, et al. Routine preoperative restaging CTs after neoadjuvant chemoradiation for locally advanced rectal cancer are low yield: a retrospective case study. *Int J Surg*. 2014;12:1295–1299.
75. Liu GC, Zhang X, Xie E, et al. The value of restaging with chest and abdominal CT/MRI scan after neoadjuvant chemoradiotherapy for locally advanced rectal cancer. *Medicine (Baltimore)*. 2015;94:e2074.
76. de Jong EA, ten Berge JC, Dwarkasing RS, Rijkers AP, van Eijck CH. The accuracy of MRI, endorectal ultrasonography, and computed tomography in predicting the response of locally advanced rectal cancer after preoperative therapy: a metaanalysis. *Surgery*. 2016;159:688–699.
77. Dickman R, Kundel Y, Levy-Drummer R, et al. Restaging locally advanced rectal cancer by different imaging modalities after preoperative chemoradiation: a comparative study. *Radiat Oncol*. 2013;8:278.
78. Hanly AM, Ryan EM, Rogers AC, McNamara DA, Madoff RD, Winter DC; MERRION Study Group. Multicenter Evaluation of Rectal cancer ReImaging pOst Neoadjuvant (MERRION) Therapy. *Ann Surg*. 2014;259:723–727.
79. Memon S, Lynch AC, Bressel M, Wise AG, Heriot AG. Systematic review and meta-analysis of the accuracy of MRI and endorectal ultrasound in the restaging and response assessment of rectal cancer following neoadjuvant therapy. *Colorectal Dis*. 2015;17:748–761.
80. Schneider DA, Akhurst TJ, Ngan SY, et al. Relative value of restaging MRI, CT, and FDG-PET scan after preoperative chemoradiation for rectal cancer. *Dis Colon Rectum*. 2016;59:179–186.
81. Ioannidis A, Konstantinidis M, Apostolakis S, Koutsierimpas C, Machairas N, Konstantinidis KM. Impact of multidisciplinary tumor boards on patients with rectal cancer. *Mol Clin Oncol*. 2018;9:135–137.
82. Richardson B, Preskitt J, Lichliter W, et al. The effect of multidisciplinary teams for rectal cancer on delivery of care and patient outcome: has the use of multidisciplinary teams for rectal cancer affected the utilization of available resources, proportion of patients meeting the standard of care, and does this translate into changes in patient outcome? *Am J Surg*. 2016;211:46–52.
83. van de Velde CJ, Boelens PG, Borrás JM, et al. EURECCA colorectal: multidisciplinary management: European consensus conference colon & rectum. *Eur J Cancer* 2014;50:1 e– e34.
84. Bass EM, Del Pino A, Tan A, Pearl RK, Orsay CP, Abcarian H. Does preoperative stoma marking and education by the enterostomal therapist affect outcome? *Dis Colon Rectum*. 1997;40:440–442.
85. Chaudhri S, Brown L, Hassan I, Horgan AF. Preoperative intensive, community-based vs. traditional stoma education: a randomized, controlled trial. *Dis Colon Rectum*. 2005;48:504–509.
86. Crooks S. Foresight that leads to improved outcome: stoma care nurses' role in siting stomas. *Prof Nurse*. 1994;10:89–92.
87. Salvadalena G, Hendren S, McKenna L, et al. WOCN Society and ASCRS position statement on preoperative stoma site marking for patients undergoing colostomy or ileostomy surgery. *J Wound Ostomy Continence Nurs*. 2015;42:249–252.
88. Hendren S, Hammond K, Glasgow SC, et al. Clinical practice guidelines for ostomy surgery. *Dis Colon Rectum*. 2015;58:375–387.
89. Brunner W, Widmann B, Marti L, Tarantino I, Schmied BM, Warschkow R. Predictors for regional lymph node metastasis in T1 rectal cancer: a population-based SEER analysis. *Surg Endosc*. 2016;30:4405–4415.
90. Nascimbeni R, Burgart LJ, Nivatvongs S, Larson DR. Risk of lymph node metastasis in T1 carcinoma of the colon and rectum. *Dis Colon Rectum*. 2002;45:200–206.
91. Christoforidis D, Cho HM, Dixon MR, Mellgren AF, Madoff RD, Finne CO. Transanal endoscopic microsurgery versus conventional transanal excision for patients with early rectal cancer. *Ann Surg*. 2009;249:776–782.
92. Clancy C, Burke JP, Albert MR, O'Connell PR, Winter DC. Transanal endoscopic microsurgery versus standard transanal excision for the removal of rectal neoplasms: a systematic review and meta-analysis. *Dis Colon Rectum*. 2015;58:254–261.
93. Lee L, Edwards K, Hunter IA, et al. Quality of local excision for rectal neoplasms using transanal endoscopic microsurgery versus transanal minimally invasive surgery: a multi-institutional matched analysis. *Dis Colon Rectum*. 2017;60:928–935.
94. Emmanuel A, Gulati S, Burt M, Hayee B, Haji A. Colorectal endoscopic submucosal dissection: patient selection and special considerations. *Clin Exp Gastroenterol*. 2017;10:121–131.
95. Doornebosch PG, Tollenaar RA, De Graaf EJ. Is the increasing role of Transanal Endoscopic Microsurgery in curation for T1 rectal cancer justified? A systematic review. *Acta Oncol*. 2009;48:343–353.
96. Kidane B, Chadi SA, Kanters S, Colquhoun PH, Ott MC. Local resection compared with radical resection in the treatment of T1N0M0 rectal adenocarcinoma: a systematic review and meta-analysis. *Dis Colon Rectum*. 2015;58:122–140.
97. You YN, Baxter NN, Stewart A, Nelson H. Is the increasing rate of local excision for stage I rectal cancer in the United States justified?: a nationwide cohort study from the National Cancer Database. *Ann Surg*. 2007;245:726–733.
98. Halverson AL, Morris AM, Cleary RK, Chang GJ. For patients with early rectal cancer, does local excision have an impact on recurrence, survival, and quality of life relative to radical resection? *Ann Surg Oncol*. 2019;26:2497–2506.
99. Borstlap WA, Coeymans TJ, Tanis PJ, et al. Meta-analysis of oncological outcomes after local excision of pT1-2 rectal cancer requiring adjuvant (chemo)radiotherapy or completion surgery. *Br J Surg*. 2016;103:1105–1116.

100. Russo S, Anker CJ, Abdel-Wahab M, et al; Expert Panel on Radiation Oncology- Local Excision in Rectal Cancer. Executive Summary of the American Radium Society Appropriate Use Criteria for Local Excision in Rectal Cancer. *Int J Radiat Oncol Biol Phys.* 2019;105:977–993.
101. Garcia-Aguilar J, Renfro LA, Chow OS, et al. Organ preservation for clinical T2N0 distal rectal cancer using neoadjuvant chemoradiotherapy and local excision (ACOSOG Z6041): results of an open-label, single-arm, multi-institutional, phase 2 trial. *Lancet Oncol.* 2015;16:1537–1546.
102. Shaikh I, Askari A, Ourù S, Warusavitarne J, Athanasiou T, Faiz O. Oncological outcomes of local excision compared with radical surgery after neoadjuvant chemoradiotherapy for rectal cancer: a systematic review and meta-analysis. *Int J Colorectal Dis.* 2015;30:19–29.
103. Rullier E, Vendrely V, Asselineau J, et al. Organ preservation with chemoradiotherapy plus local excision for rectal cancer: 5-year results of the GRECCAR 2 randomised trial. *Lancet Gastroenterol Hepatol.* 2020;5:465–474.
104. Lezoche E, Baldarelli M, Lezoche G, Paganini AM, Gesuita R, Guerrieri M. Randomized clinical trial of endoluminal locoregional resection versus laparoscopic total mesorectal excision for T2 rectal cancer after neoadjuvant therapy. *Br J Surg.* 2012;99:1211–1218.
105. Smith FM, Ahad A, Perez RO, Marks J, Bujko K, Heald RJ. Local excision techniques for rectal cancer after neoadjuvant chemoradiotherapy: what are we doing? *Dis Colon Rectum.* 2017;60:228–239.
106. Hallam S, Messenger DE, Thomas MG. A systematic review of local excision after neoadjuvant therapy for rectal cancer: are ypT0 tumors the limit? *Dis Colon Rectum.* 2016;59:984–997.
107. Nelson H, Petrelli N, Carlin A, et al; National Cancer Institute Expert Panel. Guidelines 2000 for colon and rectal cancer surgery. *J Natl Cancer Inst.* 2001;93:583–596.
108. Heald RJ, Husband EM, Ryall RD. The mesorectum in rectal cancer surgery—the clue to pelvic recurrence? *Br J Surg.* 1982;69:613–616.
109. Quirke P, Steele R, Monson J, et al; MRC CR07/NCIC-CTG CO16 Trial Investigators; NCRI Colorectal Cancer Study Group. Effect of the plane of surgery achieved on local recurrence in patients with operable rectal cancer: a prospective study using data from the MRC CR07 and NCIC-CTG CO16 randomised clinical trial. *Lancet.* 2009;373:821–828.
110. Hida J, Yasutomi M, Maruyama T, Fujimoto K, Uchida T, Okuno K. Lymph node metastases detected in the mesorectum distal to carcinoma of the rectum by the clearing method: justification of total mesorectal excision. *J Am Coll Surg.* 1997;184:584–588.
111. Scott N, Jackson P, al-Jaber T, Dixon MF, Quirke P, Finan PJ. Total mesorectal excision and local recurrence: a study of tumour spread in the mesorectum distal to rectal cancer. *Br J Surg.* 1995;82:1031–1033.
112. Andreola S, Leo E, Belli F, et al. Distal intramural spread in adenocarcinoma of the lower third of the rectum treated with total rectal resection and coloanal anastomosis. *Dis Colon Rectum.* 1997;40:25–29.
113. Bujko K, Rutkowski A, Chang GJ, Michalski W, Chmielik E, Kusnierz J. Is the 1-cm rule of distal bowel resection margin in rectal cancer based on clinical evidence? A systematic review. *Ann Surg Oncol.* 2012;19:801–808.
114. Guillem JG, Chessin DB, Shia J, et al. A prospective pathologic analysis using whole-mount sections of rectal cancer following preoperative combined modality therapy: implications for sphincter preservation. *Ann Surg.* 2007;245:88–93.
115. Kuvshinov B, Maghfoor I, Miedema B, et al. Distal margin requirements after preoperative chemoradiotherapy for distal rectal carcinomas: are < or = 1 cm distal margins sufficient? *Ann Surg Oncol.* 2001;8:163–169.
116. Adam IJ, Mohamdee MO, Martin IG, et al. Role of circumferential margin involvement in the local recurrence of rectal cancer. *Lancet.* 1994;344:707–711.
117. How P, Shihab O, Tekkis P, et al. A systematic review of cancer related patient outcomes after anterior resection and abdominoperineal excision for rectal cancer in the total mesorectal excision era. *Surg Oncol.* 2011;20:e149–e155.
118. den Dulk M, Marijnen CA, Putter H, et al. Risk factors for adverse outcome in patients with rectal cancer treated with an abdominoperineal resection in the total mesorectal excision trial. *Ann Surg.* 2007;246:83–90.
119. den Dulk M, Putter H, Collette L, et al. The abdominoperineal resection itself is associated with an adverse outcome: the European experience based on a pooled analysis of five European randomised clinical trials on rectal cancer. *Eur J Cancer.* 2009;45:1175–1183.
120. Porter GA, O’Keefe GE, Yakimets WW. Inadvertent perforation of the rectum during abdominoperineal resection. *Am J Surg.* 1996;172:324–327.
121. Slanetz CA Jr. The effect of inadvertent intraoperative perforation on survival and recurrence in colorectal cancer. *Dis Colon Rectum.* 1984;27:792–797.
122. Holm T, Ljung A, Häggmark T, Jurell G, Lagergren J. Extended abdominoperineal resection with gluteus maximus flap reconstruction of the pelvic floor for rectal cancer. *Br J Surg.* 2007;94:232–238.
123. West NP, Anderin C, Smith KJ, Holm T, Quirke P; European Extralevator Abdominoperineal Excision Study Group. Multicentre experience with extralevator abdominoperineal excision for low rectal cancer. *Br J Surg.* 2010;97:588–599.
124. West NP, Finan PJ, Anderin C, Lindholm J, Holm T, Quirke P. Evidence of the oncologic superiority of cylindrical abdominoperineal excision for low rectal cancer. *J Clin Oncol.* 2008;26:3517–3522.
125. Asplund D, Haglind E, Angenete E. Outcome of extralevator abdominoperineal excision compared with standard surgery: results from a single centre. *Colorectal Dis.* 2012;14:1191–1196.
126. Klein M, Fischer A, Rosenberg J, Gögenur I; Danish Colorectal Cancer Group (DCCG). Extralevator abdominoperineal excision (ELAPE) does not result in reduced rate of tumor perforation or rate of positive circumferential resection margin: a nationwide database study. *Ann Surg.* 2015;261:933–938.
127. Krishna A, Rickard MJ, Keshava A, Dent OF, Chapuis PH. A comparison of published rates of resection margin involvement and intra-operative perforation between standard and ‘cylindrical’ abdominoperineal excision for low rectal cancer. *Colorectal Dis.* 2013;15:57–65.
128. Ortiz H, Ciga MA, Armendariz P, et al; Spanish Rectal Cancer Project. Multicentre propensity score-matched analysis of conventional versus extended abdominoperineal excision for low rectal cancer. *Br J Surg.* 2014;101:874–882.



129. Prytz M, Angenete E, Bock D, Haglind E. Extralevator abdominoperineal excision for low rectal cancer—extensive surgery to be used with discretion based on 3-year local recurrence results: a registry-based, observational national cohort study. *Ann Surg.* 2016;263:516–521.
130. Stelzner S, Koehler C, Stelzer J, Sims A, Witzigmann H. Extended abdominoperineal excision vs. standard abdominoperineal excision in rectal cancer—a systematic overview. *Int J Colorectal Dis.* 2011;26:1227–1240.
131. Yu HC, Peng H, He XS, Zhao RS. Comparison of short- and long-term outcomes after extralevator abdominoperineal excision and standard abdominoperineal excision for rectal cancer: a systematic review and meta-analysis. *Int J Colorectal Dis.* 2014;29:183–191.
132. Cirocchi R, Trastulli S, Farinella E, et al. High tie versus low tie of the inferior mesenteric artery in colorectal cancer: a RCT is needed. *Surg Oncol.* 2012;21:e111–e123.
133. Kang J, Hur H, Min BS, Kim NK, Lee KY. Prognostic impact of inferior mesenteric artery lymph node metastasis in colorectal cancer. *Ann Surg Oncol.* 2011;18:704–710.
134. Rao X, Zhang J, Liu T, et al. Prognostic value of inferior mesenteric artery lymph node metastasis in cancer of the descending colon, sigmoid colon and rectum. *Colorectal Dis.* 2018;20:O135–O142.
135. Mari GM, Crippa J, Cocozza E, et al. Low ligation of inferior mesenteric artery in laparoscopic anterior resection for rectal cancer reduces genitourinary dysfunction: results from a randomized controlled trial (HIGHLOW Trial). *Ann Surg.* 2019;269:1018–1024.
136. Yasuda K, Kawai K, Ishihara S, et al. Level of arterial ligation in sigmoid colon and rectal cancer surgery. *World J Surg Oncol.* 2016;14:99.
137. Georgiou P, Tan E, Gouvas N, et al. Extended lymphadenectomy versus conventional surgery for rectal cancer: a meta-analysis. *Lancet Oncol.* 2009;10:1053–1062.
138. Kusters M, Marijnen CA, van de Velde CJ, et al. Patterns of local recurrence in rectal cancer; a study of the Dutch TME trial. *Eur J Surg Oncol.* 2010;36:470–476.
139. Ogura A, Konishi T, Cunningham C, et al; Lateral Node Study Consortium. Neoadjuvant (chemo)radiotherapy with total mesorectal excision only is not sufficient to prevent lateral local recurrence in enlarged nodes: results of the multicenter lateral node study of patients with low cT3/4 rectal cancer. *J Clin Oncol.* 2019;37:33–43.
140. Komori K, Fujita S, Mizusawa J, et al; Colorectal Cancer Study Group of Japan Clinical Oncology Group. Predictive factors of pathological lateral pelvic lymph node metastasis in patients without clinical lateral pelvic lymph node metastasis (clinical stage II/III): The analysis of data from the clinical trial (JCOG0212). *Eur J Surg Oncol.* 2019;45:336–340.
141. Fujita S, Mizusawa J, Kanemitsu Y, et al; Colorectal Cancer Study Group of Japan Clinical Oncology Group. Mesorectal excision with or without lateral lymph node dissection for clinical stage II/III lower rectal cancer (JCOG0212): a multicenter, randomized controlled, noninferiority trial. *Ann Surg.* 2017;266:201–207.
142. Lehnert T, Methner M, Pollok A, Schaible A, Hinz U, Herfarth C. Multivisceral resection for locally advanced primary colon and rectal cancer: an analysis of prognostic factors in 201 patients. *Ann Surg.* 2002;235:217–225.
143. Gosens MJ, Klaassen RA, Tan-Go I, et al. Circumferential margin involvement is the crucial prognostic factor after multimodality treatment in patients with locally advanced rectal carcinoma. *Clin Cancer Res.* 2007;13(22 Pt 1):6617–6623.
144. Beyond TME Collaborative. Consensus statement on the multidisciplinary management of patients with recurrent and primary rectal cancer beyond total mesorectal excision planes. *Br J Surg.* 2013;100:1009–1014.
145. Patel A, Holm T, Wale A, et al. Session 3: beyond the boundaries of total mesorectal excision - where surgeons fear to tread. *Colorectal Dis.* 2018;20 Suppl 1:61–64.
146. Helewa RM, Park J. Surgery for locally advanced T4 rectal cancer: strategies and techniques. *Clin Colon Rectal Surg.* 2016;29:106–113.
147. Sclafani F, Brown G, Cunningham D, et al. Systemic chemotherapy as salvage treatment for locally advanced rectal cancer patients who fail to respond to standard neoadjuvant chemoradiotherapy. *Oncologist.* 2017;22:728–736.
148. Denost Q, Kontovounisios C, Rasheed S, et al. Individualizing surgical treatment based on tumour response following neoadjuvant therapy in T4 primary rectal cancer. *Eur J Surg Oncol.* 2017;43:92–99.
149. Haddock MG. Intraoperative radiation therapy for colon and rectal cancers: a clinical review. *Radiat Oncol.* 2017;12:11.
150. Mirnezami R, Chang GJ, Das P, et al. Intraoperative radiotherapy in colorectal cancer: systematic review and meta-analysis of techniques, long-term outcomes, and complications. *Surg Oncol.* 2013;22:22–35.
151. Dubois JB, Bussieres E, Richaud P, et al. Intra-operative radiotherapy of rectal cancer: results of the French multi-institutional randomized study. *Radiation Oncol.* 2011;98:298–303.
152. Kusters M, Valentini V, Calvo FA, et al. Results of European pooled analysis of IORT-containing multimodality treatment for locally advanced rectal cancer: adjuvant chemotherapy prevents local recurrence rather than distant metastases. *Ann Oncol.* 2010;21:1279–1284.
153. Alberda WJ, Verhoef C, Nuyttens JJ, et al. Intraoperative radiation therapy reduces local recurrence rates in patients with microscopically involved circumferential resection margins after resection of locally advanced rectal cancer. *Int J Radiat Oncol Biol Phys.* 2014;88:1032–1040.
154. Hyngstrom JR, Tzeng CW, Beddar S, et al. Intraoperative radiation therapy for locally advanced primary and recurrent colorectal cancer: ten-year institutional experience. *J Surg Oncol.* 2014;109:652–658.
155. Jiang JB, Jiang K, Dai Y, et al. Laparoscopic versus open surgery for mid-low rectal cancer: a systematic review and meta-analysis on short- and long-term outcomes. *J Gastrointest Surg.* 2015;19:1497–1512.
156. Bonjer HJ, Deijen CL, Haglind E; COLOR II Study Group. A randomized trial of laparoscopic versus open surgery for rectal cancer. *N Engl J Med.* 2015;373:194.
157. Guillou PJ, Quirke P, Thorpe H, et al; MRC CLASICC trial group. Short-term endpoints of conventional versus laparoscopic-assisted surgery in patients with colorectal cancer (MRC CLASICC trial): multicentre, randomised controlled trial. *Lancet.* 2005;365:1718–1726.
158. Jeong SY, Park JW, Nam BH, et al. Open versus laparoscopic surgery for mid-rectal or low-rectal cancer after neoadjuvant chemoradiotherapy (COREAN trial): survival outcomes of an

- open-label, non-inferiority, randomised controlled trial. *Lancet Oncol.* 2014;15:767–774.
159. van der Pas MH, Haglind E, Cuesta MA, et al; COLOrectal cancer Laparoscopic or Open Resection II (COLOR II) Study Group. Laparoscopic versus open surgery for rectal cancer (COLOR II): short-term outcomes of a randomised, phase 3 trial. *Lancet Oncol.* 2013;14:210–218.
  160. Fleshman J, Branda M, Sargent DJ, et al. Effect of laparoscopic-assisted resection vs open resection of stage II or III rectal cancer on pathologic outcomes: the ACOSOG Z6051 randomized clinical trial. *JAMA.* 2015;314:1346–1355.
  161. Stevenson AR, Solomon MJ, Lumley JW, et al; ALaCaRT Investigators. Effect of laparoscopic-assisted resection vs open resection on pathological outcomes in rectal cancer: the ALaCaRT randomized clinical trial. *JAMA.* 2015;314:1356–1363.
  162. Martínez-Pérez A, Carra MC, Brunetti F, de'Angelis N. Pathologic outcomes of laparoscopic vs open mesorectal excision for rectal cancer: a systematic review and meta-analysis. *JAMA Surg.* 2017;152:e165665.
  163. Vennix S, Pelzers L, Bouvy N, et al. Laparoscopic versus open total mesorectal excision for rectal cancer. *Cochrane Database Syst Rev.* 2014;(4):CD005200.
  164. Fleshman J, Branda ME, Sargent DJ, et al. Disease-free survival and local recurrence for laparoscopic resection compared with open resection of stage II to III rectal cancer: follow-up results of the ACOSOG Z6051 randomized controlled trial. *Ann Surg.* 2019;269:589–595.
  165. Stevenson ARL, Solomon MJ, Brown CSB, et al; Australasian Gastro-Intestinal Trials Group (AGITG) ALaCaRT investigators. Disease-free survival and local recurrence after laparoscopic-assisted resection or open resection for rectal cancer: the Australasian Laparoscopic Cancer of the Rectum Randomized Clinical Trial. *Ann Surg.* 2019;269:596–602.
  166. Jayne D, Pigazzi A, Marshall H, et al. Effect of robotic-assisted vs conventional laparoscopic surgery on risk of conversion to open laparotomy among patients undergoing resection for rectal cancer: the ROLARR randomized clinical trial. *JAMA.* 2017;318:1569–1580.
  167. Huang YJ, Kang YN, Huang YM, Wu AT, Wang W, Wei PL. Effects of laparoscopic vs robotic-assisted mesorectal excision for rectal cancer: An update systematic review and meta-analysis of randomized controlled trials. *Asian J Surg.* 2019;42:657–666.
  168. Roh HF, Nam SH, Kim JM. Robot-assisted laparoscopic surgery versus conventional laparoscopic surgery in randomized controlled trials: a systematic review and meta-analysis. *PLoS One.* 2018;13:e0191628.
  169. Trastulli S, Farinella E, Cirocchi R, et al. Robotic resection compared with laparoscopic rectal resection for cancer: systematic review and meta-analysis of short-term outcome. *Colorectal Dis.* 2012;14:e134–e156.
  170. Lei P, Ruan Y, Yang X, Fang J, Chen T. Trans-anal or trans-abdominal total mesorectal excision? A systematic review and meta-analysis of recent comparative studies on perioperative outcomes and pathological result. *Int J Surg.* 2018;60:113–119.
  171. Wu Z, Zhou W, Chen F, Wang W, Feng Y. Short-term outcomes of transanal versus laparoscopic total mesorectal excision: a systematic review and meta-analysis of cohort studies. *J Cancer.* 2019;10:341–354.
  172. Zhang X, Gao Y, Dai X, et al. Short- and long-term outcomes of transanal versus laparoscopic total mesorectal excision for mid-to-low rectal cancer: a meta-analysis. *Surg Endosc.* 2019;33:972–985.
  173. Koedam TWA, Veltcamp Helbach M, van de Ven PM, et al. Transanal total mesorectal excision for rectal cancer: evaluation of the learning curve. *Tech Coloproctol.* 2018;22:279–287.
  174. Deijen CL, Tsai A, Koedam TW, et al. Clinical outcomes and case volume effect of transanal total mesorectal excision for rectal cancer: a systematic review. *Tech Coloproctol.* 2016;20:811–824.
  175. Penna M, Hompes R, Arnold S, et al; TaTME Registry Collaborative. Transanal total mesorectal excision: international registry results of the first 720 cases. *Ann Surg.* 2017;266:111–117.
  176. Dickson EA, Penna M, Cunningham C, et al; International TaTME Registry Collaborative. Carbon dioxide embolism associated with transanal total mesorectal excision surgery: a report from the international registries. *Dis Colon Rectum.* 2019;62:794–801.
  177. Harnsberger CR, Alavi K, Davids JS, Sturrock PR, Zayaruzny M, Maykel JA. CO2 embolism can complicate transanal total mesorectal excision. *Tech Coloproctol.* 2018;22:881–885.
  178. Larsen SG, Pfeffer F, Kørner H; Norwegian Colorectal Cancer Group. Norwegian moratorium on transanal total mesorectal excision. *Br J Surg.* 2019;106:1120–1121.
  179. Deijen CL, Velthuis S, Tsai A, et al. COLOR III: a multicentre randomised clinical trial comparing transanal TME versus laparoscopic TME for mid and low rectal cancer. *Surg Endosc.* 2016;30:3210–3215.
  180. Cui J, Fang H, Zhang L, Wu YL, Zhang HZ. Advances for achieving a pathological complete response for rectal cancer after neoadjuvant therapy. *Chronic Dis Transl Med.* 2016;2:10–16.
  181. Ryan JE, Warrier SK, Lynch AC, Ramsay RG, Phillips WA, Heriot AG. Predicting pathological complete response to neoadjuvant chemoradiotherapy in locally advanced rectal cancer: a systematic review. *Colorectal Dis.* 2016;18:234–246.
  182. Maas M, Nelemans PJ, Valentini V, et al. Long-term outcome in patients with a pathological complete response after chemoradiation for rectal cancer: a pooled analysis of individual patient data. *Lancet Oncol.* 2010;11:835–844.
  183. Fokas E, Strobel P, Fietkau R, et al; German Rectal Cancer Study Group. Tumor regression grading after preoperative chemoradiotherapy as a prognostic factor and individual-level surrogate for disease-free survival in rectal cancer. *J Natl Cancer Inst.* 2017;109(12). doi: 10.1093/jnci/djx095.
  184. Karagkounis G, Thai L, Mace AG, et al. Prognostic implications of pathological response to neoadjuvant chemoradiation in pathologic stage III rectal cancer. *Ann Surg.* 2019;269:1117–1123.
  185. Maas M, Beets-Tan RG, Lambregts DM, et al. Wait-and-see policy for clinical complete responders after chemoradiation for rectal cancer. *J Clin Oncol.* 2011;29:4633–4640.
  186. Hiotis SP, Weber SM, Cohen AM, et al. Assessing the predictive value of clinical complete response to neoadjuvant therapy for rectal cancer: an analysis of 488 patients. *J Am Coll Surg.* 2002;194:131–135.
  187. Smith FM, Chang KH, Sheahan K, Hyland J, O'Connell PR, Winter DC. The surgical significance of residual mucosal abnormalities in rectal cancer following neoadjuvant chemoradiotherapy. *Br J Surg.* 2012;99:993–1001.
  188. Kundel Y, Brenner R, Purim O, et al. Is local excision after complete pathological response to neoadjuvant chemoradiation

- for rectal cancer an acceptable treatment option? *Dis Colon Rectum*. 2010;53:1624–1631.
189. Ortega CD, Perez RO. Role of magnetic resonance imaging in organ-preserving strategies for the management of patients with rectal cancer. *Insights Imaging*. 2019;10:59.
  190. Lambregts DMJ, Boellaard TN, Beets-Tan RGH. Response evaluation after neoadjuvant treatment for rectal cancer using modern MR imaging: a pictorial review. *Insights Imaging*. 2019;10:15.
  191. Chadi SA, Malcomson L, Ensor J, et al. Factors affecting local regrowth after watch and wait for patients with a clinical complete response following chemoradiotherapy in rectal cancer (InterCoRe consortium): an individual participant data meta-analysis. *Lancet Gastroenterol Hepatol*. 2018;3:825–836.
  192. Appelt AL, Pløen J, Harling H, et al. High-dose chemoradiotherapy and watchful waiting for distal rectal cancer: a prospective observational study. *Lancet Oncol*. 2015;16:919–927.
  193. Habr-Gama A, Gama-Rodrigues J, São Julião GP, et al. Local recurrence after complete clinical response and watch and wait in rectal cancer after neoadjuvant chemoradiation: impact of salvage therapy on local disease control. *Int J Radiat Oncol Biol Phys*. 2014;88:822–828.
  194. Li J, Liu H, Yin J, et al. Wait-and-see or radical surgery for rectal cancer patients with a clinical complete response after neoadjuvant chemoradiotherapy: a cohort study. *Oncotarget*. 2015;6:42354–42361.
  195. Habr-Gama A, Perez RO, Nadalin W, et al. Operative versus nonoperative treatment for stage 0 distal rectal cancer following chemoradiation therapy: long-term results. *Ann Surg*. 2004;240:711–717.
  196. Smith JD, Ruby JA, Goodman KA, et al. Nonoperative management of rectal cancer with complete clinical response after neoadjuvant therapy. *Ann Surg*. 2012;256:965–972.
  197. Dossa F, Chesney TR, Acuna SA, Baxter NN. A watch-and-wait approach for locally advanced rectal cancer after a clinical complete response following neoadjuvant chemoradiation: a systematic review and meta-analysis. *Lancet Gastroenterol Hepatol*. 2017;2:501–513.
  198. Sammour T, Price BA, Krause KJ, Chang GJ. Nonoperative management or ‘watch and wait’ for rectal cancer with complete clinical response after neoadjuvant chemoradiotherapy: a critical appraisal. *Ann Surg Oncol*. 2017;24:1904–1915.
  199. Dattani M, Heald RJ, Goussous G, et al. Oncological and survival outcomes in watch and wait patients with a clinical complete response after neoadjuvant chemoradiotherapy for rectal cancer: a systematic review and pooled analysis. *Ann Surg*. 2018;268:955–967.
  200. van der Valk MJM, Hilling DE, Bastiaannet E, et al; IWWD Consortium. Long-term outcomes of clinical complete responders after neoadjuvant treatment for rectal cancer in the International Watch & Wait Database (IWWD): an international multicentre registry study. *Lancet*. 2018;391:2537–2545.
  201. Smith JJ, Strombom P, Chow OS, et al. Assessment of a watch-and-wait strategy for rectal cancer in patients with a complete response after neoadjuvant therapy. *JAMA Oncol*. 2019;5:e185896.
  202. Umpleby HC, Fermor B, Symes MO, Williamson RC. Viability of exfoliated colorectal carcinoma cells. *Br J Surg*. 1984;71:659–663.
  203. Rondelli F, Trastulli S, Cirocchi R, et al. Rectal washout and local recurrence in rectal resection for cancer: a meta-analysis. *Colorectal Dis*. 2012;14:1313–1321.
  204. Zhou C, Ren Y, Li J, Li X, He J, Liu P. Systematic review and meta-analysis of rectal washout on risk of local recurrence for cancer. *J Surg Res*. 2014;189:7–16.
  205. Keane C, Wells C, O’Grady G, Bissett IP. Defining low anterior resection syndrome: a systematic review of the literature. *Colorectal Dis*. 2017;19:713–722.
  206. Hüttner FJ, Tenckhoff S, Jensen K, et al. Meta-analysis of reconstruction techniques after low anterior resection for rectal cancer. *Br J Surg*. 2015;102:735–745.
  207. Liao C, Gao F, Cao Y, Tan A, Li X, Wu D. Meta-analysis of the colon J-pouch vs transverse colectomy pouch after anterior resection for rectal cancer. *Colorectal Dis*. 2010;12:624–631.
  208. Brown CJ, Fenech DS, McLeod RS. Reconstructive techniques after rectal resection for rectal cancer. *Cochrane Database Syst Rev*. 2008;(2):CD006040.
  209. Fazio VW, Zutshi M, Remzi FH, et al. A randomized multicenter trial to compare long-term functional outcome, quality of life, and complications of surgical procedures for low rectal cancers. *Ann Surg*. 2007;246:481–488.
  210. Okkabaz N, Haksal M, Atici AE, et al. J-pouch vs. side-to-end anastomosis after hand-assisted laparoscopic low anterior resection for rectal cancer: A prospective randomized trial on short and long term outcomes including life quality and functional results. *Int J Surg*. 2017;47:4–12.
  211. Rubin F, Douard R, Wind P. The functional outcomes of coloanal and low colorectal anastomoses with reservoirs after low rectal cancer resections. *Am Surg*. 2014;80:1222–1229.
  212. Matthiessen P, Hallböök O, Rutegård J, Simert G, Sjødahl R. Defunctioning stoma reduces symptomatic anastomotic leakage after low anterior resection of the rectum for cancer: a randomized multicenter trial. *Ann Surg*. 2007;246:207–214.
  213. Tsikitis VL, Larson DW, Poola VP, et al. Postoperative morbidity with diversion after low anterior resection in the era of neoadjuvant therapy: a single institution experience. *J Am Coll Surg*. 2009;209:114–118.
  214. den Dulk M, Marijnen CA, Collette L, et al. Multicentre analysis of oncological and survival outcomes following anastomotic leakage after rectal cancer surgery. *Br J Surg*. 2009;96:1066–1075.
  215. Gendall KA, Raniga S, Kennedy R, Frizelle FA. The impact of obesity on outcome after major colorectal surgery. *Dis Colon Rectum*. 2007;50:2223–2237.
  216. Ha GW, Kim JH, Lee MR. Oncologic impact of anastomotic leakage following colorectal cancer surgery: a systematic review and meta-analysis. *Ann Surg Oncol*. 2017;24:3289–3299.
  217. Matthiessen P, Hallböök O, Andersson M, Rutegård J, Sjødahl R. Risk factors for anastomotic leakage after anterior resection of the rectum. *Colorectal Dis*. 2004;6:462–469.
  218. Daams F, Wu Z, Lahaye MJ, Jeekel J, Lange JF. Prediction and diagnosis of colorectal anastomotic leakage: a systematic review of literature. *World J Gastrointest Surg*. 2014;6:14–26.
  219. Wu Z, van de Haar RC, Sparreboom CL, et al. Is the intraoperative air leak test effective in the prevention of colorectal anastomotic leakage? A systematic review and meta-analysis. *Int J Colorectal Dis*. 2016;31:1409–1417.

220. Ricciardi R, Roberts PL, Marcello PW, Hall JF, Read TE, Schoetz DJ. Anastomotic leak testing after colorectal resection: what are the data? *Arch Surg*. 2009;144:407–411.
221. Nachiappan S, Askari A, Currie A, Kennedy RH, Faiz O. Intraoperative assessment of colorectal anastomotic integrity: a systematic review. *Surg Endosc*. 2014;28:2513–2530.
222. Gu WL, Wu SW. Meta-analysis of defunctioning stoma in low anterior resection with total mesorectal excision for rectal cancer: evidence based on thirteen studies. *World J Surg Oncol*. 2015;13:9.
223. Hüser N, Michalski CW, Erkan M, et al. Systematic review and meta-analysis of the role of defunctioning stoma in low rectal cancer surgery. *Ann Surg*. 2008;248:52–60.
224. Montedori A, Cirocchi R, Farinella E, Sciannone F, Abraha I. Covering ileo- or colostomy in anterior resection for rectal carcinoma. *Cochrane Database Syst Rev*. 2010;(5):CD006878.
225. Pisarska M, Gajewska N, Małczak P, et al. Defunctioning ileostomy reduces leakage rate in rectal cancer surgery - systematic review and meta-analysis. *Oncotarget*. 2018;9:20816–20825.
226. Tan WS, Tang CL, Shi L, Eu KW. Meta-analysis of defunctioning stomas in low anterior resection for rectal cancer. *Br J Surg*. 2009;96:462–472.
227. Wu SW, Ma CC, Yang Y. Role of protective stoma in low anterior resection for rectal cancer: a meta-analysis. *World J Gastroenterol*. 2014;20:18031–18037.
228. Pommegaard HC, Gessler B, Burcharth J, Angenete E, Haglund E, Rosenberg J. Preoperative risk factors for anastomotic leakage after resection for colorectal cancer: a systematic review and meta-analysis. *Colorectal Dis*. 2014;16:662–671.
229. Lightner AL, Pemberton JH. The role of temporary fecal diversion. *Clin Colon Rectal Surg*. 2017;30:178–183.
230. Musters GD, Buskens CJ, Bemelman WA, Tanis PJ. Perineal wound healing after abdominoperineal resection for rectal cancer: a systematic review and meta-analysis. *Dis Colon Rectum*. 2014;57:1129–1139.
231. Althumairi AA, Canner JK, Gearhart SL, et al. Risk factors for wound complications after abdominoperineal excision: analysis of the ACS NSQIP database. *Colorectal Dis*. 2016;18:O260–O266.
232. Devulapalli C, Jia Wei AT, DiBiagio JR, et al. Primary versus flap closure of perineal defects following oncologic resection: a systematic review and meta-analysis. *Plast Reconstr Surg*. 2016;137:1602–1613.
233. Blok RD, Hagemans JAW, Klaver CEL, et al. A systematic review and meta-analysis on omentoplasty for the management of abdominoperineal defects in patients treated for cancer. *Ann Surg*. 2020;271:654–662.
234. Lee SJ, Lee J, Lim HY, et al. Survival benefit from ovarian metastectomy in colorectal cancer patients with ovarian metastasis: a retrospective analysis. *Cancer Chemother Pharmacol*. 2010;66:229–235.
235. Garrett CR, George B, Viswanathan C, et al. Survival benefit associated with surgical oophorectomy in patients with colorectal cancer metastatic to the ovary. *Clin Colorectal Cancer*. 2012;11:191–194.
236. Huang PP, Weber TK, Mendoza C, Rodriguez-Bigas MA, Petrelli NJ. Long-term survival in patients with ovarian metastases from colorectal carcinoma. *Ann Surg Oncol*. 1998;5:695–698.
237. Young-Fadok TM, Wolff BG, Nivatvongs S, Metzger PP, Ilstrup DM. Prophylactic oophorectomy in colorectal carcinoma: preliminary results of a randomized, prospective trial. *Dis Colon Rectum*. 1998;41:277–283.
238. Finch AP, Lubinski J, Møller P, et al. Impact of oophorectomy on cancer incidence and mortality in women with a BRCA1 or BRCA2 mutation. *J Clin Oncol*. 2014;32:1547–1553.
239. Schmeler KM, Lynch HT, Chen LM, et al. Prophylactic surgery to reduce the risk of gynecologic cancers in the Lynch syndrome. *N Engl J Med*. 2006;354:261–269.
240. Diggs JC, Xu F, Diaz M, Cooper GS, Koroukian SM. Failure to screen: predictors and burden of emergency colorectal cancer resection. *Am J Manag Care*. 2007;13:157–164.
241. McArdle CS, Hole DJ. Emergency presentation of colorectal cancer is associated with poor 5-year survival. *Br J Surg*. 2004;91:605–609.
242. Smothers L, Hynan L, Fleming J, Turnage R, Simmang C, Anthony T. Emergency surgery for colon carcinoma. *Dis Colon Rectum*. 2003;46:24–30.
243. Phang PT, MacFarlane JK, Taylor RH, et al. Effect of emergent presentation on outcome from rectal cancer management. *Am J Surg*. 2003;185:450–454.
244. Runkel NS, Schlag P, Schwarz V, Herfarth C. Outcome after emergency surgery for cancer of the large intestine. *Br J Surg*. 1991;78:183–188.
245. Chia D, Lu J, Zheng H, et al. Efficacy of palliative radiation therapy for symptomatic rectal cancer. *Radiother Oncol*. 2016;121:258–261.
246. Picardi V, Deodato F, Guido A, et al. Palliative short-course radiation therapy in rectal cancer: a phase 2 study. *Int J Radiat Oncol Biol Phys*. 2016;95:1184–1190.
247. Heller SJ, Tokar JL, Nguyen MT, Haluszka O, Weinberg DS. Management of bleeding GI tumors. *Gastrointest Endosc*. 2010;72:817–824.
248. Pisano M, Zorcolo L, Merli C, et al. 2017 WSES guidelines on colon and rectal cancer emergencies: obstruction and perforation. *World J Emerg Surg*. 2018;13:36.
249. Ceresoli M, Allievi N, Coccolini F, et al. Long-term oncologic outcomes of stent as a bridge to surgery versus emergency surgery in malignant left side colonic obstructions: a meta-analysis. *J Gastrointest Oncol*. 2017;8:867–876.
250. Shimura T, Joh T. Evidence-based clinical management of acute malignant colorectal obstruction. *J Clin Gastroenterol*. 2016;50:273–285.
251. Cao Y, Gu J, Deng S, Li J, Wu K, Cai K. Long-term tumour outcomes of self-expanding metal stents as ‘bridge to surgery’ for the treatment of colorectal cancer with malignant obstruction: a systematic review and meta-analysis. *Int J Colorectal Dis*. 2019;34:1827–1838.
252. Gorissen KJ, Tuynman JB, Fryer E, et al. Local recurrence after stenting for obstructing left-sided colonic cancer. *Br J Surg*. 2013;100:1805–1809.
253. Malakorn S, Stein SL, Lee JH, You YN. Urgent management of obstructing colorectal cancer: divert, stent, or resect? *J Gastrointest Surg*. 2019;23:425–432.
254. van Halsema EE, van Hooff JE, Small AJ, et al. Perforation in colorectal stenting: a meta-analysis and a search for risk factors. *Gastrointest Endosc*. 2014;79:970–982.e7.
255. Hünerbein M, Krause M, Moesta KT, Rau B, Schlag PM. Palliation of malignant rectal obstruction with self-expanding metal stents. *Surgery*. 2005;137:42–47.

256. Tomiki Y, Watanabe T, Ishibiki Y, et al. Comparison of stent placement and colostomy as palliative treatment for inoperable malignant colorectal obstruction. *Surg Endosc*. 2004;18:1572–1577.
257. Birgisson H, Pählman L, Gunnarsson U, Glimelius B; Swedish Rectal Cancer Trial Group. Adverse effects of preoperative radiation therapy for rectal cancer: long-term follow-up of the Swedish Rectal Cancer Trial. *J Clin Oncol*. 2005;23:8697–8705.
258. Folkesson J, Birgisson H, Pahlman L, Cedermark B, Glimelius B, Gunnarsson U. Swedish Rectal Cancer Trial: long lasting benefits from radiotherapy on survival and local recurrence rate. *J Clin Oncol*. 2005;23:5644–5650.
259. Kapiteijn E, Marijnen CA, Nagtegaal ID, et al; Dutch Colorectal Cancer Group. Preoperative radiotherapy combined with total mesorectal excision for resectable rectal cancer. *N Engl J Med*. 2001;345:638–646.
260. van Gijn W, Marijnen CA, Nagtegaal ID, et al; Dutch Colorectal Cancer Group. Preoperative radiotherapy combined with total mesorectal excision for resectable rectal cancer: 12-year follow-up of the multicentre, randomised controlled TME trial. *Lancet Oncol*. 2011;12:575–582.
261. Peeters KC, van de Velde CJ, Leer JW, et al. Late side effects of short-course preoperative radiotherapy combined with total mesorectal excision for rectal cancer: increased bowel dysfunction in irradiated patients—a Dutch colorectal cancer group study. *J Clin Oncol*. 2005;23:6199–6206.
262. Wiltink LM, Chen TY, Nout RA, et al. Health-related quality of life 14 years after preoperative short-term radiotherapy and total mesorectal excision for rectal cancer: report of a multicenter randomised trial. *Eur J Cancer*. 2014;50:2390–2398.
263. Abraha I, Aristei C, Palumbo I, et al. Preoperative radiotherapy and curative surgery for the management of localised rectal carcinoma. *Cochrane Database Syst Rev*. 2018;10:CD002102.
264. Sauer R, Liersch T, Merkel S, et al. Preoperative versus postoperative chemoradiotherapy for locally advanced rectal cancer: results of the German CAO/ARO/AIO-94 randomized phase III trial after a median follow-up of 11 years. *J Clin Oncol*. 2012;30:1926–1933.
265. Loos M, Quentmeier P, Schuster T, et al. Effect of preoperative radio(chemo)therapy on long-term functional outcome in rectal cancer patients: a systematic review and meta-analysis. *Ann Surg Oncol*. 2013;20:1816–1828.
266. Ma B, Gao P, Wang H, et al. What has preoperative radio(chemo) therapy brought to localized rectal cancer patients in terms of perioperative and long-term outcomes over the past decades? A systematic review and meta-analysis based on 41,121 patients. *Int J Cancer*. 2017;141:1052–1065.
267. Ngan SY, Burmeister B, Fisher RJ, et al. Randomized trial of short-course radiotherapy versus long-course chemoradiation comparing rates of local recurrence in patients with T3 rectal cancer: Trans-Tasman Radiation Oncology Group trial 01.04. *J Clin Oncol*. 2012;30:3827–3833.
268. Ansari N, Solomon MJ, Fisher RJ, et al. Acute adverse events and postoperative complications in a randomized trial of preoperative short-course radiotherapy versus long-course chemoradiotherapy for T3 adenocarcinoma of the rectum: Trans-Tasman Radiation Oncology Group Trial (TROG 01.04). *Ann Surg*. 2017;265:882–888.
269. Bujko K, Nowacki MP, Kepka L, Oledzki J, Bebenek M, Kryj M; Polish Colorectal Study Group. Postoperative complications in patients irradiated pre-operatively for rectal cancer: report of a randomised trial comparing short-term radiotherapy vs chemoradiation. *Colorectal Dis*. 2005;7:410–416.
270. Zhou ZR, Liu SX, Zhang TS, et al. Short-course preoperative radiotherapy with immediate surgery versus long-course chemoradiation with delayed surgery in the treatment of rectal cancer: a systematic review and meta-analysis. *Surg Oncol*. 2014;23:211–221.
271. Erlandsson J, Holm T, Pettersson D, et al. Optimal fractionation of preoperative radiotherapy and timing to surgery for rectal cancer (Stockholm III): a multicentre, randomised, non-blinded, phase 3, non-inferiority trial. *Lancet Oncol*. 2017;18:336–346.
272. Pettersson D, Lörinc E, Holm T, et al. Tumour regression in the randomized Stockholm III Trial of radiotherapy regimens for rectal cancer. *Br J Surg*. 2015;102:972–978.
273. De Caluwé L, Van Nieuwenhove Y, Ceelen WP. Preoperative chemoradiation versus radiation alone for stage II and III resectable rectal cancer. *Cochrane Database Syst Rev*. 2013;(2):CD006041.
274. Azria D, Doyen J, Jarlier M, et al. Late toxicities and clinical outcome at 5 years of the ACCORD 12/0405-PRODIGE 02 trial comparing two neoadjuvant chemoradiotherapy regimens for intermediate-risk rectal cancer. *Ann Oncol*. 2017;28:2436–2442.
275. Aschele C, Cionini L, Lonardi S, et al. Primary tumor response to preoperative chemoradiation with or without oxaliplatin in locally advanced rectal cancer: pathologic results of the STAR-01 randomized phase III trial. *J Clin Oncol*. 2011;29:2773–2780.
276. Allegra CJ, Yothers G, O’Connell MJ, et al. Neoadjuvant 5-FU or capecitabine plus radiation with or without oxaliplatin in rectal cancer patients: a phase III randomized clinical trial. *J Natl Cancer Inst*. 2015;107:djv248. doi: 10.1093/jnci/djv248
277. Deng Y, Chi P, Lan P, et al. Modified FOLFOX6 with or without radiation versus fluorouracil and leucovorin with radiation in neoadjuvant treatment of locally advanced rectal cancer: initial results of the Chinese FOWARC multicenter, open-label, randomized three-arm phase III trial. *J Clin Oncol*. 2016;34:3300–3307.
278. Rödel C, Graeven U, Fietkau R, et al; German Rectal Cancer Study Group. Oxaliplatin added to fluorouracil-based preoperative chemoradiotherapy and postoperative chemotherapy of locally advanced rectal cancer (the German CAO/ARO/AIO-04 study): final results of the multicentre, open-label, randomised, phase 3 trial. *Lancet Oncol*. 2015;16:979–989.
279. Perez K, Safran H, Sikov W, et al. Complete neoadjuvant treatment for rectal cancer: the Brown University Oncology Group CONTRE study. *Am J Clin Oncol*. 2017;40:283–287.
280. Fernandez-Martos C, Garcia-Albeniz X, Pericay C, et al. Chemoradiation, surgery and adjuvant chemotherapy versus induction chemotherapy followed by chemoradiation and surgery: long-term results of the Spanish GCR-3 phase II randomized trial†. *Ann Oncol*. 2015;26:1722–1728.
281. Fernández-Martos C, Pericay C, Aparicio J, et al. Phase II, randomized study of concomitant chemoradiotherapy followed by surgery and adjuvant capecitabine plus oxaliplatin (CAPOX) compared with induction CAPOX followed by concomitant chemoradiotherapy and surgery in magnetic resonance imaging-defined, locally advanced rectal cancer: Grupo cancer de recto 3 study. *J Clin Oncol*. 2010;28:859–865.

282. Marco MR, Zhou L, Patil S, et al; Timing of Rectal Cancer Response to Chemoradiation Consortium. Consolidation mFOLFOX6 chemotherapy after chemoradiotherapy improves survival in patients with locally advanced rectal cancer: final results of a multicenter phase II trial. *Dis Colon Rectum*. 2018;61:1146–1155.
283. Cercek A, Roxburgh CSD, Strombom P, et al. Adoption of total neoadjuvant therapy for locally advanced rectal cancer. *JAMA Oncol*. 2018;4:e180071.
284. Schrag D, Weiser MR, Goodman KA, et al. Neoadjuvant chemotherapy without routine use of radiation therapy for patients with locally advanced rectal cancer: a pilot trial. *J Clin Oncol*. 2014;32:513–518.
285. Weiser MR, Fichera A, Schrag D, Boughey JC, You YN. Progress in the PROSPECT trial: precision treatment for rectal cancer? *Bull Am Coll Surg*. 2015;100:51–52.
286. Martella A, Willett C, Palta M, Czito B. The selective use of radiation therapy in rectal cancer patients. *Curr Oncol Rep*. 2018;20:43.
287. Goodman KA, Patton CE, Fisher GA, et al. Appropriate customization of radiation therapy for stage II and III rectal cancer: executive summary of an ASTRO clinical practice statement using the RAND/UCLA appropriateness method. *Pract Radiat Oncol*. 2016;6:166–175.
288. Willett CG, Badizadegan K, Ancukiewicz M, Shellito PC. Prognostic factors in stage T3N0 rectal cancer: do all patients require postoperative pelvic irradiation and chemotherapy? *Dis Colon Rectum*. 1999;42:167–173.
289. Gunderson LL, Sargent DJ, Tepper JE, et al. Impact of T and N substage on survival and disease relapse in adjuvant rectal cancer: a pooled analysis. *Int J Radiat Oncol Biol Phys*. 2002;54:386–396.
290. Gunderson LL, Sargent DJ, Tepper JE, et al. Impact of T and N stage and treatment on survival and relapse in adjuvant rectal cancer: a pooled analysis. *J Clin Oncol*. 2004;22:1785–1796.
291. Baek JY, Yu JI, Park HC, et al. Risk factors for locoregional recurrence in patients with pathologic T3N0 rectal cancer with negative resection margin treated by surgery alone. *Radiat Oncol J*. 2019;37:110–116.
292. Guillem JG, Díaz-González JA, Minsky BD, et al. cT3N0 rectal cancer: potential overtreatment with preoperative chemoradiotherapy is warranted. *J Clin Oncol*. 2008;26:368–373.
293. Peeters KC, Marijnen CA, Nagtegaal ID, et al; Dutch Colorectal Cancer Group. The TME trial after a median follow-up of 6 years: increased local control but no survival benefit in irradiated patients with resectable rectal carcinoma. *Ann Surg*. 2007;246:693–701.
294. Clancy C, Flanagan M, Marinello F, O'Neill BD, McNamara D, Burke JP. Comparative oncologic outcomes of upper third rectal cancers: a meta-analysis. *Clin Colorectal Cancer*. 2019;18:e361–e367.
295. Taylor FG, Quirke P, Heald RJ, et al; MERCURY study group. Preoperative high-resolution magnetic resonance imaging can identify good prognosis stage I, II, and III rectal cancer best managed by surgery alone: a prospective, multicenter, European study. *Ann Surg*. 2011;253:711–719.
296. Kennedy ED, Simunovic M, Jhaveri K, et al. Safety and feasibility of using magnetic resonance imaging criteria to identify patients with “good prognosis” rectal cancer eligible for primary surgery: the phase 2 nonrandomized QuickSilver clinical trial. *JAMA Oncol*. 2019;5:961–966.
297. Park IJ, You YN, Agarwal A, et al. Neoadjuvant treatment response as an early response indicator for patients with rectal cancer. *J Clin Oncol*. 2012;30:1770–1776.
298. Trakarnsanga A, Gönen M, Shia J, et al. Comparison of tumor regression grade systems for locally advanced rectal cancer after multimodality treatment. *J Natl Cancer Inst*. 2014;106:dju248. doi: 10.1093/jnci/dju248..
299. Foster JD, Jones EL, Falk S, Cooper EJ, Francis NK. Timing of surgery after long-course neoadjuvant chemoradiotherapy for rectal cancer: a systematic review of the literature. *Dis Colon Rectum*. 2013;56:921–930.
300. Du D, Su Z, Wang D, Liu W, Wei Z. Optimal interval to surgery after neoadjuvant chemoradiotherapy in rectal cancer: a systematic review and meta-analysis. *Clin Colorectal Cancer*. 2018;17:13–24.
301. Wang XJ, Zheng ZR, Chi P, Lin HM, Lu XR, Huang Y. Effect of interval between neoadjuvant chemoradiotherapy and surgery on oncological outcome for rectal cancer: a systematic review and meta-analysis. *Gastroenterol Res Pract*. 2016;2016:6756859.
302. Lefevre JH, Mineur L, Kotti S, et al. Effect of interval (7 or 11 weeks) between neoadjuvant radiochemotherapy and surgery on complete pathologic response in rectal cancer: a multicenter, randomized, controlled trial (GRECCAR-6). *J Clin Oncol*. 2016;34:3773–3780.
303. André T, Boni C, Navarro M, et al. Improved overall survival with oxaliplatin, fluorouracil, and leucovorin as adjuvant treatment in stage II or III colon cancer in the MOSAIC trial. *J Clin Oncol*. 2009;27:3109–3116.
304. Kuebler JP, Wieand HS, O'Connell MJ, et al. Oxaliplatin combined with weekly bolus fluorouracil and leucovorin as surgical adjuvant chemotherapy for stage II and III colon cancer: results from NSABP C-07. *J Clin Oncol*. 2007;25:2198–2204.
305. Wolmark N, Wieand HS, Hyams DM, et al. Randomized trial of postoperative adjuvant chemotherapy with or without radiotherapy for carcinoma of the rectum: National Surgical Adjuvant Breast and Bowel Project Protocol R-02. *J Natl Cancer Inst*. 2000;92:388–396.
306. Hong YS, Nam BH, Kim KP, et al. Oxaliplatin, fluorouracil, and leucovorin versus fluorouracil and leucovorin as adjuvant chemotherapy for locally advanced rectal cancer after preoperative chemoradiotherapy (ADORE): an open-label, multicentre, phase 2, randomised controlled trial. *Lancet Oncol*. 2014;15:1245–1253.
307. Zhao L, Liu R, Zhang Z, et al. Oxaliplatin/fluorouracil-based adjuvant chemotherapy for locally advanced rectal cancer after neoadjuvant chemoradiotherapy and surgery: a systematic review and meta-analysis of randomized controlled trials. *Colorectal Dis*. 2016;18:763–772.
308. Petersen SH, Harling H, Kirkeby LT, Wille-Jørgensen P, Mocellin S. Postoperative adjuvant chemotherapy in rectal cancer operated for cure. *Cochrane Database Syst Rev*. 2012;(3):CD004078.
309. Petrelli F, Coiu A, Lonati V, Barni S. A systematic review and meta-analysis of adjuvant chemotherapy after neoadjuvant treatment and surgery for rectal cancer. *Int J Colorectal Dis*. 2015;30:447–457.
310. Turner MC, Keenan JE, Rushing CN, et al. Adjuvant chemotherapy improves survival following resection of locally ad-

- vanced rectal cancer with pathologic complete response. *J Gastrointest Surg.* 2019;23:1614–1622.
311. Ma B, Ren Y, Chen Y, et al. Is adjuvant chemotherapy necessary for locally advanced rectal cancer patients with pathological complete response after neoadjuvant chemoradiotherapy and radical surgery? A systematic review and meta-analysis. *Int J Colorectal Dis.* 2019;34:113–121.
  312. Dossa F, Acuna SA, Rickles AS, et al. Association between adjuvant chemotherapy and overall survival in patients with rectal cancer and pathological complete response after neoadjuvant chemotherapy and resection. *JAMA Oncol.* 2018;4:930–937.
  313. Alexander M, Blum R, Burbury K, et al. Timely initiation of chemotherapy: a systematic literature review of six priority cancers - results and recommendations for clinical practice. *Intern Med J.* 2017;47:16–34.
  314. Nachiappan S, Askari A, Mamidanna R, et al. Initiation of adjuvant chemotherapy within 8 weeks of elective colorectal resection improves overall survival regardless of reoperation. *Colorectal Dis.* 2016;18:1041–1049.
  315. Dos Santos LV, Faria TM, Lima AB, et al. Timing of adjuvant chemotherapy in colorectal cancer. *Colorectal Dis.* 2016;18:871–876.
  316. Kim IY, Kim BR, Kim YW. Factors affecting use and delay ( $\geq 8$  weeks) of adjuvant chemotherapy after colorectal cancer surgery and the impact of chemotherapy-use and delay on oncologic outcomes. *PLoS One.* 2015;10:e0138720.
  317. Malietzis G, Mughal A, Currie AC, et al. Factors implicated for delay of adjuvant chemotherapy in colorectal cancer: a meta-analysis of observational studies. *Ann Surg Oncol.* 2015;22:3793–3802.
  318. Gresham G, Cheung WY, Speers C, Woods R, Kennecke H. Time to adjuvant chemotherapy and survival outcomes among patients with stage 2 to 3 rectal cancer treated with preoperative chemoradiation. *Clin Colorectal Cancer.* 2015;14:41–45.
  319. Biagi JJ, Raphael MJ, Mackillop WJ, Kong W, King WD, Booth CM. Association between time to initiation of adjuvant chemotherapy and survival in colorectal cancer: a systematic review and meta-analysis. *JAMA.* 2011;305:2335–2342.
  320. Des Guetz G, Nicolas P, Perret GY, Morere JF, Uzzan B. Does delaying adjuvant chemotherapy after curative surgery for colorectal cancer impair survival? A meta-analysis. *Eur J Cancer.* 2010;46:1049–1055.
  321. André T, Iveson T, Labianca R, et al; for the IDEA Steering Committee. The IDEA (International Duration Evaluation of Adjuvant Chemotherapy) Collaboration: prospective combined analysis of phase III trials investigating duration of adjuvant therapy with the FOLFOX (FOLFOX4 or modified FOLFOX6) or XELOX (3 versus 6 months) regimen for patients with stage III colon cancer: trial design and current status. *Curr Colorectal Cancer Rep.* 2013;9:261–269.
  322. Grothey A, Sobrero AF, Shields AF, et al. Duration of adjuvant chemotherapy for stage III colon cancer. *N Engl J Med.* 2018;378:1177–1188.
  323. Lieu C, Kennedy EB, Bergsland E, et al. Duration of oxaliplatin-containing adjuvant therapy for stage III colon cancer: ASCO Clinical Practice Guideline. *J Clin Oncol.* 2019;37:1436–1447.
  324. Genovesi D, Myerson RJ, Céfaro GA, et al; G.I. A.I.R.O. Working Group. Postoperative 5-FU based radiochemotherapy in rectal cancer: retrospective long term results and prognostic factors of a pooled analysis on 1,338 patients. *Anticancer Res.* 2013;33:4557–4566.
  325. Glynne-Jones R, Wyrwicz L, Tiret E, et al; ESMO Guidelines Committee. Rectal cancer: ESMO Clinical Practice Guidelines for diagnosis, treatment and follow-up. *Ann Oncol.* 2018;29(suppl 4):iv263.
  326. Sebag-Montefiore D, Stephens RJ, Steele R, et al. Preoperative radiotherapy versus selective postoperative chemoradiotherapy in patients with rectal cancer (MRC CR07 and NCIC-CTG C016): a multicentre, randomised trial. *Lancet.* 2009;373:811–820.
  327. Fakih MG. Metastatic colorectal cancer: current state and future directions. *J Clin Oncol.* 2015;33:1809–1824.
  328. Engstrand J, Kartalis N, Strömberg C, et al. The impact of a hepatobiliary multidisciplinary team assessment in patients with colorectal cancer liver metastases: a population-based study. *Oncologist.* 2017;22:1067–1074.
  329. Chen CH, Hsieh MC, Lao WT, Lin EK, Lu YJ, Wu SY. Multidisciplinary team intervention associated with improved survival for patients with colorectal adenocarcinoma with liver or lung metastasis. *Am J Cancer Res.* 2018;8:1887–1898.
  330. Lowes M, Kleiss M, Lueck R, et al. The utilization of multidisciplinary tumor boards (MDT) in clinical routine: results of a health care research study focusing on patients with metastasized colorectal cancer. *Int J Colorectal Dis.* 2017;32:1463–1469.
  331. Pavlidis ET, Pavlidis TE. Role of bevacizumab in colorectal cancer growth and its adverse effects: a review. *World J Gastroenterol.* 2013;19:5051–5060.
  332. Aloia TA, Zimmitti G, Conrad C, Gottumukalla V, Kopetz S, Vauthey JN. Return to intended oncologic treatment (RIOT): a novel metric for evaluating the quality of oncosurgical therapy for malignancy. *J Surg Oncol.* 2014;110:107–114.
  333. Poultsides GA, Paty PB. Reassessing the need for primary tumor surgery in unresectable metastatic colorectal cancer: overview and perspective. *Ther Adv Med Oncol.* 2011;3:35–42.
  334. Faron M, Pignon JP, Malka D, et al. Is primary tumour resection associated with survival improvement in patients with colorectal cancer and unresectable synchronous metastases? A pooled analysis of individual data from four randomised trials. *Eur J Cancer.* 2015;51:166–176.
  335. Cirocchi R, Trastulli S, Abraha I, et al. Non-resection versus resection for an asymptomatic primary tumour in patients with unresectable stage IV colorectal cancer. *Cochrane Database Syst Rev.* 2012;(8):CD008997.
  336. Poultsides GA, Servais EL, Saltz LB, et al. Outcome of primary tumor in patients with synchronous stage IV colorectal cancer receiving combination chemotherapy without surgery as initial treatment. *J Clin Oncol.* 2009;27:3379–3384.
  337. McCahill LE, Yothers G, Sharif S, et al. Primary mFOLFOX6 plus bevacizumab without resection of the primary tumor for patients presenting with surgically unresectable metastatic colon cancer and an intact asymptomatic colon cancer: definitive analysis of NSABP trial C-10. *J Clin Oncol.* 2012;30:3223–3228.
  338. Lorimer PD, Motz BM, Kirks RC, et al. Frequency of unplanned surgery in patients with stage IV colorectal cancer receiving palliative chemotherapy with an intact primary: an analysis of SEER-Medicare. *J Surg Oncol.* 2019;120:407–414.
  339. Lumachi F, Chiara GB, Tozzoli R, Del Conte A, Del Conte A, Basso SM. Factors affecting survival in patients with lung me-

- tastases from colorectal cancer. a short meta-analysis. *Anticancer Res.* 2016;36:13–19.
340. Glockzin G, Zeman F, Croner RS, et al. Perioperative systemic chemotherapy, cytoreductive surgery, and hyperthermic intraperitoneal chemotherapy in patients with colorectal peritoneal metastasis: results of the prospective multicenter phase 2 COMBATAC trial. *Clin Colorectal Cancer.* 2018;17:285–296.
  341. Sánchez-Hidalgo JM, Rodríguez-Ortiz L, Arjona-Sánchez Á, et al. Colorectal peritoneal metastases: optimal management review. *World J Gastroenterol.* 2019;25:3484–3502.
  342. Jones RP, Poston GJ. Resection of liver metastases in colorectal cancer in the era of expanding systemic therapy. *Annu Rev Med.* 2017;68:183–196.
  343. Tsitsias T, Toufektzian L, Routledge T, Pilling J. Are there recognized prognostic factors for patients undergoing pulmonary metastasectomy for colorectal carcinoma? *Interact Cardiovasc Thorac Surg.* 2016;23:962–969.
  344. Nordlinger B, Sorbye H, Glimelius B, et al; EORTC Gastro-Intestinal Tract Cancer Group; Cancer Research UK; Arbeitsgruppe Lebermetastasen und-tumoren in der Chirurgischen Arbeitsgemeinschaft Onkologie (ALM-CAO); Australasian Gastro-Intestinal Trials Group (AGITG); Fédération Francophone de Cancérologie Digestive (FFCD). Perioperative FOLFOX4 chemotherapy and surgery versus surgery alone for resectable liver metastases from colorectal cancer (EORTC 40983): long-term results of a randomised, controlled, phase 3 trial. *Lancet Oncol.* 2013;14:1208–1215.
  345. Wang L, Sun Y, Zhao B, Zhang H, Yu Q, Yuan X. Chemotherapy plus targeted drugs in conversion therapy for potentially resectable colorectal liver metastases: a meta-analysis. *Oncotarget.* 2016;7:55732–55740.
  346. Overman MJ, Ferrarotto R, Raghav K, et al. The addition of bevacizumab to oxaliplatin-based chemotherapy: impact upon hepatic sinusoidal injury and thrombocytopenia. *J Natl Cancer Inst.* 2018;110:888–894.
  347. Zorzi D, Laurent A, Pawlik TM, Lauwers GY, Vauthey JN, Abdalla EK. Chemotherapy-associated hepatotoxicity and surgery for colorectal liver metastases. *Br J Surg.* 2007;94:274–286.
  348. Vauthey JN, Pawlik TM, Ribero D, et al. Chemotherapy regimen predicts steatohepatitis and an increase in 90-day mortality after surgery for hepatic colorectal metastases. *J Clin Oncol.* 2006;24:2065–2072.
  349. Tzeng CW, Vauthey JN. Postoperative complications and oncologic outcomes after resection of colorectal liver metastases: the importance of staying on track. *Ann Surg Oncol.* 2013;20:2457–2459.
  350. Conrad C, Vauthey JN, Masayuki O, et al. Individualized treatment sequencing selection contributes to optimized survival in patients with rectal cancer and synchronous liver metastases. *Ann Surg Oncol.* 2017;24:3857–3864.
  351. Baltatzis M, Chan AK, Jegatheeswaran S, Mason JM, Siriwardena AK. Colorectal cancer with synchronous hepatic metastases: Systematic review of reports comparing synchronous surgery with sequential bowel-first or liver-first approaches. *Eur J Surg Oncol.* 2016;42:159–165.
  352. Shubert CR, Habermann EB, Bergquist JR, et al. A NSQIP review of major morbidity and mortality of synchronous liver resection for colorectal metastasis stratified by extent of liver resection and type of colorectal resection. *J Gastrointest Surg.* 2015;19:1982–1994.
  353. Silberhumer GR, Paty PB, Denton B, et al. Long-term oncologic outcomes for simultaneous resection of synchronous metastatic liver and primary colorectal cancer. *Surgery.* 2016;160:67–73.
  354. Butte JM, Gonen M, Ding P, et al. Patterns of failure in patients with early onset (synchronous) resectable liver metastases from rectal cancer. *Cancer.* 2012;118:5414–5423.
  355. Sager O, Dincoglan F, Demiral S, et al. A concise review of pelvic radiation therapy (RT) for rectal cancer with synchronous liver metastases. *Int J Surg Oncol.* 2019;2019:5239042.
  356. Holliday EB, Hunt A, You YN, et al. Short course radiation as a component of definitive multidisciplinary treatment for select patients with metastatic rectal adenocarcinoma. *J Gastrointest Oncol.* 2017;8:990–997.
  357. Glasgow SC, Morris AM, Baxter NN, et al. Development of The American Society of Colon and Rectal Surgeons' Rectal Cancer Surgery Checklist. *Dis Colon Rectum.* 2016;59:601–606.
  358. Maniar RL, Sytnik P, Wirtzfeld DA, et al. Synoptic operative reports enhance documentation of best practices for rectal cancer. *J Surg Oncol.* 2015;112:555–560.
  359. Bidwell SS, Merrell SB, Poles G, Morris AM; Synoptic Operative Report Study Group. Implementation of a synoptic operative report for rectal cancer: a mixed-methods study. *Dis Colon Rectum.* 2020;63:190–199.
  360. Washington MK, Berlin J, Branton P, et al; Members of the Cancer Committee, College of American Pathologists. Protocol for the examination of specimens from patients with primary carcinoma of the colon and rectum. *Arch Pathol Lab Med.* 2009;133:1539–1551.
  361. Sluijter CE, van Lonkhuijzen LR, van Slooten HJ, Nagtegaal ID, Overbeek LI. The effects of implementing synoptic pathology reporting in cancer diagnosis: a systematic review. *Virchows Arch.* 2016;468:639–649.
  362. Guyatt G, Gutterman D, Baumann MH, et al. Grading strength of recommendations and quality of evidence in clinical guidelines: report from an American College of Chest Physicians task force. *Chest.* 2006;129:174–181.