

infections, however, might follow different patterns (10). For example, higher macrolide use among white persons might lead to macrolide resistance in a greater proportion of *Streptococcus pneumoniae* bacteria carried by whites, but if white persons have fewer *S. pneumoniae* infections, then they would incur a lower absolute rate of macrolide-resistant *S. pneumoniae* infections. Further studies comparing antimicrobial drug use, antimicrobial drug resistance, and disease prevalence by race/ethnicity will be critical for addressing this question and improving antimicrobial drug stewardship.

S.W.O. was supported by cooperative agreement U54GM088558 from the National Institute of General Medical Sciences.

About the Author

Dr. Olesen is a postdoctoral fellow at the Harvard T.H. Chan School of Public Health, Boston, Massachusetts, USA. His research interests include antimicrobial drug use and resistance. Dr. Grad is the Melvin J. and Geraldine L. Glimcher Assistant Professor of Immunology and Infectious Diseases at the Harvard T.H. Chan School of Public Health. His research interests include antimicrobial drug use and resistance and the evolution and spread of pathogens.

References

- Hicks LA, Bartoces MG, Roberts RM, Suda KJ, Hunkler RJ, Taylor TH Jr, et al. US outpatient antibiotic prescribing variation according to geography, patient population, and provider specialty in 2011. *Clin Infect Dis*. 2015;60:1308–16.
- Goyal MK, Johnson TJ, Chamberlain JM, Casper TC, Simmons T, Alessandrini EA, et al.; Pediatric Care Applied Research Network. Racial and ethnic differences in antibiotic use for viral illness in emergency departments. *Pediatrics*. 2017;140:e20170203. <http://dx.doi.org/10.1542/peds.2017-0203>
- Steinman MA, Landefeld CS, Gonzales R. Predictors of broad-spectrum antibiotic prescribing for acute respiratory tract infections in adult primary care. *JAMA*. 2003;289:719–25. <http://dx.doi.org/10.1001/jama.289.6.719>
- Gerber JS, Prasad PA, Localio AR, Fiks AG, Grundmeier RW, Bell LM, et al. Racial differences in antibiotic prescribing by primary care pediatricians. *Pediatrics*. 2013;131:677–84. <http://dx.doi.org/10.1542/peds.2012-2500>
- Hill SC, Roemer M, Stagnitti MN. Methodology report #29. Outpatient prescription drugs: data collection and editing in the 2011 medical expenditure panel survey. 2014 Mar [cited 2018 May 7]. https://meps.ahrq.gov/data_files/publications/mr29/mr29.shtml
- Hill SC, Zuvekas SH, Zodet MW. Implications of the accuracy of MEPS prescription drug data for health services research. *Inquiry*. 2011;48:242–59. <http://dx.doi.org/10.5034/inquiryjml.48.03.04>
- Zoorob R, Grigoryan L, Nash S, Trautner BW. Nonprescription antimicrobial use in a primary care population in the United States. *Antimicrob Agents Chemother*. 2016;60:5527–32. <http://dx.doi.org/10.1128/AAC.00528-16>
- Tamblyn R, Eguale T, Huang A, Winslade N, Doran P. The incidence and determinants of primary nonadherence with prescribed medication in primary care: a cohort study. *Ann Intern Med*. 2014;160:441–50. <http://dx.doi.org/10.7326/M13-1705>
- Fleming-Dutra KE, Hersh AL, Shapiro DJ, Bartoces M, Enns EA, File TM Jr, et al. Prevalence of inappropriate antibiotic prescriptions among US ambulatory care visits, 2010–2011. *JAMA*. 2016;315:1864–73. <http://dx.doi.org/10.1001/jama.2016.4151>
- Kanjilal S, Sater MRA, Thayer M, Lagoudas GK, Kim S, Blainey PC, et al. Trends in antibiotic susceptibility in *Staphylococcus aureus* in Boston, Massachusetts, from 2000 to 2014. *J Clin Microbiol*. 2017;56:e01160-17. <http://dx.doi.org/10.1128/JCM.01160-17>

Address for correspondence: Yonatan H. Grad, Harvard T. H. Chan School of Public Health, 665 Huntington Ave, Bldg 1, Rm 715, Boston, MA 02115, USA; email: ygrad@hsph.harvard.edu

Congenital Zika Virus Infection with Normal Neurodevelopmental Outcome, Brazil

Alessandra Lemos de Carvalho, Carlos Brites, Tânia Barreto Taguchi, Suelly Fernandes Pinho, Gúbio Campos, Rita Lucena

Author affiliations: SARAH Network of Rehabilitation Hospitals, Salvador, Brazil (A.L. de Carvalho, T.B. Taguchi, S.F. Pinho); Federal University of Bahia, Salvador (C. Brites, G. Campos, R. Lucena)

DOI: <https://doi.org/10.3201/eid2411.180883>

We describe a case of a 20-month-old girl with probable congenital Zika virus infection and normal neurodevelopment, despite microcephaly and abnormal neuroimaging. This case raises questions about early prognostic markers and draws attention to the need for investigation in suspected Zika cases, even if the child's early neurodevelopment is normal.

Zika virus is a mosquito-borne RNA virus (genus *Flavivirus*, family *Flaviviridae*) that was first isolated in 1947 from monkeys in the Zika Forest in Uganda (1). In November 2015, there was an outbreak of congenital microcephaly in the northeast states of Brazil (2). Further confirmation of this syndrome's relationship with Zika virus infection during pregnancy was then possible (3). Congenital Zika syndrome has been recognized as a new clinical entity (4,5). Most published case series focus on the picture of severely affected infants (6,7). We describe a case of a child with probable congenital Zika virus infection whose neurodevelopment was normal, despite

microcephaly and abnormal neuroimaging. The mother provided written informed consent for this report.

The patient, a girl, was born at 36 weeks, 4 days' gestation; Apgar scores were 8 at first minute and 9 at fifth minute. There was no family history of microcephaly, and the parents were phenotypically normal. The pregnancy occurred during Brazil's Zika virus epidemic and the mother lived in Bahia, the state where the virus was first detected and one of the most affected areas. She was 27 years of age, in her third pregnancy, and had a history of rash at 12 weeks' gestation, followed by fever, headache, arthralgia, and conjunctivitis. She recovered after 1 week, without a specific diagnosis. At 24 weeks' gestation, a routine ultrasound exam detected microcephaly in the fetus. Testing for HIV, human T-lymphotropic virus, cytomegalovirus, toxoplasmosis, rubella, syphilis, and hepatitis B and C in the mother yielded negative results. She had no further complications except for high blood pressure detected 3 days before delivery, the discovery of which led to an elective cesarean section.

At birth, the infant's weight was 2,496 g (-0.6 SD), length was 45 cm (-1.1 SD), and head circumference was 29.5 cm (-2.4 SD) (8). She had no neonatal complications and was breast-fed without difficulty. Test results were negative for chikungunya, dengue, rubella, toxoplasmosis, cytomegalovirus, parvovirus B19, and herpes virus I and II. However, serum testing (EuroImmun, Lubeck, Germany) showed positive results for Zika virus IgM. Results of biochemical analysis of cerebrospinal fluid, abdominal ultrasound, and neonatal metabolic screening were all normal, as were ophthalmologic and auditory evaluations. Transfontanellar ultrasound showed focal calcification in basal ganglia that was more pronounced

in the right hemisphere. Results of cerebral computed tomography conducted during the neonatal period showed mild craniofacial disproportion, slightly decreased brain volume, and small calcifications in the right nucleocapsular area and around the left thalamus.

In January 2016, at 6 months of age, the patient entered a neurorehabilitation program, during which she reached normal achievement of developmental milestones. Further investigation included a videoelectroencephalogram and auditory and visual evoked potentials; results were all normal. We diagnosed probable congenital Zika virus infection, considering the gestational history, congenital microcephaly, positive serologic test results, and neuroradiological findings, which were mild but consistent with Zika virus infection. A follow-up cerebral scan performed at 7 months of age showed mild calcifications at the right lenticular nucleus and posterior arm of the left internal capsule (Figure).

The patient started to walk independently at 13 months of age, and her gait pattern did not show any abnormality. We performed a follow-up assessment at 20 months of age. Neurologic examination was normal, except for microcephaly (head circumference 42.5 cm, -3 SD) (9). Weight was within reference range (8.7 kg, between -1 and -2 SD), but length was below reference values (74 cm, between -2 and -3 SD). The child was otherwise healthy. We performed developmental evaluation using Bayley-III Scales of Infant Development (10). All composite scores were within average classification (online Technical Appendix, <https://wwwnc.cdc.gov/EID/article/24/11/18-0883-Techapp1.pdf>).

Neurodevelopment is a dynamic process that depends on the interaction between neurobiological and

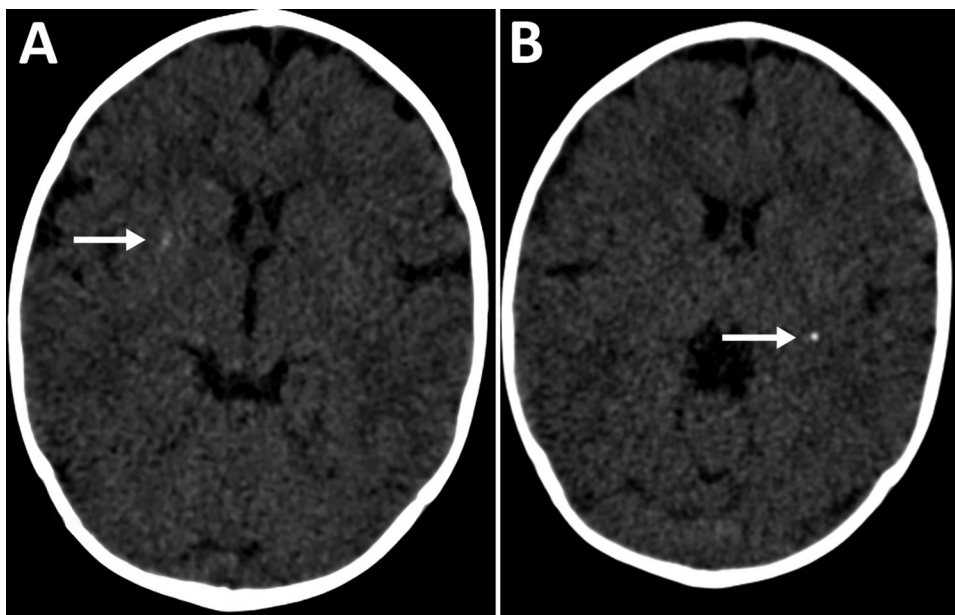


Figure. Cerebral computed tomography images of infant with probable congenital Zika virus infection at 7 months of age, Brazil. A) Mild calcification at the right lenticular nucleus (arrow); B) calcifications at the posterior arm of the left internal capsule (arrow).

environmental factors. Children initially developing within the expected range for their age group may experience a slowdown as demands of neurodevelopment become more extensive. We cannot make inferences about long-term prognosis from the patient's condition at 20 months of age. Developmental evolution should be determined prospectively, using the same instrument so that results can be compared over time.

This report has 2 main limitations. First, molecular confirmation of Zika virus infection in the mother or the child was not possible. Second, we did not perform PCR or culture for cytomegalovirus. Nevertheless, the child's Zika virus IgM was positive in the neonatal period, and her mother's clinical symptoms suggested Zika virus infection during pregnancy, which occurred during the Zika virus epidemic in Brazil, in one of the most affected areas.

This case may indicate a broader spectrum in congenital Zika syndrome, raising questions about early prognostic markers. Our findings draw attention to the need for detailed evaluation even for typically developing children with possible congenital Zika virus infection who receive medical attention later.

Acknowledgment

We thank Silvia Ines Sardi for technical contributions on Zika serology performance.

No external funding was used for this study. G.C. received a "Zika fast track grant" provided by Coordination for the Improvement of Higher Education Personnel (CAPES), Brazil, to perform ELISA testing for Zika virus in the neonatal period. This institution had no role in study design, data collection and analysis, decision to publish, or preparation of this manuscript. The other authors have no financial disclosures relevant to this article.

About the Author

Dr. Carvalho is a pediatrician at the Child Rehabilitation Center of SARA Network of Rehabilitation Hospitals, Salvador Unit. She is currently a master's degree student at the Postgraduate Program in Medicine and Health, Federal University of Bahia, Bahia, Brazil. Her primary clinical practice and research interests are in cerebral palsy and congenital Zika virus infection.

References

1. Dick GWA, Kitchen SF, Haddock AJ. Zika virus. I. Isolations and serological specificity. *Trans R Soc Trop Med Hyg.* 1952;46: 509–20. [http://dx.doi.org/10.1016/0035-9203\(52\)90042-4](http://dx.doi.org/10.1016/0035-9203(52)90042-4)
2. Pan American Health Organization; World Health Organization. Epidemiological update: Neurological syndrome, congenital anomalies, and Zika virus infection. 2016 Jan 17 [cited 2018 Sep 19]. <https://www.paho.org/hq/dmdocuments/2016/2016-jan-17-cha-epi-update-zika-virus.pdf>
3. de Araújo TVB, Ximenes RAA, Miranda-Filho DB, Souza WV, Montarroyos UR, de Melo APL, et al. Association between microcephaly, Zika virus infection, and other risk factors in Brazil: final report of a case-control study. *Lancet Infect Dis.* 2018;18:328–36.
4. del Campo M, Feitosa IML, Ribeiro EM, Horovitz DDG, Pessoa ALS, França GVA, et al.; Zika Embryopathy Task Force-Brazilian Society of Medical Genetics ZETF-SBGM. The phenotypic spectrum of congenital Zika syndrome. *Am J Med Genet A.* 2017;173:841–57. <http://dx.doi.org/10.1002/ajmg.a.38170>
5. Moore CA, Staples JE, Dobyns WB, Pessoa A, Ventura CV, Fonseca EB, et al. Characterizing the pattern of anomalies in congenital Zika syndrome for pediatric clinicians. *JAMA Pediatr.* 2017;171:288–95. <http://dx.doi.org/10.1001/jamapediatrics.2016.3982>
6. Schuler-Faccini L, Ribeiro EM, Feitosa IML, Horovitz DDG, Cavalcanti DP, Pessoa A, et al.; Brazilian Medical Genetics Society–Zika Embryopathy Task Force. Possible association between Zika virus infection and microcephaly—Brazil, 2015. *MMWR Morb Mortal Wkly Rep.* 2016;65:59–62. <http://dx.doi.org/10.15585/mmwr.mm6503e2>
7. Moura da Silva AA, Ganz JSS, Sousa PD, Doriqui MJR, Ribeiro MRC, Branco MD, et al. Early growth and neurologic outcomes of infants with probable congenital Zika virus syndrome. *Emerg Infect Dis.* 2016;22:1953–6. <http://dx.doi.org/10.3201/eid2211.160956>
8. Villar J, Cheikh Ismail L, Victora CG, Ohuma EO, Bertino E, Altman DG, et al. International standards for newborn weight, length, and head circumference by gestational age and sex: the newborn cross-sectional study of the INTERGROWTH-21st Project. *Lancet.* 2014;384:857–68. [https://doi.org/10.1016/S0140-6736\(14\)60932-6](https://doi.org/10.1016/S0140-6736(14)60932-6)
9. World Health Organization Multicentre Growth Reference Study Group. WHO child growth standards: length/height-for-age, weight-for-age, weight-for-length, weight-for-height, and body mass index-for-age: methods and development. Geneva: The Organization; 2006 [cited 2018 Aug 14]. http://www.who.int/childgrowth/standards/technical_report/en
10. Bayley N. Bayley scales of infant and toddler development. 3rd ed. San Antonio (TX, USA); Psychological Corp.; 2005.

Address for correspondence: Alessandra Lemos de Carvalho, SARA Salvador Hospital, Av Tancredo Neves, 2782, Caminho das Árvores, Salvador, BA 41820-900, Brazil; email: alessandracarvalhoped@gmail.com

Congenital Zika Virus Infection with Normal Neurodevelopmental Outcome, Brazil

Technical Appendix

Results, Bayley-III Scales of Infant and Toddler Development

Cognitive subtest: Raw score of 56, Scaled score of 11, Composite score of 105.

Language subtest: Raw score of 20 for Receptive Language, Raw score of 21 for Expressive Language, Scaled score of 9 for both Receptive and Expressive Language, Composite score of 94.

Motor subtest: Raw score of 36 for Fine Motor, Raw score of 53 for Gross Motor, Scaled score of 11 for Fine Motor, Scaled score of 10 for Gross Motor, Composite score of 103.