



January 2023

ELDER CARE

A Resource for Interprofessional Providers

Dentures

Ann Garcia MD Medical Director for Geriatric Medicine CHRISTUS St Vincent's Medical Center, Darlene Moyer MD, HonorHealth Scottsdale Osborn Family Medicine Residency Program, Bilal Shafi DDS, College of Dental Medicine, Midwestern University

Many older adults suffer from poor dentition, and dental care is a major geriatric concern. Tooth loss can be caused by periodontal disease, tooth decay, and trauma. Other contributing factors can include drug and tobacco abuse, poor access to dental services, lack of knowledge about proper dental care, and lack of financial resources.

Edentulism is defined as the loss of all permanent teeth. It is an irreversible condition that is the final stage of poor oral health. Edentulism is an important topic in geriatric care because not only does it usually reflect poor oral health, it can also have significant influence on overall health, nutrition, verbal communication, and self-confidence.

Edentulism is common. CDC data indicate that about one-quarter of adults over age 60 have no natural teeth. Dentures are one option that patients have for dealing with tooth loss. Dentures are not only important for aesthetic purposes but also for mastication (chewing), speech, oral maxillofacial structure, and nutrition.

Complete Dentures

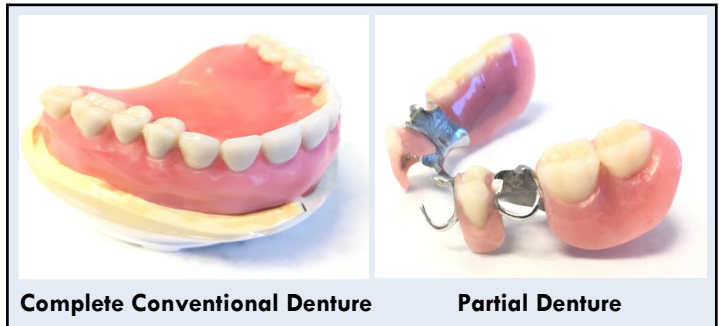
There are two types of dentures - complete and partial. Complete dentures can be "conventional" or "immediate."

Conventional complete dentures are made and fitted after teeth have been removed and the alveolar tissue has had time to heal. This process can take between 8-12 weeks and many patients find it unappealing to wait that long.

Immediate complete dentures are made in advance and can be placed as soon as the teeth are removed. Although this option is cosmetically appealing, it is only a temporary solution. After tooth removal, the bone and gingival structure changes drastically and multiple adjustments need to be made to accommodate those structural changes.

Partial Dentures

Partial dentures are used when one or more teeth remain in the jaw. Therefore, not all teeth need to be replaced. Partial dentures can be fixed or removable. Fixed partial dentures, also known as a bridge, are used when replacement teeth are cemented to neighboring teeth.



Complete Conventional Denture

Partial Denture

Removable (flexible) partial dentures are typically more affordable and consist of a prosthesis that can be removed and reinserted by the patient. Partial dentures fill the space in between missing teeth, helping to prevent other teeth from changing position. Because they are removable, they can be easily cleaned.

Alternatives to Dentures

Dental implants are an alternative to dentures. Implants are artificial teeth that are surgically anchored into bone and are not removable. In addition to being able to replace individual teeth, implants may also be used in conjunction with dentures, offering better retention, support, and bone maintenance than traditional prostheses. Not all patients are good candidates for implants and many cannot afford their high cost. Patients who are heavy smokers, use bisphosphonates, have poorly controlled diabetes, or have poor bone availability are less-ideal candidates for implants.

Cost

A set of upper and lower complete dentures typically costs \$1,000-\$2,000. Partial dentures are around \$800-\$2,000 per arch. Denture prices can vary, however, depending on case complexity as well as tooth and material selection. A single tooth implant costs, on average, \$1,000-\$2,000. Additional diagnostic, imaging, and surgical fees may also apply, depending on the case.

TIPS ABOUT DENTURE CARE

- If patients have loose dentures, pain, or other problems related to dentures, they should promptly return to their dental provider for evaluation - ideally to the same dentist who made the dentures.
- Dentures require monitoring and adjustment over time and are very individualized.
- Tooth loss and poorly fitting dentures lead to bone loss and can result in difficulty molding and fitting dentures if not addressed promptly.

ELDER CARE

Continued from front page

Daily Care and Handling

Dentures should be rinsed with running water after every meal to remove loose food debris. Patients should brush them daily with a soft-bristled toothbrush designed for cleaning dentures. Patients should also perform routine oral care after removing the dentures. This involves cleaning the gums, natural teeth, tongue, and palate with a soft-bristled toothbrush or gauze.

Patients should also receive instructions from their dentist about proper care and handling of dentures. Some general rules are that dentures should be handled carefully because attachment points and clasps can break during cleaning. Another important recommendation is to place a towel below the dentures during cleaning so that dentures won't break if inadvertently dropped onto a hard surface.

Storage

Dentures should be kept in a moist environment when not being worn. They should be soaked overnight, preferably in a denture cleansing solution. Studies indicate soaking dentures overnight in alkaline peroxide-based cleansing solution or water reduces *Candida* and bacteria levels on the denture surface in comparison to dry storage.

Things to Avoid

Patients should avoid using hard-bristled toothbrushes, toothpaste, household cleaners, or bleach for denture cleaning as they may damage dentures. Hot water can warp dentures and should also be avoided.

Complications

Some of the most common complications of dentures include traumatic ulcers, gingival hyperplasia, denture stomatitis, loss of denture retention, denture breakage, and trouble chewing or speaking due to abnormal fit. The table below reviews the most frequent complications and how to trouble-shoot them for your patients.

Routine Follow Up

Ongoing follow-up with the same dental provider who made the denture is strongly recommended. Over the long term, patients should visit a dentist every 6 months to assess fit and assure that dentures are receiving proper care. Poor-fitting dentures can lead to bone loss over time, resulting in still worse fit and often making the dentures unusable. Dentures will require adjustments due to normal wear and changes in weight, but complete dentures should last 5-7 years before replacement is necessary.

TABLE - COMPLICATIONS AND MANAGEMENT OF DENTURES

Complications	Cause	Clinical Features	Differential	Management
Traumatic ulcers: Small, painful mucosal lesions that most commonly develop in the first days after insertion of a new denture	Ill-fitting dentures with overextended flanges, unbalanced occlusion or small excess of material, friction points at the frenulum or muscular attachments of the mouth.	Painful mucosal ulcerations have a yellowish floor and red margins, with no hardening or thickening of oral tissues. The irregularly shaped lesions are usually localized to the buccal and lingual sulcus.	Squamous cell carcinoma, bacterial, fungal and viral diseases, and other oral mucosal diseases	Denture removal. Ulcers usually heal in about a week. For symptomatic relief, recommend benzamine hydrochloride 0.15% mouthwash or spray. Use chlorhexidine gluconate 0.2% mouthwash for oral rinses and soak the dentures overnight to prevent and treat infection. Patients should see a dentist if ulcers reoccur, or last longer than a week, so that dentures can be adjusted to relieve pressure.
Denture-related hyperplasia: Enlargement of the oral mucosa	Reaction to low-grade continuous chronic trauma induced by denture flanges, which have thin, sharp edges.	Reactive mucosal enlargement	Fibrous hyperplasia vs inflammatory papillary hyperplasia	Patients should see their dental provider for adjustments to their dentures. The hyperplasia resolves almost entirely after removal of the cause. Sometimes minor surgery is required.
Denture stomatitis: Chronic infectious inflammatory disease of the oral mucosa directly contacting dentures	Infections with <i>Candida</i> , <i>Staphylococcus</i> , <i>Streptococcus</i> and sometimes irritation from medications.	Asymptomatic inflammatory lesions, with erythema and edema (without plaques) that are found in the denture-bearing area, more frequently in the maxillary surface.	Squamous cell carcinoma, traumatic ulcers	Adopting strict methods for oral and denture hygiene, with removal of the denture overnight and soaking it in an antiseptic solution. Patients should see a dental provider if it persists.

References and Resources

- Duyck J, Vandamme K, Muller P, Teughels. Overnight storage of removable dentures in alkaline peroxide-based tablets affects biofilm mass and composition. *J Dentistry*. 2013;41(12):1281-1289.
- Felton D, et al. Evidence-based guidelines for the care and maintenance of complete dentures: A publication of the American College of Prosthodontists. *J Am Dental Assoc*. 2011;142:1S.
- Kapner, M. Denture Problems. 2016. <https://medlineplus.gov/ency/article/002037.htm>
- Preoteasa, E., Preoteasa, C., Iosif, L., Magureanu, C. & Imre, M. 2015. Denture and Overdenture Complications. In *Emerging Trends in Oral Health Sciences and Dentistry*. <http://cdn.intechopen.com/pdfs-wm/47861.pdf>

Interprofessional care improves the outcomes of older adults with complex health problems.

Editors: Mindy Fain, MD; Jane Mohler, NP-c, MPH, PhD; and Barry D. Weiss, MD

Interprofessional Associate Editors: Tracy Carroll, PT, CHT, MPH; David Coon, PhD; Marilyn Gilbert, MS, CHES; Teri Kennedy, PhD, MSW, LCSW, ACSW; Jeannie Lee, PharmD, BCPS; Marisa Menchola, PhD; Francisco Moreno, MD; Lisa O'Neill, MPH; Floribella Redondo; Laura Vitkus, BA

The University of Arizona, PO Box 245069, Tucson, AZ 85724-5069 | (520) 626-5800 | <http://aging.arizona.edu>

Supported by: Donald W. Reynolds Foundation, Arizona Geriatrics Workforce Enhancement Program and the University of Arizona Center on Aging

This project was supported by the Health Resources and Services Administration (HRSA) of the U.S. Department of Health and Human Services (HHS) under grant number U1QHP28721, Arizona Geriatrics Workforce Enhancement Program. This information or content and conclusions are those of the author and should not be construed as the official position or policy of, nor should any endorsements be inferred by HRSA, HHS or the U.S. Government.