



EQUINE DISEASE QUARTERLY

FUNDED BY UNDERWRITERS AT LLOYD'S, LONDON

APRIL 2020
Volume 29, Number 2



COMMENTARY

IN THIS ISSUE

Commentary

International

Fourth Quarter
2019..... 2

Epiglottic
Entrapment..... 3

National

Equine Abortion 4

Kentucky

Nocardioform
Placentitis..... 4

One benefit of being older is the ability to reflect on many equine medical crises. Contagious equine metritis was the first notable crisis of my career, but I have unfortunately witnessed numerous others including: equine viral arteritis, leptospirosis, mare reproductive loss syndrome, track breakdowns, and more recently nocardioform placentitis. With each of these crises, scientists have stepped up to search for solutions, and I have seen first-hand the positive results that take place when practitioners work with scientists on the medical issues facing our horses.

This year central Kentucky has again been confronted with a substantial increase in the number of nocardioform placentitis cases. As with any case of placentitis, and certainly with nocardioform placentitis, the first clinical sign that the mare's pregnancy may be compromised is evident with "bagging up" early, which is horseman's lingo for premature lactation or increased udder size. Unlike ascending placentitis, there is usually no vulvar discharge in mares with nocardioform placentitis.

For the most part, it is relatively easy to diagnose nocardioform placentitis after the mare has either aborted or foaled, as the placenta is usually covered by a very characteristic brown mucoid discharge—many people think it looks like peanut butter. A diagnosis of nocardioform placentitis is more challenging before the mare delivers her foal (or fetus) and is made based on clinical signs

and abdominal ultrasound scans. Nocardioform placentitis frequently forms lesions on the ventral aspect of the placenta. This unique location negates the usefulness of the standard placentitis ultrasound measurement of the combined thickness of the uterus and placenta (CTUP), which is taken by rectal ultrasound of the uterus and placenta near the cervix.

With suspect nocardioform placentitis cases, one may see a range of abnormalities on trans-abdominal ultrasound scans. These include pockets of separation with apparent exudate between the uterus and placenta and signs of placental inflammation. It is important to note that not all lesions will be apparent by this method, and placental examination for lesions should still be done after abortion or parturition.

The greatest incidence of nocardioform placentitis occurs in December, January, and February. As we enter March, the number of cases should soon decrease. While we have unfortunately seen an increased incidence of nocardioform placentitis this year, one positive is that more cases have been examined and increased samples have been collected to better understand this unique condition.

CONTACT:

Tom Riddle, DVM
triddle@roodandriddle.com
(859) 233-0371
Rood and Riddle Equine Hospital
Lexington, Kentucky



College of Agriculture,
Food and Environment
Department of
Veterinary Science

LLOYD'S

Lloyd's—An international
insurance market for
bloodstock and other
specialist insurance.



Fourth Quarter 2019

The International Collating Centre, Newmarket, United Kingdom, and other sources reported the following equine disease outbreaks.

The Republic of South Africa (RSA) reported sporadic cases of African Horse Sickness in Free State, Gauteng, and North West Province. These represented the first cases recorded in the 2019/2020 season.

Three separate outbreaks of glanders were confirmed in Turkey. These were associated with illegal movement of horses without identification or veterinary certification. Of 1,375 horses tested, 63 were positive and 18 suspect; all were euthanized.

Equine influenza was confirmed in France, Germany, the Netherlands, the UK, and the USA. With the exception of the USA, the number of outbreaks ranged from 1-3, the majority in unvaccinated horses. The disease is endemic in the USA, with outbreaks diagnosed in seven states and multiple outbreaks in one state.

Belgium, France, Germany, the Netherlands, Switzerland, and the USA recorded strangles. The number of outbreaks varied from four (Belgium), 21 (France), three (Germany), 12 (the Netherlands), one (Switzerland) to 40 in the USA, where the disease is endemic.

Equine herpesvirus 1 (EHV-1) related diseases were recorded by Belgium, Canada, France, Germany, the Netherlands, RSA, UK, and the USA. Respiratory disease outbreaks were diagnosed in France (two), the Netherlands (one), RSA (one), UK (four), and in several states in the USA. EHV-1 abortion was reported by France (one case) and the Netherlands (one case). EHV-1 neurologic disease was confirmed in Belgium (one outbreak involving five horses), Canada (two cases), France (two outbreaks), Germany (one case), the Netherlands (three outbreaks, one involving 11 affected horses and the other two, single cases), and the USA (17 outbreaks in 10 states, one involving eight cases and the remainder, single cases).

Equine herpesvirus 4 (EHV-4) respiratory disease outbreaks were reported by France (41, the majority involving single cases), Germany (three, all single cases), Japan (one outbreak involving two horses), the Netherlands (five, involving one to five animals apiece), and the UK (11). While the majority were represented by single cases, one

outbreak involved 32 weanlings and another eight yearlings. France (two outbreaks) and the USA (three outbreaks) reported single cases of EHV-4 abortion. Numerous cases of EHV-2 and EHV-5 infection were confirmed by the USA, a percentage of which were associated with clinical respiratory disease.

France and the USA reported two outbreaks of equine infectious anemia apiece. Each involved a single case.

Only a single report of equine piroplasmiasis was received in the fourth quarter of 2019. The RSA reported that the disease was endemic throughout the country.

A total of 19 cases of nocardioform placentitis and abortion were diagnosed in Kentucky, USA during the period under review. A range of bacterial organisms were identified with cases of the disease. Contagious equine metritis was reported by several countries. Denmark, France and Germany each detected *Taylorella equigenitalis* in a stallion. South Korea recorded three positive animals out of 2,269 samples tested, the gender of the animals was not identified.

Other causes of abortion reported by Kentucky, USA included *Neorickettsia risticii* (two cases).

The USA recorded one case of *Salmonella* infection in Kentucky; several cases of rotavirus infection in three states, two involving strains of the G3 genotype and four the G14 genotype; nine cases of *Lawsonia* enteropathy; and 10 cases of infection with *Clostridium perfringens* Toxin A genotype.

Eastern equine encephalomyelitis (EEE) was reported by the USA, with 30 cases diagnosed in the fourth quarter, 10 in Michigan and nine in Indiana. The majority were in unvaccinated horses that died or were euthanized.

France, Germany, Portugal, and the USA confirmed cases of West Nile (WN) encephalitis. Outbreaks in France (seven), Germany (three), and Portugal (one) involved one or two cases. A total of 25 cases were recorded in the USA, of which 10 were in Colorado and six in Florida. One case was positive for both EEE virus and WN virus.

The RSA confirmed one case of equine encephalitis, and the USA diagnosed three cases of equine protozoal myelitis during the period under review.



Equine Disease Quarterly

Editors

Peter Timoney
Alan Loynachan
Rebecca Ruby

Staff

Diane Furry
Tawana Brown
Dennis Duross
Anita Hatchett

Correspondence should be addressed to the editors, Department of Veterinary Science, Maxwell H. Gluck Equine Research Center, University of Kentucky, Lexington, Kentucky USA, 40546-0099
Telephone (859) 257-4757
Fax (859) 257-8542

Internet address:
<http://gluck.ca.uky.edu/equine-disease-quarterly>

Material published in the Quarterly is not subject to copyright. Permission is therefore granted to reproduce articles, although acknowledgment of the source and author is requested.

The University of Kentucky is an Equal Opportunity Organization.



The fourth quarter saw an additional 35 outbreaks of vesicular stomatitis reported by the USA on premises in eight states. No new affected premises have been identified since late November.

The USA confirmed two outbreaks of *Rhodococcus equi* infection, but this significantly under-represents the incidence of this endemic disease in the country.

3

Epiglottic Entrapment

The epiglottis is a triangular shaped cartilage located in the throat at the base of the entrance to the airways. During normal breathing, it is situated above the soft palate and facilitates air movement. When eating, the epiglottis moves upwards and backwards to allow swallowing and to prevent food from entering the airways. To allow for such movement, the lower surface of the epiglottis has a loosely attached, elastic mucosa (subepiglottic mucosa). Epiglottic entrapment occurs when the subepiglottic mucosa becomes positioned above the epiglottis, restricting movement.

The most common presenting sign in cases of epiglottic entrapment is abnormal respiratory noise. The abnormally positioned subepiglottic mucosa creates a slightly narrowed airway, as well as increased air turbulence, which creates a harsh respiratory noise. Horses in a higher plane of work, racehorses for example, can also present with exercise intolerance. In horses performing at high speeds, even mild narrowing of the airway can result in decreased athletic performance, and, as a result, decreased earnings. Coughing and nasal discharge occur in some cases, as an abnormally functional epiglottis can contribute to disruption of airflow and slightly interfere with the swallowing process. As none of these changes indicate a specific cause of disease, transnasal endoscopy is often used to further investigate horses exhibiting these clinical signs. This procedure is commonly done in many cases with suspected upper airway disease and involves the passage of a small, flexible camera up the horse's nose to visualize the airway. Most horses tolerate this intervention well with minimal restraint or sedation.

The majority of cases have persistent epiglottic entrapment; however, a small number of horses experience intermittent epiglottic entrapment, which is relieved when the horse swallows. The membrane entrapping the epiglottis can vary in thickness, width, and can become ulcerated. In addition to endoscopic evaluation, a radiograph of the laryngeal region can also be obtained to assess the patient for epiglottic hypoplasia (a smaller than normal epiglottis) as this can be an uncommon cause of epiglottic entrapment.

Surgery is the most common treatment option for this condition. An incision is made through

the abnormally positioned subepiglottic mucosa to release the entrapped epiglottis. The procedure can be performed either under sedation and local anesthesia or under general anesthesia and typically takes less than 30 minutes. There are several surgical methods available, namely use of a transnasal endoscopically guided laser, transendoscopic electrosurgical instrument, or transnasal or transoral curved surgical knife. Surgical excision can also be performed via incision into the airway via the pharynx or larynx, however, these methods will result in an external scar and can contribute to surgical site complications. These procedures are therefore typically reserved for cases with additional complications.

The potential complications of surgical intervention include thermal trauma to the epiglottis, adhesions, and cicatrix (scar) formation. To reduce the risk of these occurring, horses should receive systemic and topical anti-inflammatory medications. Dorsal displacement of the soft palate can occur regardless of the treatment method employed, particularly when epiglottic hypoplasia is present.

Local inflammation is common following surgical correction of epiglottic entrapment. Horses should therefore receive transnasal endoscopic evaluation each week following surgery until the larynx has a normal appearance. Throat sprays containing anti-inflammatory agents are also strongly recommended. In order to reduce inflammation in the laryngeal region; horses require a period of rest following surgery. Depending on the severity of the condition and the treatment method employed, horses can return to work 3-8 weeks post-operatively, providing transnasal endoscopic evaluation is normal. Reoccurrence is not uncommon and can be treated by surgical excision of the excess subepiglottic mucosa. The majority of horses with epiglottic entrapment without epiglottic hypoplasia are able to return to their original level of activity.

CONTACT:

Alex Gillen, MA, MS, VetMB, CertAVP,
DipACVS, DipECVS, MRCVS
alexandra.gillen@liverpool.ac.uk
Phillip Leverhulme Equine Hospital
University of Liverpool
United Kingdom

Figure 1. Infectious causes of abortion

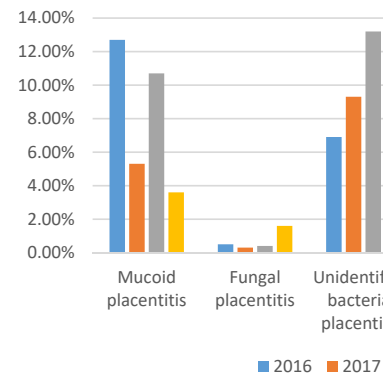
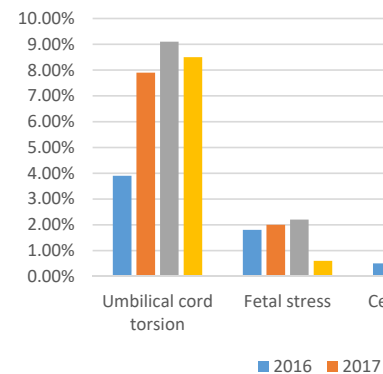


Figure 2. Non-infectious causes of abortion





NATIONAL

Equine Abortion: The 2016-2019 Breeding Seasons in Central Kentucky

Equine abortion is a common and frustrating condition with a variety of infectious and noninfectious causes. Evaluation of the fetoplacental unit can aid in understanding the cause of individual foal loss, allow early detection of infectious causes of abortion, and identify trends over multiple years that can help predict future causes of fetal loss. Following changes in the causes of abortion over multiple years may help to elucidate environmental risk factors or changes in disease prevalence over time.

Causes of abortion over the last four breeding seasons from 2016 to 2019 are presented in Figure 1 (infectious causes) and Figure 2 (non-infectious causes). A review of the 2016 and 2017 seasons can be found in the January 2018 issue of the *Equine Disease Quarterly*. Total submission numbers were 570, 328, 408, and 304 for 2016, 2017, 2018, and 2019, respectively. The overall submission numbers vary based on numbers of mares bred that year and incidence of diseases which create noticeable placental lesions (such as nocardioform placentitis). General trends in abortion have remained consistent over time, with placentitis being the most commonly diagnosed cause of abortion in all years. Placentitis cases represented 24.6%, 20.2%, 34.5%, and 25% for 2016, 2017, 2018, and 2019. Typically, non-infectious causes of abortion (umbilical cord torsion, twins, fetal and maternal stress, and abortions of unknown etiology) are more common than infectious causes (viral, bacterial, and fungal infections) with the exception of 2016, which had 145 cases of mucoid (nocardioform) placentitis, increasing the total

percentage of infectious abortions to 55%.

Evaluation of the last four breeding seasons shows that cases of mucoid placentitis and abortion of undetermined cause have the most variation between years. Abortions due to fungal infection, fetal bacteremia, umbilical cord torsion, and fetal stress have remained fairly stable. An increase in miscellaneous causes of abortion and undetermined causes occurred in 2018 and 2019. Miscellaneous causes include a variety of conditions including congenital malformations, fetal and maternal stress, cervical pole necrosis, fetal organ necrosis or inflammation, hydrops and Potomac horse fever. This increase may reflect normal variation between years. Alternatively, monitoring and intervention for early placentitis and vaccination for infectious cases of abortion such as leptospirosis and EHV-1 may be decreasing the incidence of these recognized diseases and result in a corresponding increase in the percentage of cases of abortion without an identified cause. Abortions of undetermined cause increased each year at 14.9% in 2016, 27.5% and 38.2% in 2017 and 2018 and peaking at 44% in 2019. Continued monitoring of trends will help to determine the significance of these variations.

CONTACT:

Alan Loynachan, DVM, PhD, DACVP

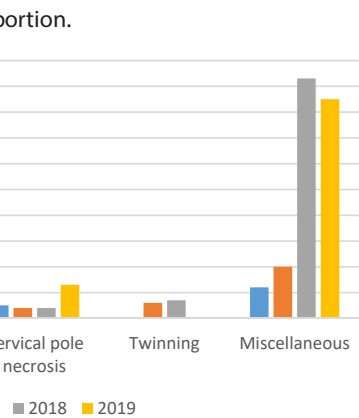
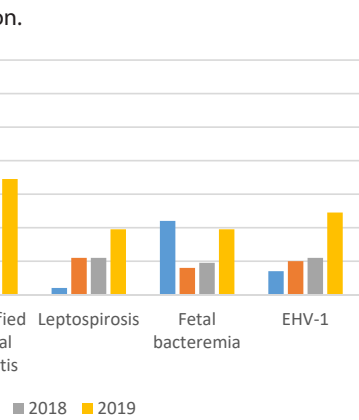
alan.loynachan@uky.edu

Rebecca Ruby, MSc, BVSc, DAVCP

rebecca.ruby@uky.edu

(859) 257-8283

University of Kentucky Veterinary Diagnostic Laboratory,
Lexington, Kentucky



KENTUCKY

Nocardioform Placentitis: A Continuing Enigma

Nocardioform placentitis was first diagnosed in central Kentucky in 1986 with subsequent increased case incidences occurring in 1998, 1999, and 2011. Cases of nocardioform placentitis have also been reported sporadically in Florida, South Africa, Italy, and most recently in New Zealand.

Nocardioform placentitis is characterized by late-term abortions, premature foals, neonatal deaths, and weak foals born at term. Nocardioform placentitis may involve large regions of the chorion that can result in fetal growth retardation due to placental insufficiency. The distribution of the

5 lesion in the placenta is distinct from ascending bacterial placentitis with lesions of nocardioform placentitis commonly distributed in the cranial, ventral portion of the placenta near the junction of the uterine horns and body. The lesion is often sharply demarcated from the surrounding normal placenta, and the affected placenta is frequently covered with thick, tan mucoid material.

Nocardioform placentitis is associated with Gram-positive, branching actinomycetes including multiple *Amycolatopsis* spp., *Crossiella equi*, and, more recently, *Streptomyces atriruber* and *Streptomyces silaceus*. Characterization of actinomycetes associated with abortions during the 2011 outbreak of nocardioform placentitis in central Kentucky revealed that *Amycolatopsis* spp. (49% of cases) were most commonly identified followed by *Crossiella equi* (29% of cases). Nocardioform placentitis results in episodic abortions. A major epizootic of nocardioform placentitis was recorded in 2010-11, consisting of 390 confirmed cases of placentitis with 76 confirmed abortions. These abortions occurred primarily between December 2010 and April 2011 and were diagnosed almost exclusively during the last trimester of pregnancy.

Nocardioform placentitis is primarily characterized as a mucoid placentitis in which the bacterial infection is limited to the chorionic surface of the ventral placenta without infection of the fetus. To date, the pathogenesis remains poorly understood. Attempts to induce infection in mares by intrauterine inoculation of *Crossiella equi* at breeding and in pregnant mares via oral, intravenous, and intranasal routes with this organism have been

unsuccessful. Likewise, the ecology and biology of the causative agents, *Crossiella equi* and *Amycolatopsis* spp. remains unknown as these causative organisms have only been isolated from affected placentae in mares.

Epidemiology

Nocardioform placentitis abortions occur from November to June, with a peak incidence in January and February. The majority of aborted fetuses are in the last trimester of pregnancy, and the identification of nocardioform lesions on the placenta of term pregnancies is a common presentation. A retrospective epidemiologic study of on-farm risk factors associated with the 2010-11 epizootic of nocardioform placentitis identified a number of associations with nocardioform placentitis. Larger farms, higher mare numbers and higher animal density on farms was positively associated with the incidence of nocardioform placentitis. Longer grazing times during late winter, prebreeding administration of progesterone to mares, human chorionic gonadotropin (hCG) administration post-breeding and nonsteroidal anti-inflammatory drugs (NSAIDs) were negatively associated with the incidence of nocardioform placentitis. Retrospective evaluation of monthly climate data (precipitation and average temperature) for central Kentucky and the number of nocardioform placentitis cases seen by the University of Kentucky Veterinary Diagnostic Laboratory for the period of 1990-2018 was conducted to evaluate climatologic associations with nocardioform placentitis (Figures 1 and 2). This analysis demonstrated a moderately strong negative association ($\rho = -0.57$; $P = 0.001$)

Figure 1. Relationship between the number of nocardioform placentitis cases seen by the UKVDL and average rainfall (inches) in August and September preceding that foaling season.

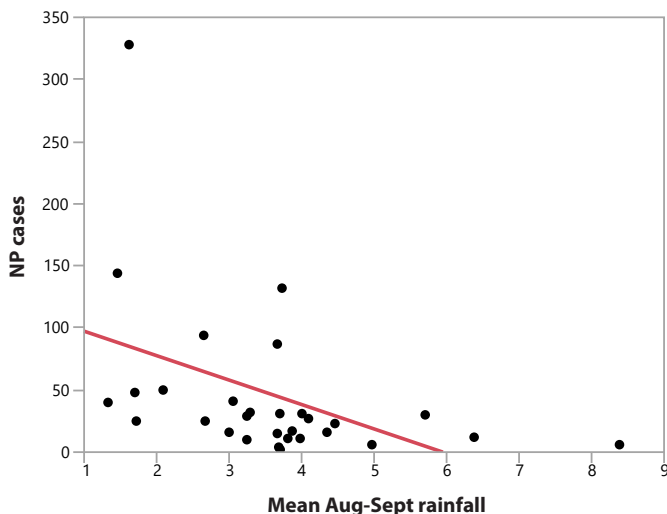
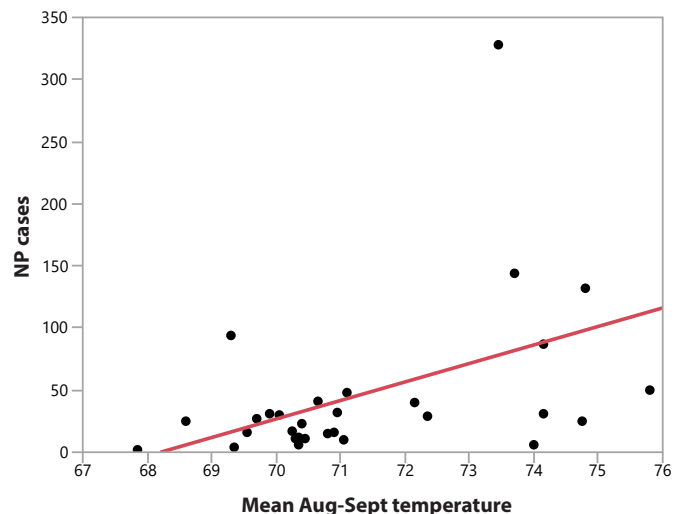


Figure 2. Relationship between the number of nocardioform placentitis cases seen by the UKVDL and average temperature (°F) in August and September preceding that foaling season.



Equine Disease Quarterly Newsletter

Department of Veterinary Science
Maxwell H. Gluck Equine Research Center
University of Kentucky
Lexington, Kentucky 40546-0099

Address Service Requested

between August and September rainfall and the number of nocardioform placentitis cases submitted for the subsequent foaling season. Likewise, there was a moderately strong positive association ($\rho = 0.47$; $P = 0.001$) between mean temperatures in August and September and the number of nocardioform placentitis cases submitted the next foaling season. Because average temperatures in August and September 2019 were 5.3% above the long-term average and average rainfall was only 52% of long-term average, the 2020 foaling season seems likely to have a higher incidence of nocardioform placentitis. Although there does seem to be an association between a hot and dry August and September preceding an increase in nocardioform cases, the causal relationship is less clear. Other members of the actinomycetes, such as *Rhodococcus equi*, are soil-dwelling pathogens that are associated with hot, dry, dusty environments. It is worth considering that the actinomycetes responsible for nocardioform placentitis may also originate as soil-borne organisms, despite the

failure thus far to isolate these pathogens from environmental sources. Related members of *Amycolatopsis* and *Streptomyces* are well characterized as soil-associated microorganisms, and a likely environmental association (hot, dry periods in late summer) may be associated with the disease.

It appears likely that the pathogenesis of nocardioform placentitis is multifactorial and may involve environmental conditions (hot, dry periods in late summer) and possibly effects related to host susceptibility. Pregnancy in many species, including the mare, involves some degree of immunosuppression, and many actinomycetes are more pathogenic in immunocompromised hosts. More research is needed to better unravel this complex disease process in the mare.

CONTACT:

Barry A. Ball, DVM, PhD, DACT
b.a.ball@uky.edu
(859) 218-1141
Maxwell H. Gluck Equine Research Center
University of Kentucky
Lexington, Kentucky

Figure 1. Infectious causes of abortion.

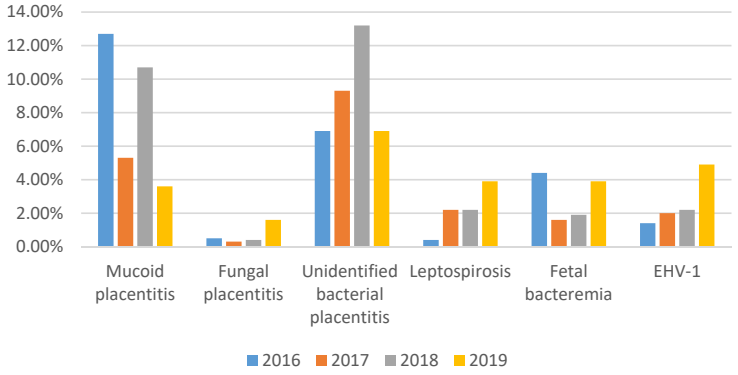


Figure 2. Non-infectious causes of abortion.

